

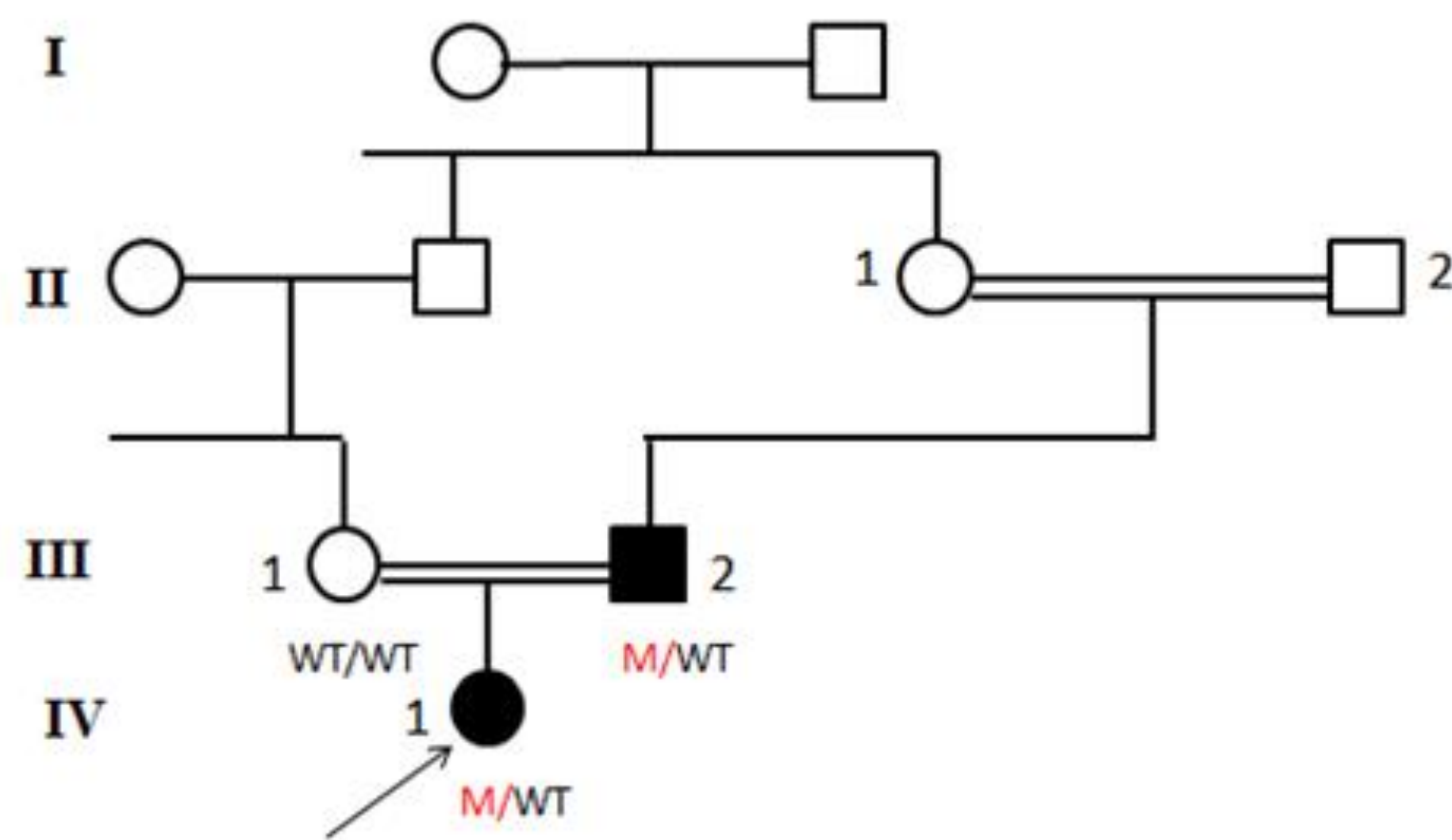
A NOVEL GH1 MUTATION IN A FAMILY WITH AUTOSOMAL-DOMINANT TYPE II ISOLATED GROWTH HORMONE DEFICIENCY

Fatih Gurbuz¹, Selin Elmaoğulları, Aslıhan Araslı, Fatma Demirel

Ankara Pediatric Hematology and Oncology Training and Research Hospital, Clinic of Pediatric Endocrinology, Ankara, Turkey

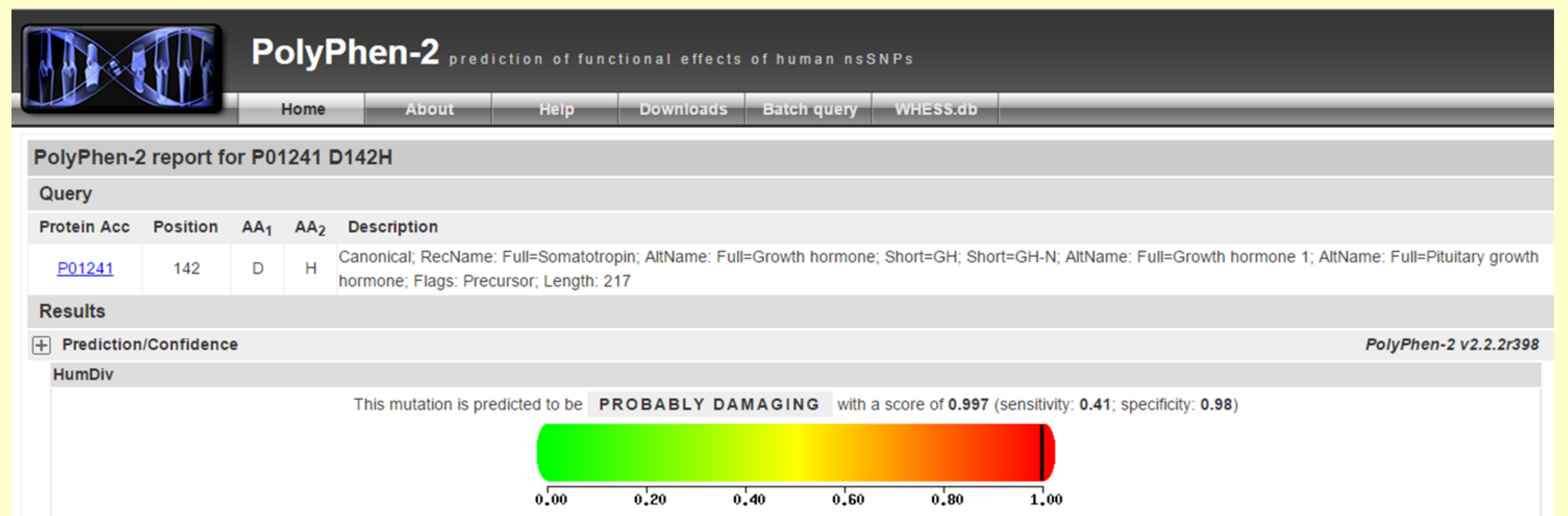
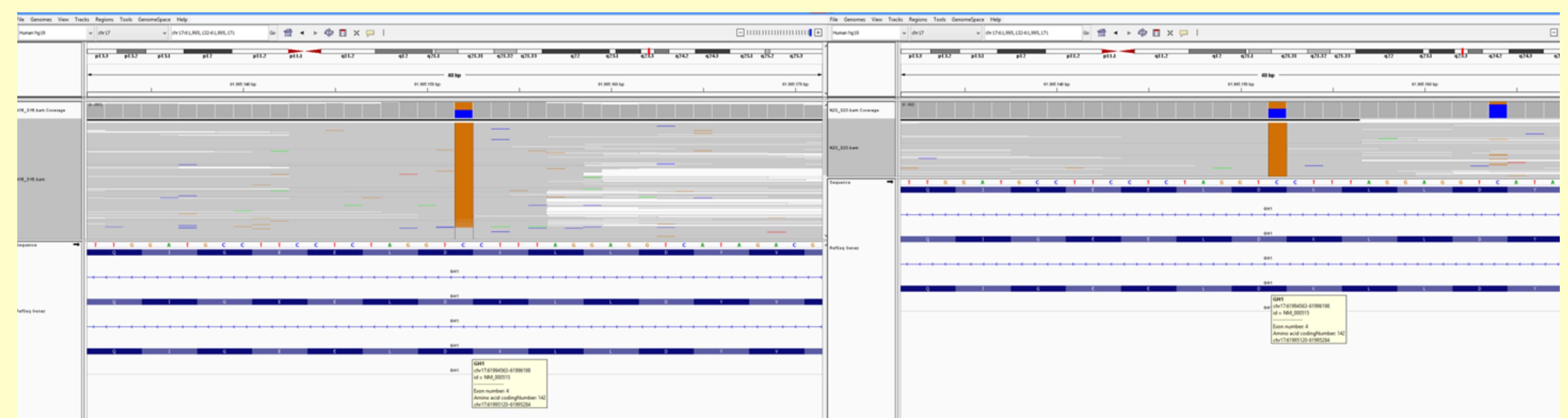
BACKGROUND

The familial type of isolated growth hormone deficiency (IGHD) is characterized by a variable degree of growth restriction, low but detectable GH serum concentrations. The recessive type IA and IB, the autosomal-dominant type II, and X-linked recessive type III. Phenotype-genotype correlations are notoriously difficult to be established. Herein, we described the patient who has autosomal-dominant type II IGHD due to a novel GH1 mutation.



PATIENT

The proband was fifteen month old girl who presented with short stature at. Her height was 67.3 cm (-3.66 SDS) and her weight was 7.3 kg (-2.77 SDS), MPH was 146 (-2.91 SDS), bone age was consistent with six months. She had typically growth hormone deficiency phenotype (baby face, increased truncal adiposity, and shrill voice). In two GH stimulation tests she had low but detectable GH peaks; respectively 5.93 ng/ml (with clonidine) and 4.79 ng/ml (with L-dopa). Other pituitary hormones and magnetic resonance imaging (MRI) of the pituitary region was normal. Patient diagnosed IGHD, but she had also congenital hip dislocation operation history. Growth hormone treatment was delayed up to 2 years and seven month old. The proband received recombinant human GH (rhGH) treatment (28 µg/kg/day) and she grew 2.9 cm in three months. Furthermore, patient's father had growth hormone treatment history because of growth hormone deficiency.



RESULTS

Sequencing of the GH1 gene revealed a novel heterozygous mutation in patient and her father (p.Q110E) (c.424G>C). In silico methods were concluded that, this novel mutation mutation is the cause of disease.

CONCLUSIONS

Establishing the genetic diagnosis of GHD is a challenge but clinical feature exceptions have to be considered.

