

# A Case of GH Deficiency with Encephalocraniocutaneous Lipomatosis and Jaffe-Campanacci Syndrome

Eun Mi Choi, Ye Jee Shim, Jun Sik Kim, Heung Sik Kim

Department of Pediatrics, Keimyung University School of Medicine and Dongsan Medical Center, Daegu, Korea

## Introduction

Encephalocraniocutaneous lipomatosis (ECCL) is a rare neurocutaneous syndrome characterized by unilateral lipomatosis and ipsilateral neurologic/ophthalmic malformation. Jaffe-Campanacci syndrome (JCS) is also a rare syndrome characterized by the association of café-au-lait spots, axillary freckles, multiple non-ossifying fibromas of the long bones and jaw, as well as some features of type 1 neurofibromatosis. In both rare diseases, we could not find any report of short stature with GH deficiency. Here we introduce a 9-year-old Tadzhikistan girl who had typical feature of both rare diseases and growth hormone deficiency.

## Case Report

The 9-year-old Tadzhikistan girl visited our Center to evaluate her anomaly. Her height was under 3<sup>rd</sup> percentile and weight was in 5<sup>th</sup>-10<sup>th</sup> percentile. She had incomplete upper eyelids (coloboma with ectopic cilia in right side, and cryptophthalmos with dermolipoma in left side) and separated sparse alopecia on left scalp (Fig. 1). She had left hemibody hyperpigmentation and ipsilateral edema of leg and foot. In brain MRI, widening of unilateral ventricular system and extraaxial CSF space of the left hemisphere and posterior fossa were observed. These findings were consistent with the known MR findings of ECCL. Associated multifocal parenchymal gliosis in left frontal lobe and the right thalamus was noted (Fig. 2). Coarctation of aorta (isthmus portion) was found by 2D-echocardiogram. Three major system were involved, so she was diagnosed as ECCL by Moog's criteria.

Imagings of her extremity showed nonossifying fibromata-extraskeletal anomalies, involving left femur and left tibiae suggesting JCS (Fig. 3). CT guided biopsy was done at proximal aspect of left tibia and pretibial soft tissue (Fig 4). Histopathologic findings showed non-ossifying fibroma in tibia bone biopsy (Fig 4.(A)) and a scattered fatty infiltration, suggestive of lipomatosis in soft tissue biopsy (Fig 4.(B)). The result was compatible with the pathology of non-ossifying fibromatosis. NF1 mutation was not found in her blood and her karyotyping was normal 46, XX.

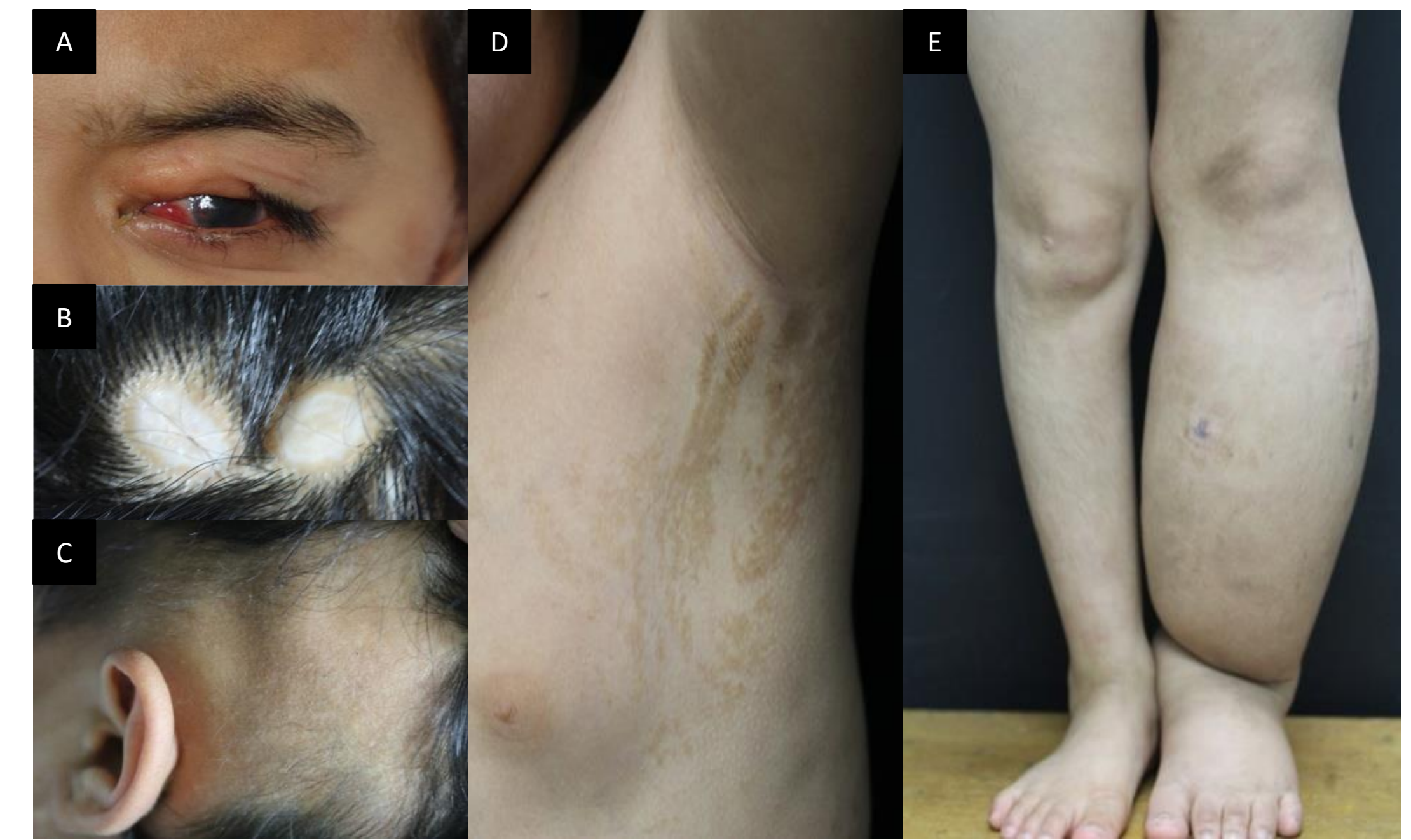Her height was under 3<sup>rd</sup> percentile. Her bone age was estimated as 7years 8months~9years old. (chronological age 9years 10months) To evaluate her short stature, we performed growth hormone provocation test using insulin and L-dopa. GH peak was 1.25 ng/mL with provocation test. IGF-1 was 19.14 ng/mL (normal range 76~499), IGF - BP3 was 1245 ng/mL (normal range 1389~4260). The other hormones (TSH, fT4, FSH, LH, ACTH, Cortisol, Estradiol, Progesterone, Testosterone, Aldosterone, Renin) were within normal range. She might need GH therapy but she returned to Tadzhikistan, so GH therapy couldn't be started.

To improve the pathologic morphology, Upper eye lids of both were reconstructed by plastic surgery and to relieve the leg edema, Z plasty was done on left lower extremity.

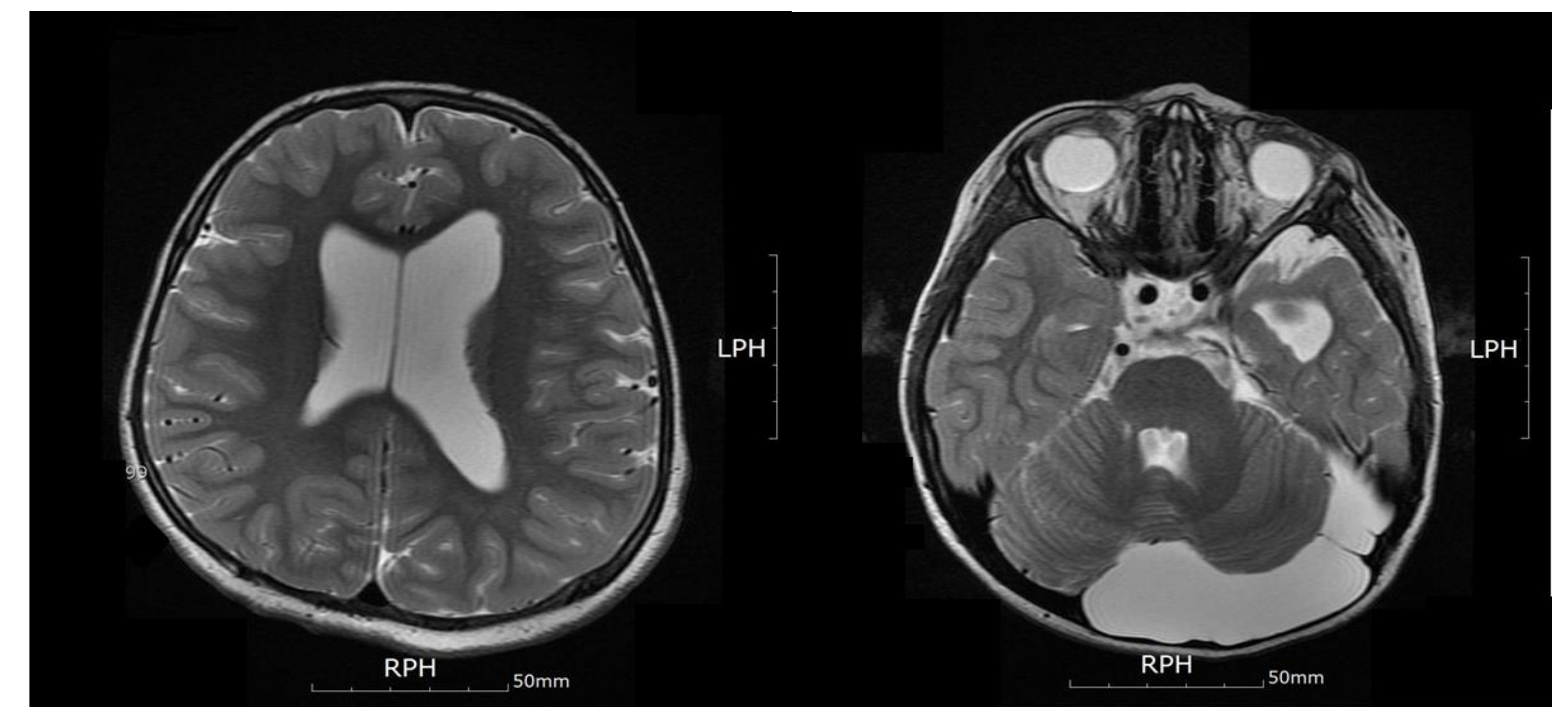
## Conclusion

Our patient was a rare case combined with ECCL and JCS. She had coloboma on the left eyelid, focal skin aplasia and hypoplasia on her scalp, asymmetrically dilated ventricles, aortic coarctation, multiple non-ossifying fibromas and café-au-lait spots. Her height was under 3<sup>rd</sup> percentile with GH deficiency.

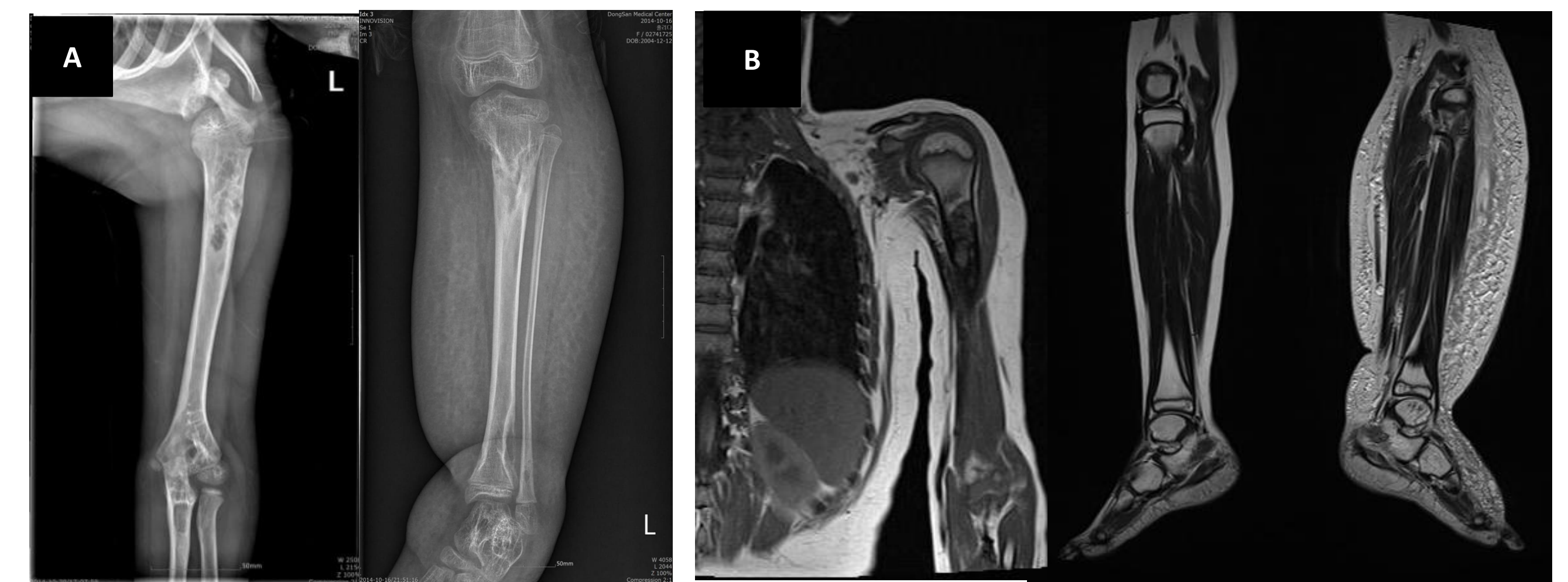
GH therapy was not done in this patient but after GH administration the result of therapy should be evaluated in the patient like this ECCL and JCS.



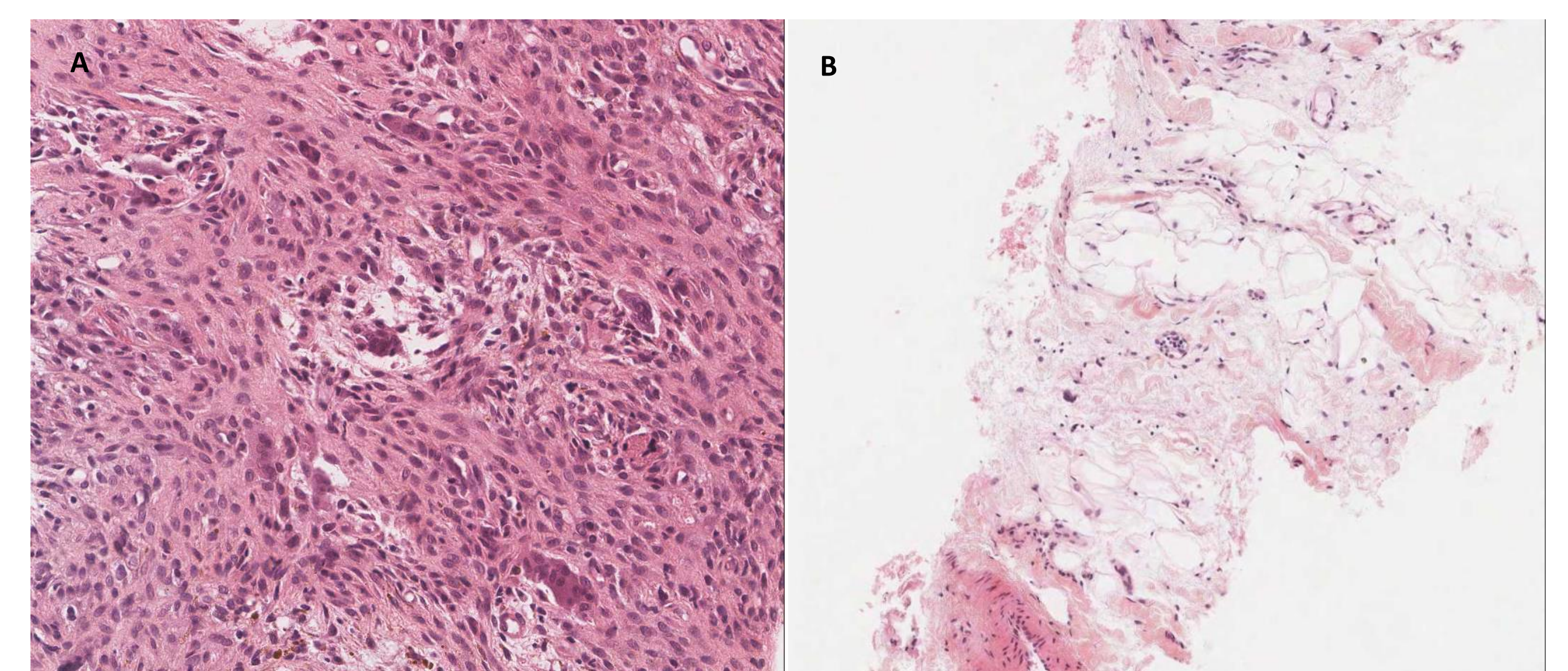
**Fig. 1. Morphologic characteristics of a girl with ECCL & JCS (A)** In left upper eyelid, coloboma and cryptophthalmos with dermolipomais was shown. Diffuse conjunctivalization of cornea and engorged vessels at nasal side was also shown. **(B)** Congenital absence or deficiency of a localized area of skin, with the base of the defect covered by a thin translucent membrane **(C)** Nevus psiloliparus **(D)** hyperpigmentation and cafe au lait spots **(E)** Hemihypertrophy



**Fig. 2. A brain MRI ;** Widening of unilateral ventricular system and extraaxial CSF space of the left hemisphere and posterior fossa were shown



**Fig. 3. An imaging findings of a girl with ECCL and JCS (A) Humerus x-ray** shows non-ossifying fibromas involving the left proximal humerus and left tibiae **(B) MR image** showed a relatively well-defined, elongated cortical bone lesion involving the left proximal humerus with heterogeneous enhancement suggestive of nonossifying fibromata extraskeletal anomalies, or angiomas, and lipomatosis involving left tibia that could be found in Jaffe Campanacci syndrome



**Fig.4 A histopathologic finding of a girl with ECCL and JCS (A) Tibia bone biopsy** showed non-ossifying fibroma(H&E, X200) **(B) Soft tissue biopsy** showed suggestive of lipomatosis(H&E, X100)

