

Congenital craniopharyngioma: report of two cases

¹Agnieszka Bogusz, ¹Elżbieta Moszczyńska, ^{1,2}Mieczysław Szalecki

¹Department of Endocrinology and Diabetology, IP CZD, Warsaw, Poland ² Faculty of Medicine and Health Sciences, The Jan Kochanowski University, Kielce, Poland

Introduction: Craniopharyngiomas are slow growing epithelial tumors located in the sellar or suprasellar region of the brain. Adamantinomatous subtype affects mainly children and accounts for 5-10% of all intracranial paediatric tumors. Diagnosed antenatal and neonatal craniopharyngiomas are very seldom, about 40 such cases have been detected to date. They are characterised by large size, progressive hydrocephalus and a poor prognosis.

The aim of the study was to analyse the clinical symptoms and treatment efficacy in children with diagnosis of congenital craniopharyngioma (adamantinomatous subtype).

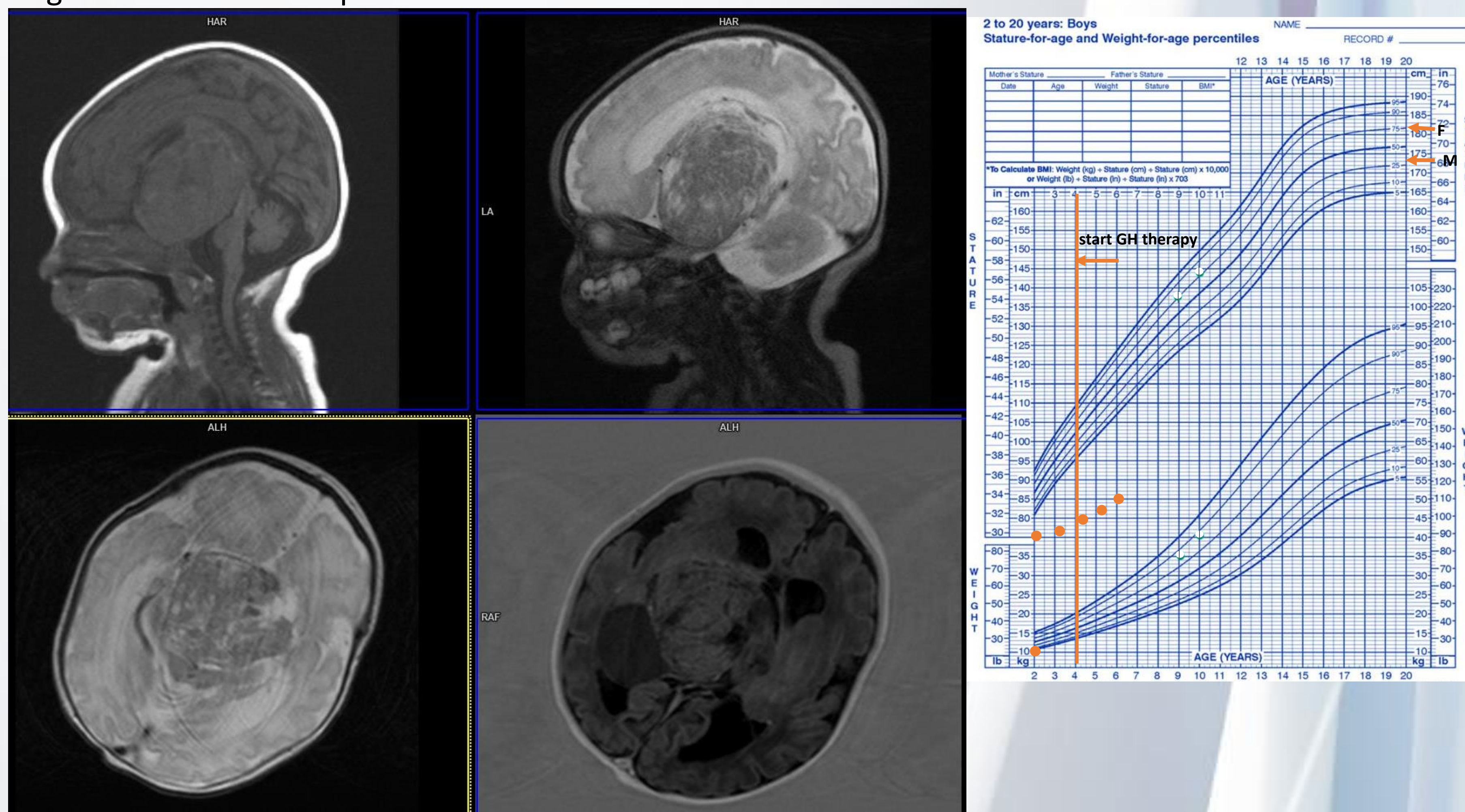
A retrospective analysis included two children with craniopharyngioma diagnosed in prenatal period (28 hbd) and in the second month of life.

Results:

Case 1. The first patient was diagnosed at 28 Hbd of pregnancy using an MRI scan. A 36-week-gestation boy was delivered by cesarian section. The newborn weighed 3410g and scored 9 points on APGAR scale. Postnatal MRI of the brain showed solid-cystic tumour with the solid part measuring 49x40x58 mm and the cystic part:29x24x31mm in the suprasellar region. Four weeks later, due to an increasing hydrocephalus, the baby underwent radical resection. It was diagnosed with an adenohypophysis, diabetes insipidus and blindness. Aged 7 now, the boy suffers from epilepsy, hypotonia and is disabled.

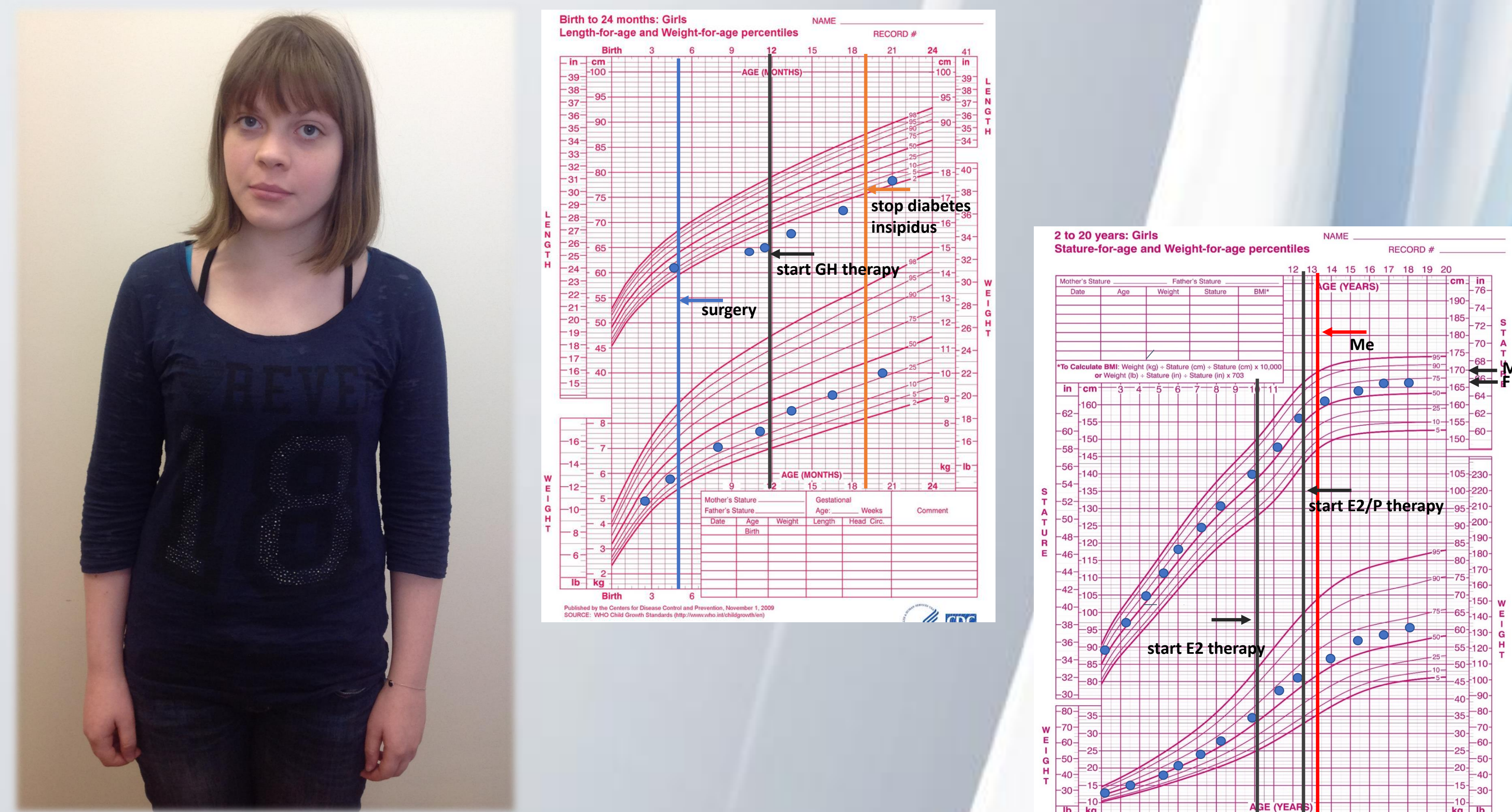
Case 1. 7 years old patient, operated at the age of 1 month

MRI of the newborn at the first day of life. SE/T1 sagittal and transverse plane.



Case 2. 18 years old patient, operated at the age of 5 months

Case 2. A 39-week-gestation girl was from uneventful pregnancy and normal vaginal delivery. At birth, she weighed 3680 g and scored 9 points on APGAR scale. At 2 months of age, due to vomiting, respiratory distress and bradycardia up to 40/min, the girl was hospitalized. The MRI of the brain revealed the presence of a mass measuring 22x26x24mm in the supra and intrasellar region. At the 5 months of age, the baby underwent radical resection. After the surgery, an adenohypophysis and temporary diabetes insipidus (1 year duration) was diagnosed. From 1st to 18th year of age, growth hormone therapy was used. Now, the 18-year-old girl measures 167,6 cm of height, weights 67,0 kg and is a capable student.



Conclusions:

Congenital craniopharyngiomas are rare tumours which can present a wide spectrum of symptoms depending on size and localisation. The outcomes can vary.