

Association between Congenital Hypopituitarism and Agenesis of the Internal Carotid Artery: a case report

Cocca A**, Carney O*, Hulse T*.

*Department of Endocrine and Diabetes, Evelina London Children's Hospital, London, UK

**Department of Pediatrics, Second University of Naples, Naples, Italy

Background

The abnormalities of the Internal Carotid Artery (ICA) are very rare phenomena and the agenesis, in particular, has an estimated incidence of 0.01% among the general population. It could be also associated with another rare condition: the congenital hypopituitarism.

Objectives and Hypothesis

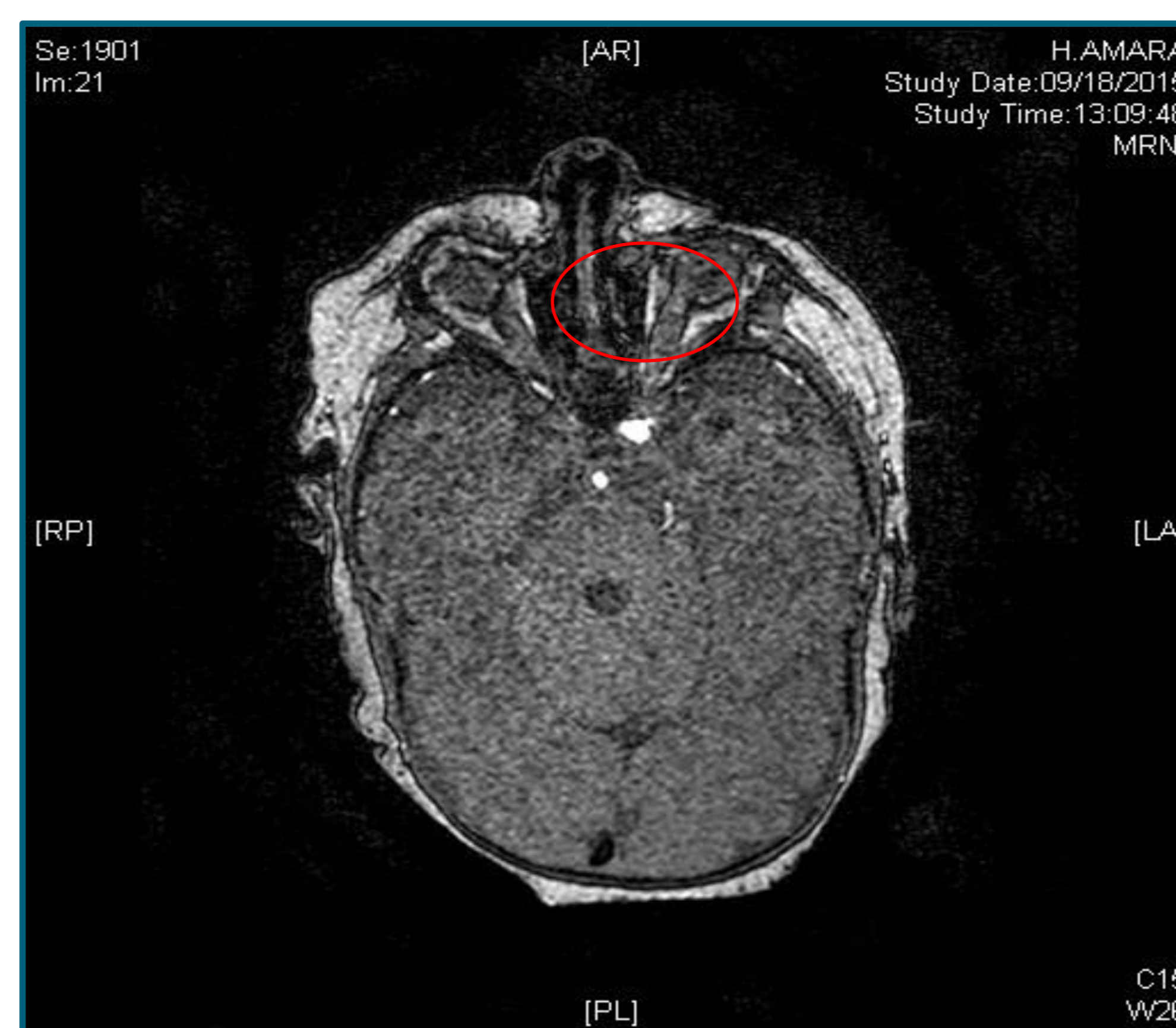
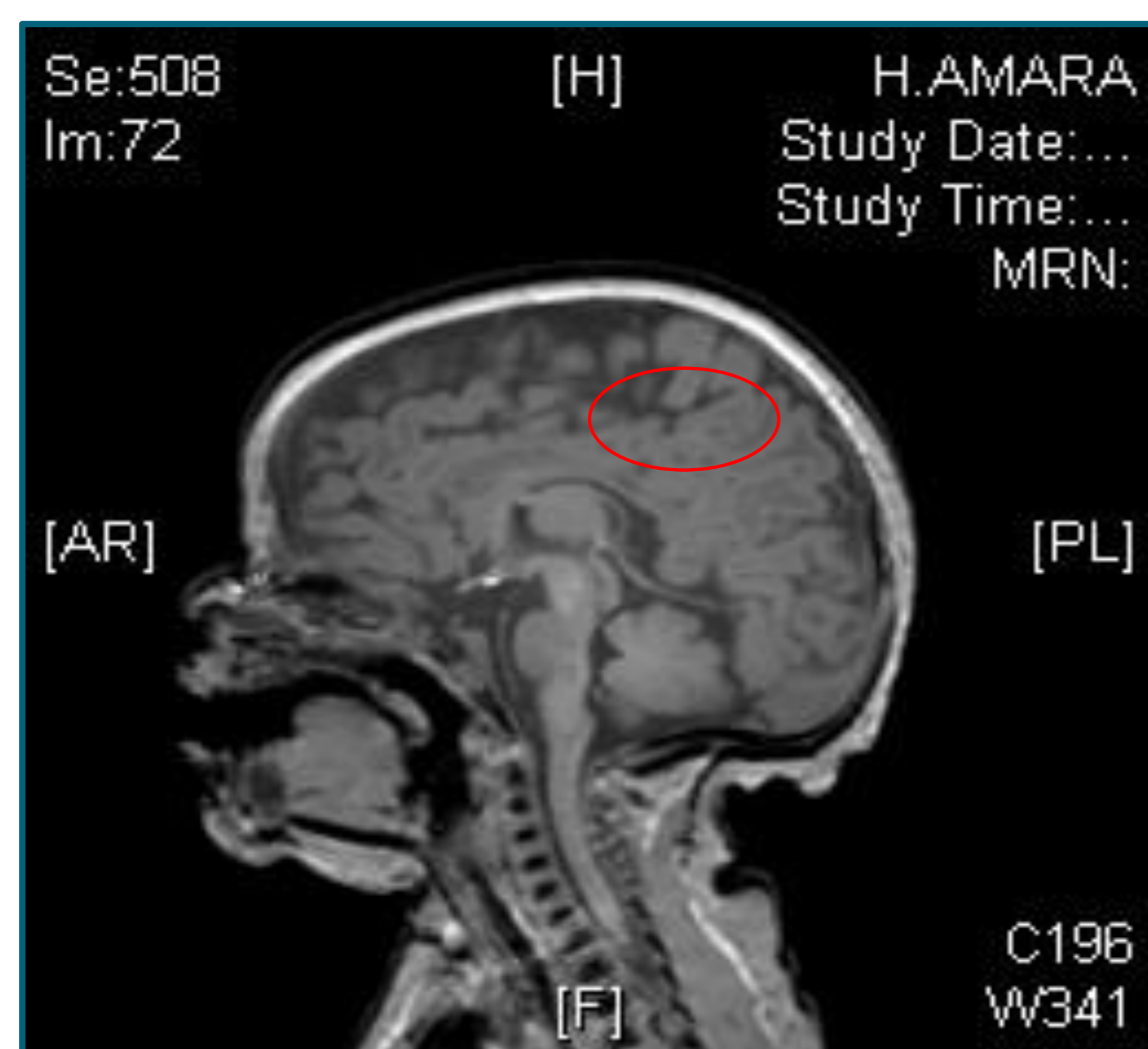
To describe a very rare case characterised by the association between the congenital hypopituitarism and the abnormalities of the ICA.

Method

Here we describe the case of a 5 months old female that presented respiratory distress after the birth and 1 month later, because of prolonged jaundice, was found to have low FT₃, FT₄, and TSH (FT₃ was <2.3 pmol/L, FT₄ was <3.5 pmol/L, TSH which was <0.1 microUI/L). She also had an undetectable Cortisol (<9 nmol/L) and IGF₁ (<3.3 mmol/L).

Results

MRI imaging demonstrated an ectopic posterior pituitary gland and the anterior pituitary gland appeared very small/hypoplastic. It also showed absence of the right ICA with an anastomotic vessel arising from the cavernous segment of the left ICA, crossing the midline, reconstituting the terminal right ICA and forming the right Middle Carotid Artery further on.



Conclusion

The case report we described is about a 5 months old patient with congenital hypopituitarism secondary to a hypoplasia of the pituitary gland, an ectopic posterior pituitary gland and the agenesis of the ICA.

Up to now this is the 14^o case with the association between congenital hypopituitarism and abnormalities of the ICA and the 4^o one before the first year of age.

Considering that a reduction of the blood supply is very unlikely to be the cause of the hypopituitarism, the hypothesis of a new, unknown, genetic mutation that could have caused both the pituitary hypoplasia and the agenesis of the ICA seems to be more likely.

References

- 1) Clarós P, Bandos R, Gilea I, Clarós Jr A, Capdevila A, García Rodríguez J, et al. Major congenital anomalies of the internal carotid artery: agenesis, aplasia and hypoplasia. *Int J Pediatr Otorhinolaryngol.* 1999;49:69-76
- 2) Savasta S, Merli P, Introzzi F, Strocchio L, Lanati G, Incorpora G, et al. Agenesis of internal carotid artery and hypopituitarism: case report and review of literature. *J Clin Endocrinol Metab.* 2012;97:3414-20
- 3) Di Iorgi N, Secco A, Napoli F, Calandra E, Rossi A, Maghnie M. Developmental abnormalities of the posterior pituitary gland. *Endocr Dev.* 2009;14:83-94

I have no conflict of interest to disclose

