

Giant macroprolactinoma in a female adolescent– case report

Ana HRENIUC¹, Simona GHERASIM¹, Carmen VULPOI¹, Ion POEATA², Daniel Rotariu², Cristina PREDA¹, Christina UNGUREANU¹, Voichița Mogoș¹, Letiția LEUȘTEAN¹

1 – Department of Endocrinology, "St.Spiridon" Hospital– University of Medicine and Pharmacy" Gr.T.Popa" Iasi, Romania

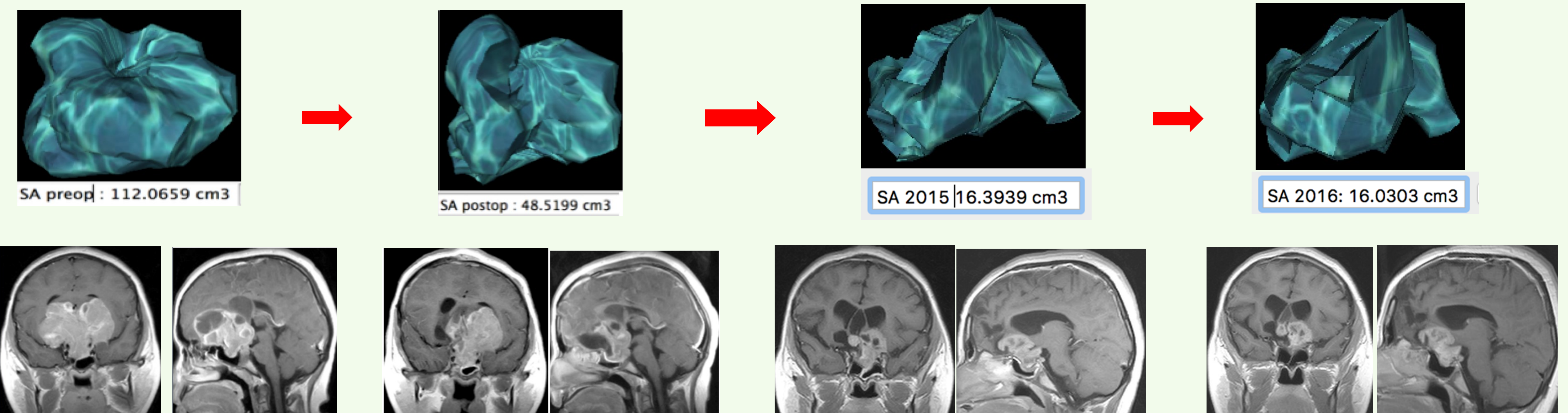
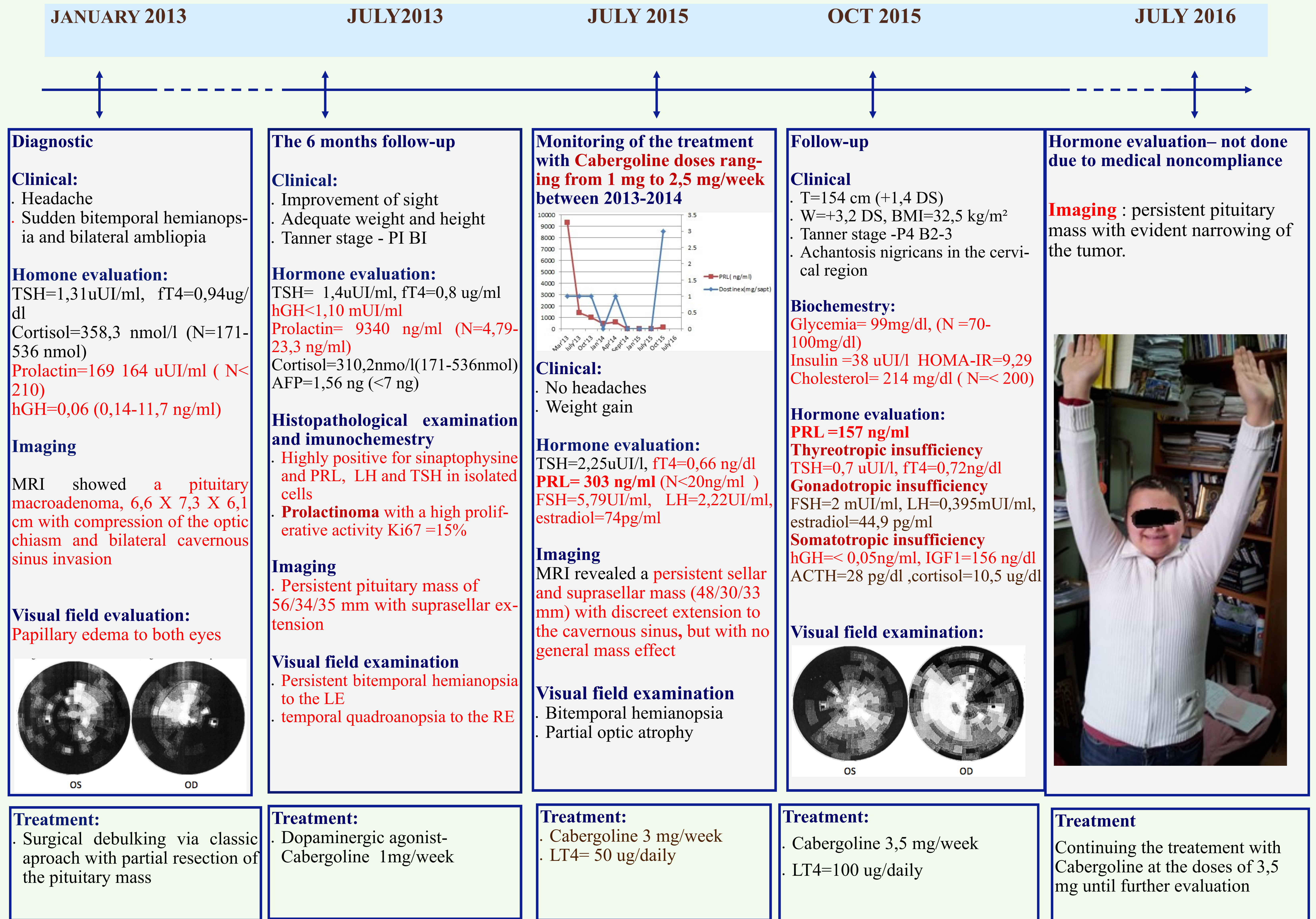
2 – Department of Neurosurgery "N.Oblu "Hospital-University of Medicine and Pharmacy" Gr.T.Popa" Iasi, Romania

Background:

Known to be the most common pituitary tumour in adults, prolactinoma is rare in children and adolescent with an evolution that tends to be controversial.

Case presentation:

Female, 12 years-old, complaining of headaches and progressive visual loss



Conclusions

- Being this fairly rare tumor in children, there is a lack of treatment guidelines. In spite of the prompt debut of the medical treatment, the control of the disease was also difficult to achieve because of low medical adherence.
- The postoperative management of this case proves to be provoking, both in the control of the secretion of this large sellar mass, but as well in the ensuring of growth and puberty installation.