

# A XO/XX Girl with Lack of Morphological UTS-Features, Short Stature and Precocious Puberty

Birgit Vogel, Kinderarztpraxis Lilienthal, Lilienthal, Germany,  
Gunter Šimić-Schleicher, Klinik für Kinder- und Jugendmedizin Klinikum Bremen Nord, Bremen, Germany

## Background:

Ullrich-Turner-Syndrome is usually characterized by typical morphological features, short stature, delayed bone age in childhood and gonadal dysgenesis with delayed or lacking pubertal development, amenorrhoea and infertility. Other symptoms like thyroid dysfunction, heart defects, diabetes, behavioural or learning problems vary. The genotype/phenotype correlation may be poor. Especially in UTS mosaicism spontaneous puberty may occur.

## Objective and Hypotheses:

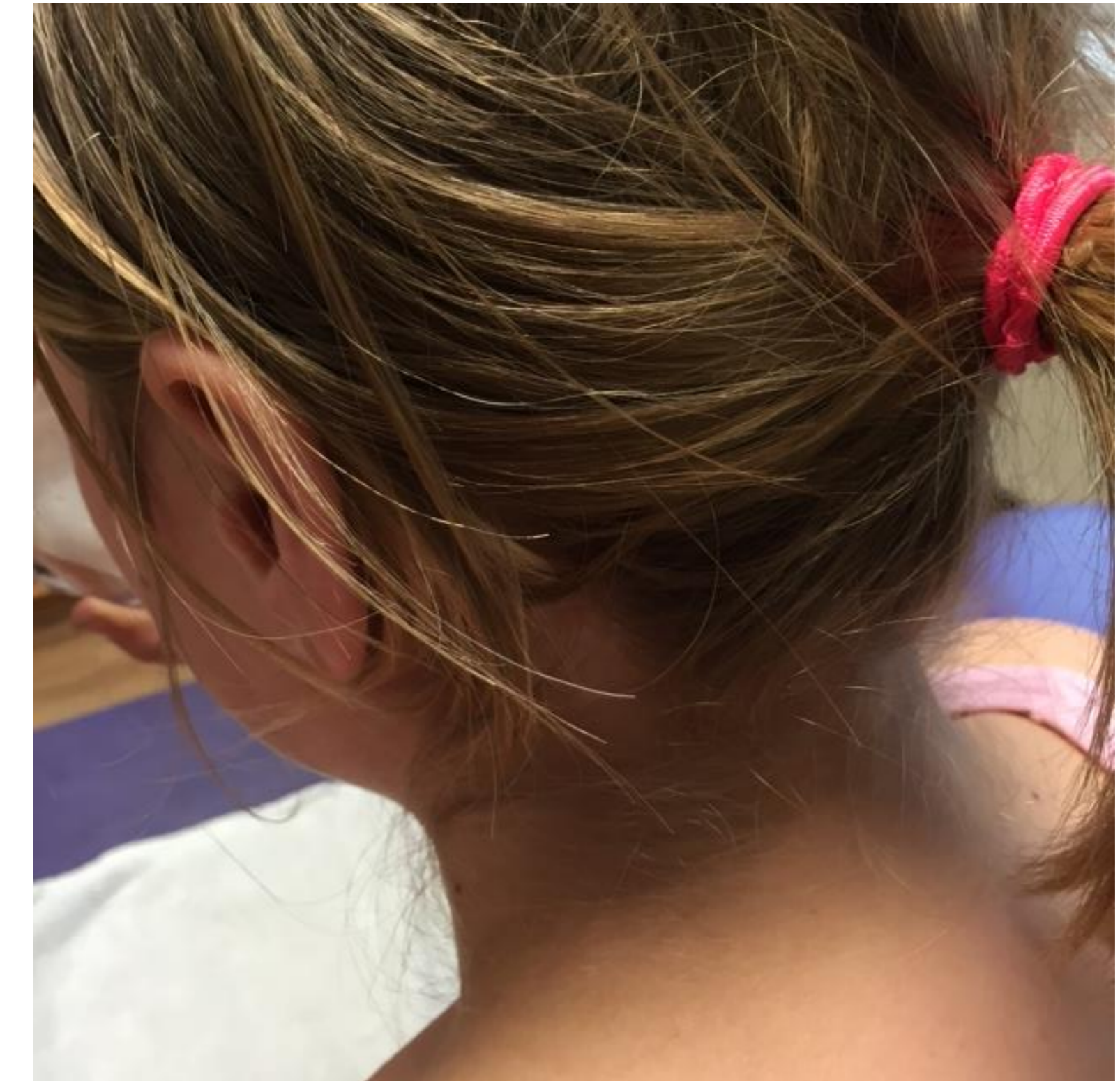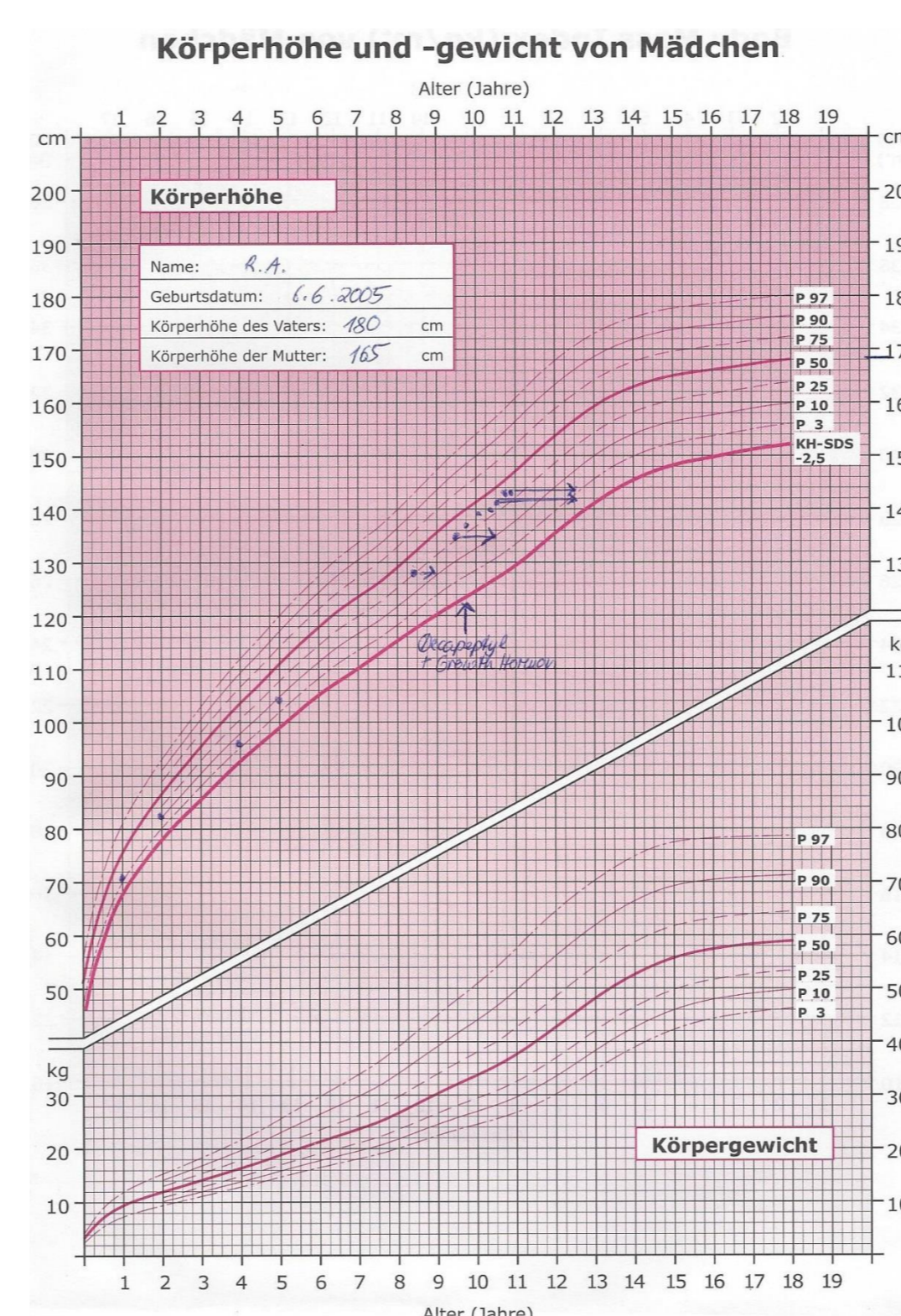
We report a girl with UTS mosaicism with lack of morphological features and precocious puberty. She is the first of 2 children born after normal pregnancy at term with low birth weight of 2820g. Her uncle suffered from Klinefelter syndrome. At the age of 8 she developed pubertal hair and thelarche. Bone age was 12.5y and she measured 139cm with a target height of 169cm. LH was 2,5 U/l (<12), FSH 6,3 U/l ((0,4-6,6), oestradiol 25 ng/l (6-27) with normal levels of beta-HCG, alpha-1-foetoprotein, testosterone, prolactin, IGF1 and IGFBP3. She then developed behavioural problems and learning difficulties. Menarche was at the age of 9 8/12y. She also has an insulin insensitivity with a peak insulin level of 302.3 µU/ml after 60 min and had a thyroid dysfunction. An ACTH-Test showed normal levels.

## Methods:

We treated the patient with growth hormone, gonadotropin-releasing hormone analogues and thyroid hormones.

## Results:

During this treatment the girl showed moderate growing (growth rate 7,2 cm) while we managed to stop puberty development and bone age progress. We are still working on weight loss to treat the insulin insensitivity.



## Conclusions:

Our patient showed a rare condition of UTS which is not recognized by appearance. Apart from hypothyroidism, for therapeutic considerations, short stature and precocious puberty with mental development are relevant. Chromosomal analysis should be mandatory in short stature or reduced prospective height even if there are no morphological features indicating Turner's syndrome.

**References:** Growth Hormone plus Childhood Low-dose Estrogen in Turner's syndrome. Judith L. Ross, M.D., Charmian A. Quigley, M.B., and Gordon B. Cutler, Jr, M.D.: N Engl J Med 2011, 364:1230-1242; Combined therapy with GnRH analog plus growth hormone in central precocious puberty; Pucarelli I, Segni M, Ortore M, Moretti A, Iannaccone R, Pasquino AM: J Pediatr Endocrinol Metab. 2000 Jul 13. Suppl 1 811-20 Treatment of precocious puberty in two patients with Turner mosaicism. Evanhec KA, Rotenstein D, J Pediatric Endocrinol. Metab. 2005 Aug;18(8):819-22

**No conflict of interests – Parents permission to show the photos is given**

