

# EARLY SUCCESSFUL HEMATOPOETIC STEM CELL TRANSPLANTATION (HSCT) IN A BOY WITH IPEX SYNDROME CAUSED BY NOVEL c.721T>C FOXP3 MUTATION



FN MOTOL

Barbora Obermannova<sup>1</sup>, Renata Formankova<sup>2</sup>, Zdenek Sumnik<sup>1</sup>, Lenka Dusatkova<sup>1</sup>, Stepanka Pruhova<sup>1</sup>, Jana Kayserova<sup>3</sup>, Petr Sedlacek<sup>2</sup> and Jan Lebl<sup>1</sup>

<sup>1</sup> Department of Pediatrics, <sup>2</sup>nd Faculty of Medicine, Charles University in Prague and University Hospital Motol, Prague, Czech Republic

<sup>2</sup>Department of Paediatric Hematology and Oncology, <sup>2</sup>nd Faculty of Medicine of Charles University and the University Hospital Motol, Prague, Czech Republic

<sup>3</sup>Department of Immunology, <sup>2</sup>nd Faculty of Medicine of Charles University and the University Hospital Motol, Prague, Czech Republic



P1\_7-RFC-5

The authors have no relevant conflicts of interest

## Background:

IPEX (OMIM #304790) is a X-linked immune dysregulatory disorder caused by mutation in the gene for transcription factor FOXP3 [1]. Mutation in FOXP3 result in either quantitative or functional deficiencies of Tregs causing diverse autoimmune disease and allergic inflammation. The males harbouring this mutations are hemizigots and manifested with clinical symptoms [2]. HSCT is the only curative therapy available for IPEX patients. However, success has been limited and morbidity and mortality are considerable. Many of the features of IPEX remit after successful transplantation, although endocrinopathies frequently persist due to permanent organ damage [3]. HSCT has been described in a limited number of IPEX patients, many of whom are well posttransplant. Potential complications of HCT in IPEX patients include macrophage activation syndrome, infection, graft-versus-host disease, and growth failure [4].

## Case presentation:

Presented boy was born at 38<sup>th</sup> GW with birth weight 3380 g and birth length 50 cm. Three maternal brothers died in early infancy due to malabsorption (Pedigree, Fig 1.). At the age of six weeks the patient developed Type 1 diabetes (T1D) with typical clinical and laboratory presentation (glycaemia 38 mmol/L, severe ketoacidosis and extremely high GAD antibodies > 120 kIU/L). Subsequently he developed atopic dermatitis and progressive failure to thrive due to diarrhea. Total parenteral nutrition (TPN) and intravenous insulin infusion was initiated. Immunosuppressive treatment with glucocorticoids (methylprednisolon dosing up to 2 mg/kg/day) was ineffective.

## Hematopoietic stem cell transplantation:

At the age of three months he underwent HSCT from an unrelated HLA-matched donor. The HSCT course was uncomplicated, the outcome was favorable: gastrointestinal and skin symptoms fully resolved, the boy is fed orally and thriving well. The treatment with glucocorticoids was stopped two months after the HSCT, the immunosuppressive therapy with sirolimus was terminated at the age of 10 months. However after the HSCT C-peptide remained undetectable, insulin treatment could not be stopped. Nowadays, at the age of one year, is the patient's T1D well-controlled by CSII (HbA1c 62 mmol/mol) with daily insulin requirements of 0.41 IU/kg. The clinical course of our patient is display in figure 2, the summary of laboratory and clinical data related with T1D in table 1.

Figure 1.: Pedigree of affected family: family history of male's early death.

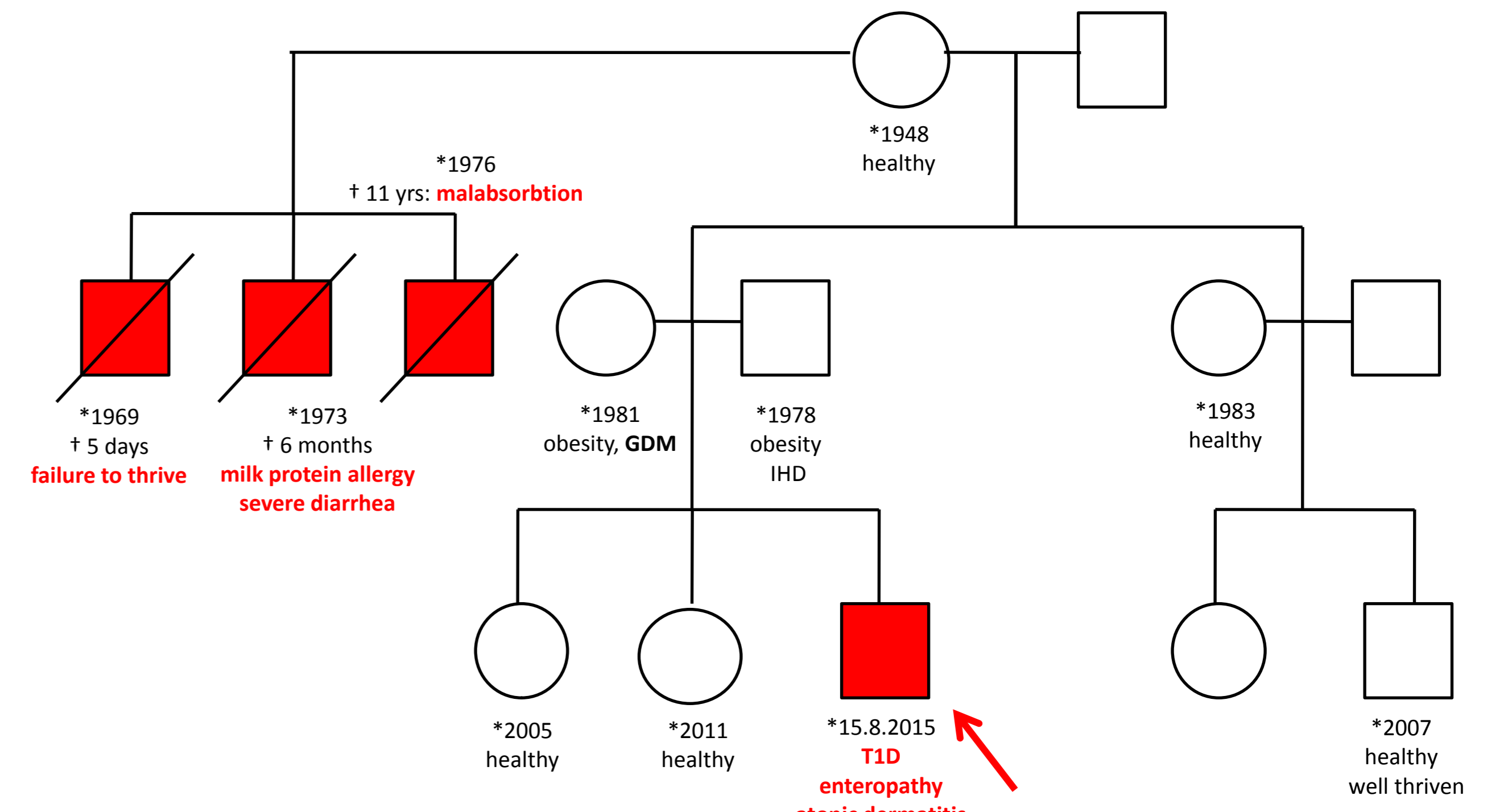
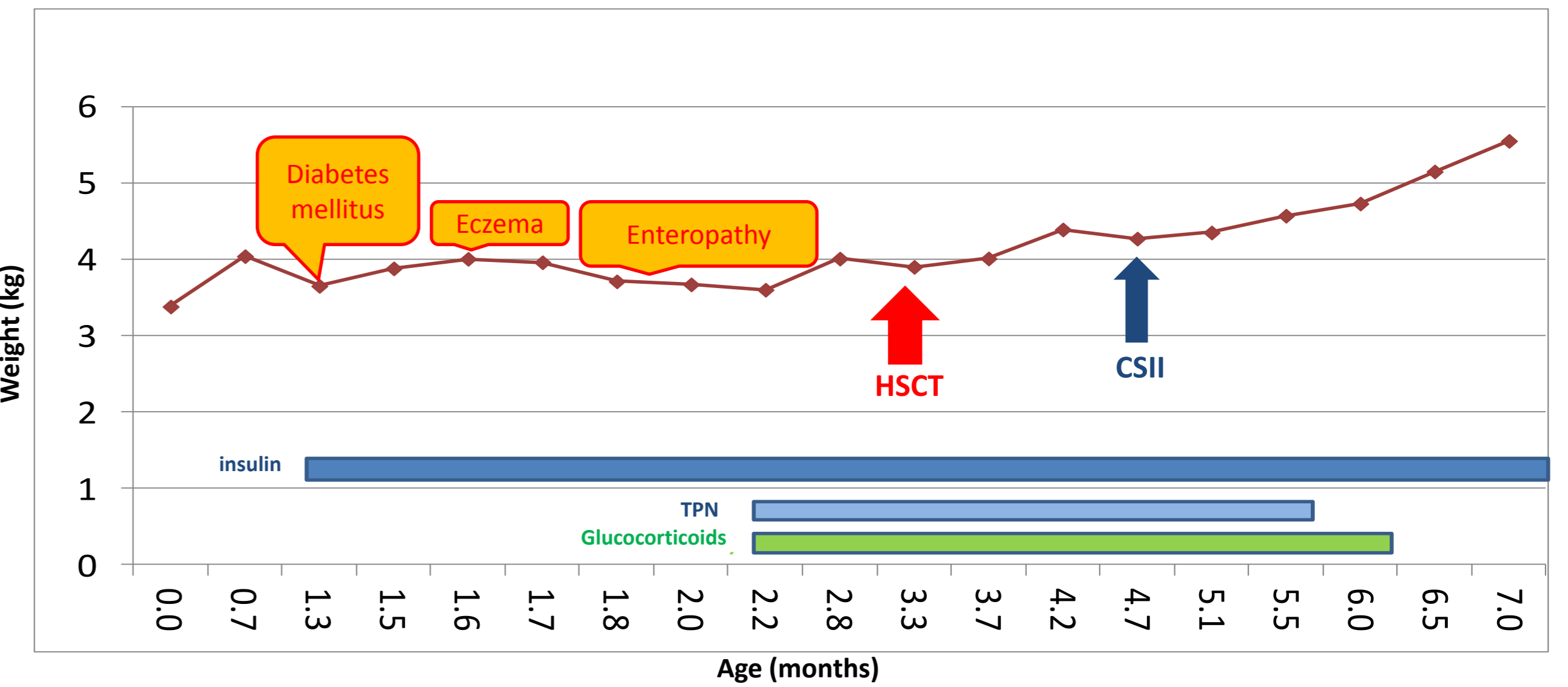


Figure 2.: Clinical course in our patient.



Age of the patient	3. months	6. months	9. months	12. months
C-peptide (pmol/L)	91,7...< 3,33	< 3,33	23.6	31.2
HbA1c (mmol/mol IFCC, % DCTT)	ND	45 (6.3%)	66 (8.2%)	62 (7.8%)
GAD antibodies (kIU/L)	> 120	ND	> 120	ND
Insulin daily dose (IU/kg)	1.35	0.67	0.64	0.41
Weight (g)	4010	5600	6670	7900
Weight (SDS)	- 2.82	- 3.73	- 2.87	- 2.36

Table 1.: Summary of laboratory and clinical data related with T1D in our patient [ND = not determined].

## References:

- Powell BR, et al. An X-linked syndrome of diarrhea, polyendocrinopathy, and fatal infection in infancy. *J Pediatr* 1982; 100:731.
- Bennett CL, et al. X-linked syndrome of polyendocrinopathy, immune dysfunction, and diarrhea maps to Xp11.23-Xq13.3. *Am J Hum Genet* 2000; 66:461.
- Wildin RS, et al. Clinical and molecular features of the immunodysregulation, polyendocrinopathy, enteropathy, X linked (IPEX) syndrome. *J. Med Genet* 2002; 39:573.
- Lucas KG, et al. Submyeloablative cord blood transplantation corrects clinical defects seen in IPEX syndrome. *Bone Marrow Transplant* 2007; 39:55.
- Gambineri E, et al. Clinical and molecular profile of a new series of patients with immune dysregulation, polyendocrinopathy, enteropathy, X-linked syndrome: inconsistent correlation between forkhead box protein 3 expression and disease severity. *J Allergy Clin Immunol*. 2008 Dec;122(6):1105-1112.e1.
- Baud O, et al. Treatment of the immune dysregulation, polyendocrinopathy, enteropathy, X-linked syndrome (IPEX) by allogeneic bone marrow transplantation. *N Engl J Med* 2001; 344:1758.

## Methods and results:

### Molecular genetic analysis:

Direct sequencing of FOXP3 gene revealed a novel c.721T>C (S241P) mutation in proband, his mother and sisters.

Gambineri in 2008 described IPEX patient with mutation in similar region (L242P) [5].

According to *in silico* predictive models the novel mutation is pathogenic.

### Functional analysis:

Transcriptional factor FoxP3 is expressed on T cells in IPEX patient. Tregs are identified as CD4+CD25+FoxP3+ cells. The quantity of Tregs in our patient was in normal range (9.0%, Fig 3A).

Immunosuppressive assay investigates suppressive function of Tregs on proliferation of effector T cells (Eff) expressed as mean fluorescence intensity (MFI) of KI67 (Fig 3B).

**Tregs from IPEX patient failed to suppress proliferation of effector T cells if compared to healthy controls.**

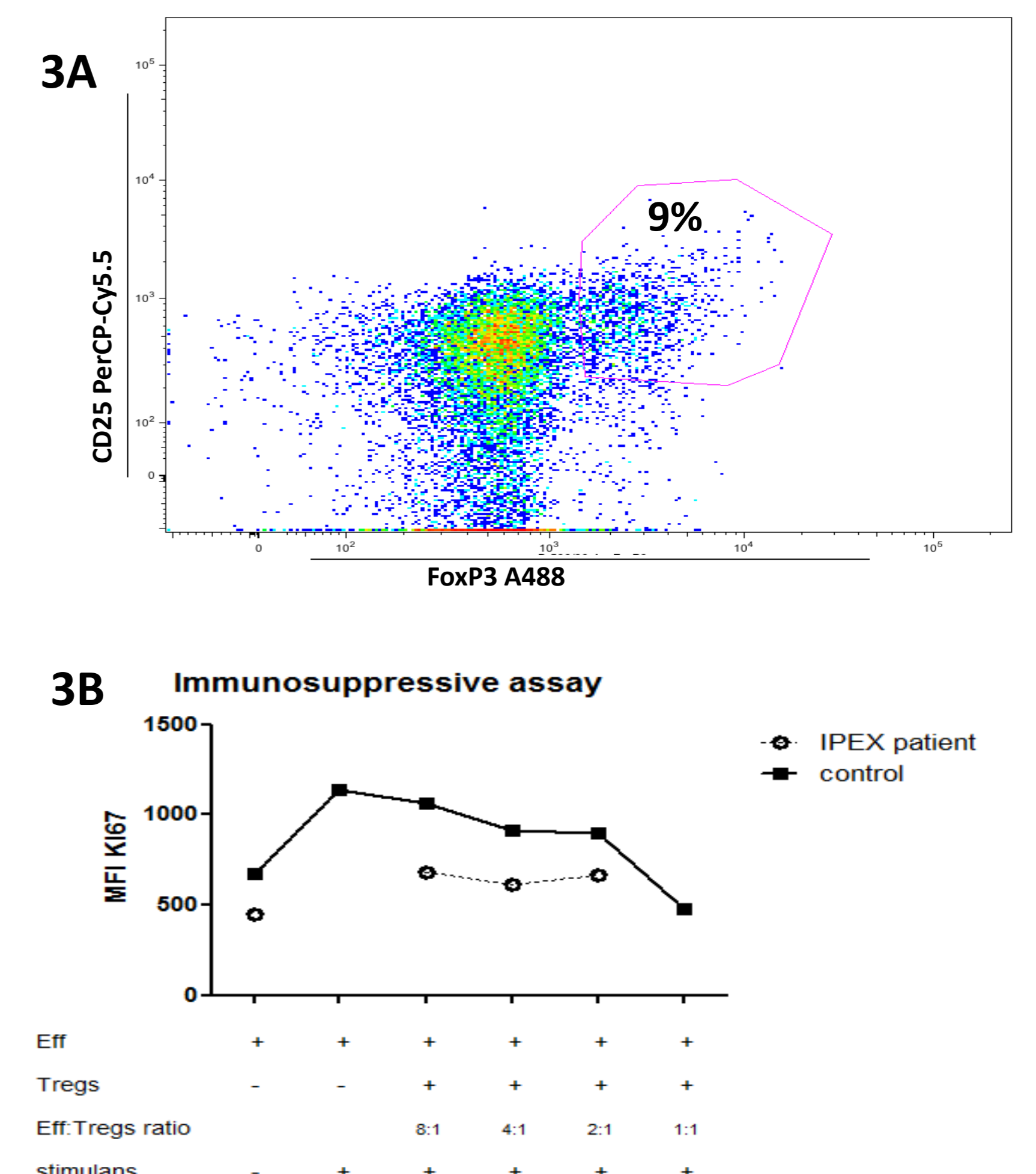


Figure 3.: Functional analysis of the patient's Tregs.

## Conclusions:

We describe a previously unreported c.721T>C (S241P) mutation in FOXP3 gene. To our knowledge we reported the youngest patient with IPEX who underwent successful HSCT [6]. We suggest that an early genetic diagnosis followed by an early HSCT offers the greatest potential to correct the disease process and thereby minimize end-organ damage.

