

# Testicular Adrenal Rest Tumours in Patient with X-Linked Adrenoleukodystrophy

Igor Chugunov, Maria Kareva, Elizaveta Orlova & Valentina Peterkova,  
Endocrinology Research center, Moscow

## Background:

Testicular adrenal rest tumours (TARTs) are benign tumors consisting of cells with adrenal-like features in mediastinum of testes. TARTs occur in up to 94% of adult male patients with classic 21-hydroxylase deficiency and also have been described in patients with Cushing syndrome and acquired adrenal insufficiency. Poor disease control is thought to be one of the main predictive factors for TARTs development.

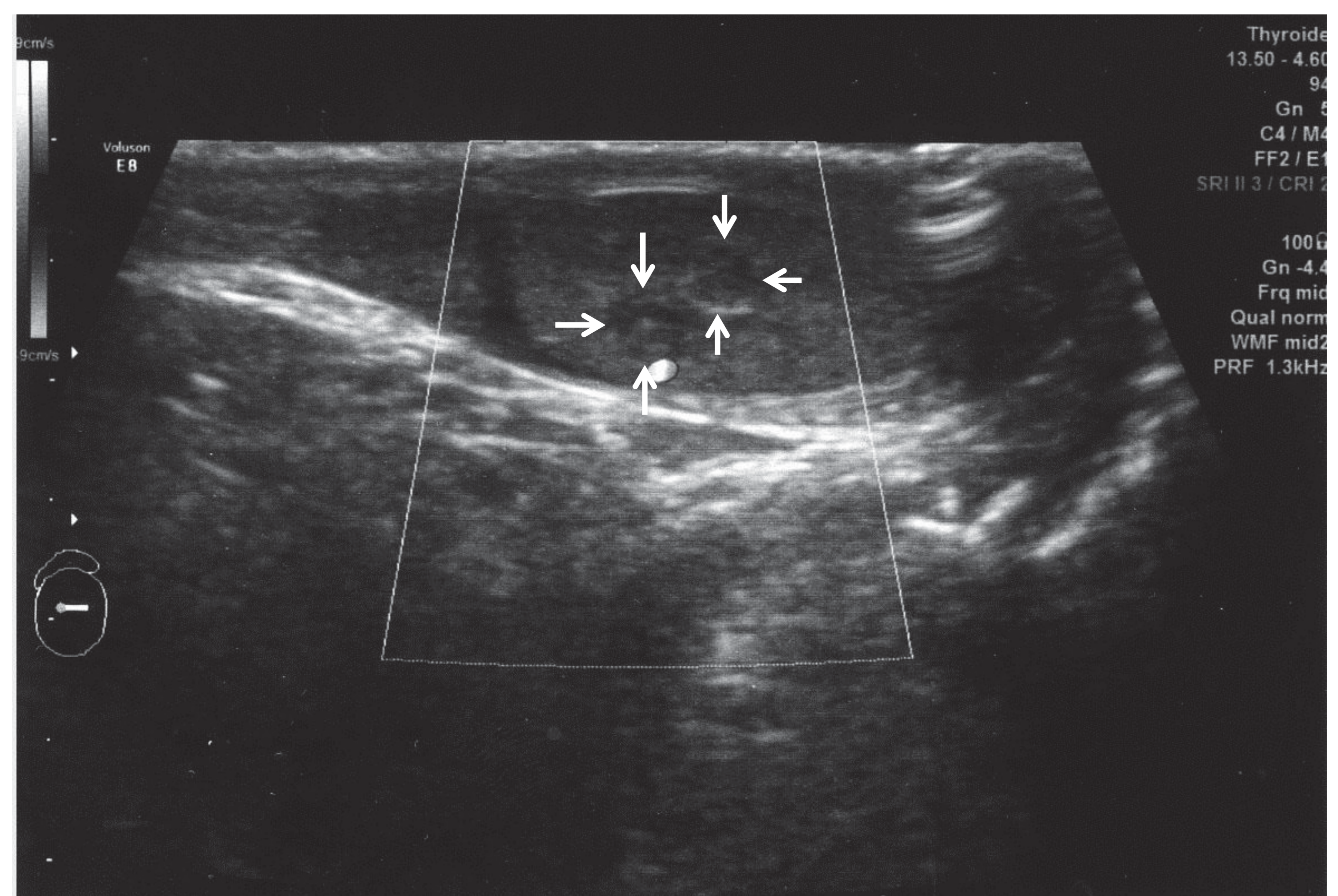
## Clinical case:

A boy presented at the age of 3 years with hyperpigmentation, weakness.

Primary adrenal insufficiency was proved by low cortisol (9 nmol/l), high ACTH (1250 pg/ml), high renin (500 mU/l). Elevated plasma concentrations of very long chain fatty acids (VLCFA) (C24 96.2  $\mu\text{mol/l}$ , range 22.6–80.0; C26 2.8  $\mu\text{mol/l}$ , range 0.22–2.2; C24/C22 1.5, range 0.64–0.88) were revealed. Novel mutation c.1550N>C in ABCD1 gene was found. He was diagnosed with X-ALD. Neurological symptoms were absent, MRI of the brain was normal.

The boy was on a replacement therapy with gluco- and mineralocorticoids since the age of 3 with good effect but ACTH level remained very high (1500–3000 pg/ml) during 3-year follow-up.

Bilateral hypoechoic lesions, located close to the mediastinum of the testes with normal bloodstream on the color Doppler evaluation, were found on scrotum ultrasound at the age of 6. Six months after the increasing the dose of hydrocortisone, TARTs volume decreased.



## Conclusion:

To the best of our knowledge, this is the first report of TARTs development in patient with X-linked adrenoleukodystrophy. Ectopic adrenal cells in prepubertal testes may avoid damage by VLCFA and when stimulated by high ACTH form TARTs.