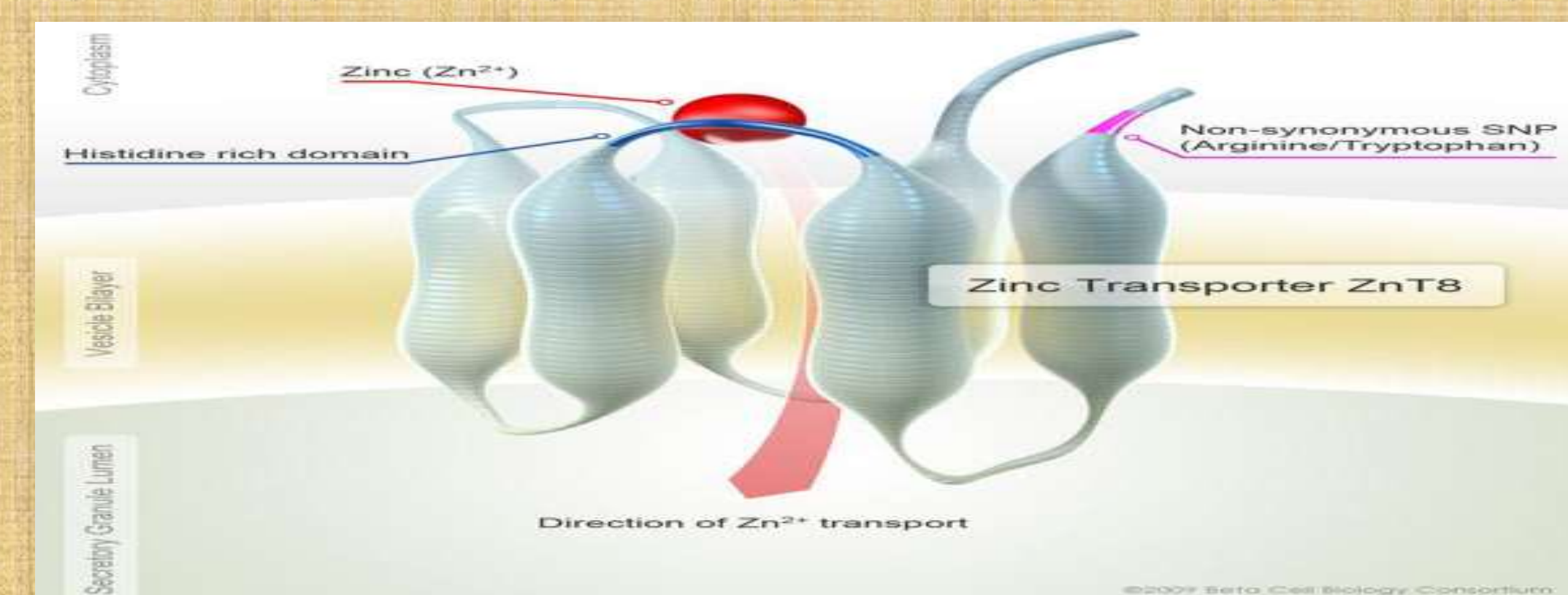
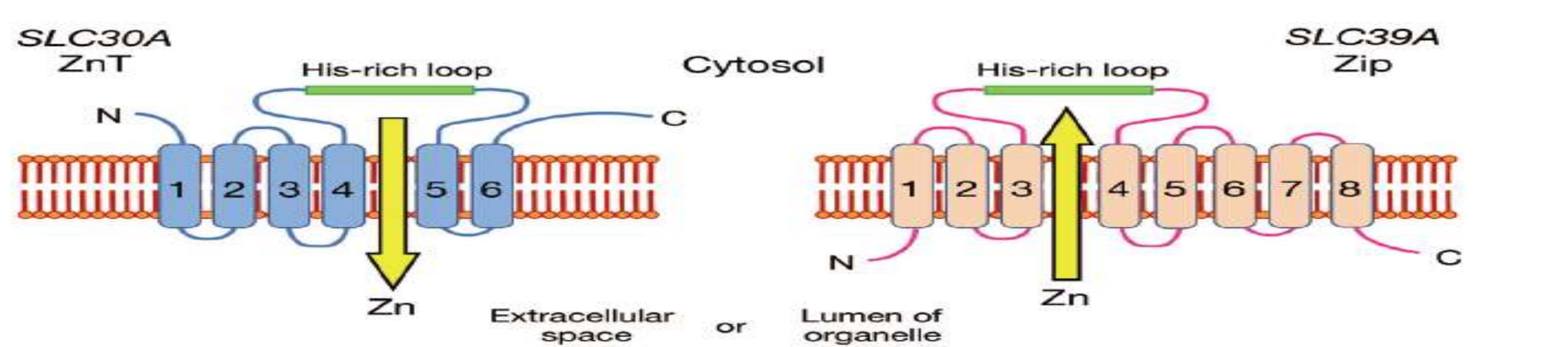


Artur Bossowski<sup>1</sup>, Joanna Reszeć<sup>2</sup>, Dariusz Polnik<sup>3</sup>, Marta Gąsowska<sup>4</sup>, Wiesława Niklińska<sup>4</sup>.

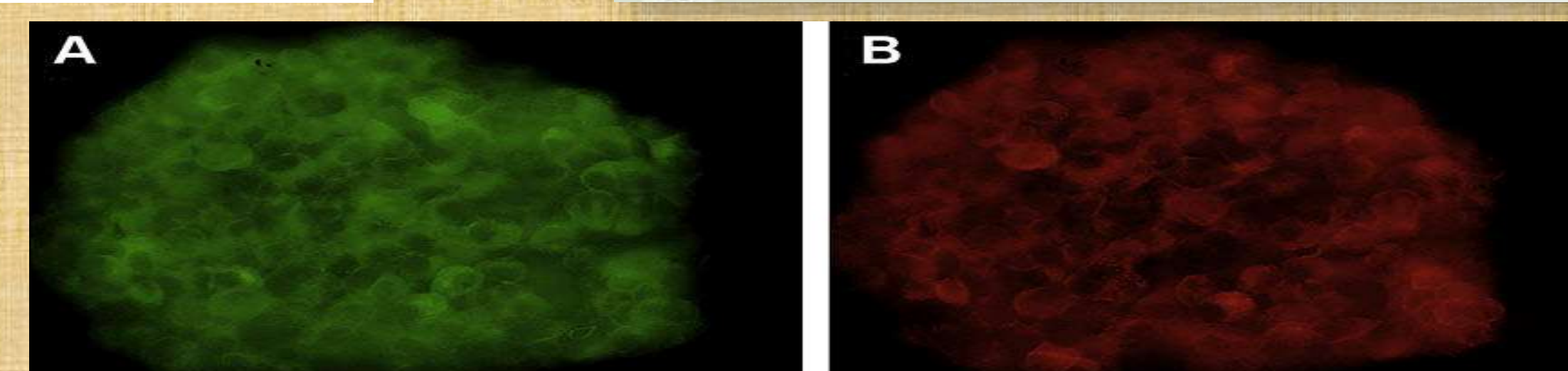
<sup>1</sup> Department of Pediatrics, Endocrinology and Diabetes with a Cardiology Unit, Medical University in Białystok, Poland, <sup>2</sup>Department of Medical Patomorphology. Medical University in Białystok, Poland <sup>3</sup> Department of Children's Surgery and Transplantology, Children's Memorial Health Institute, Warsaw, Poland, <sup>4</sup>Department of Histology and Embryology, Medical University in Białystok, Poland

## Objectives

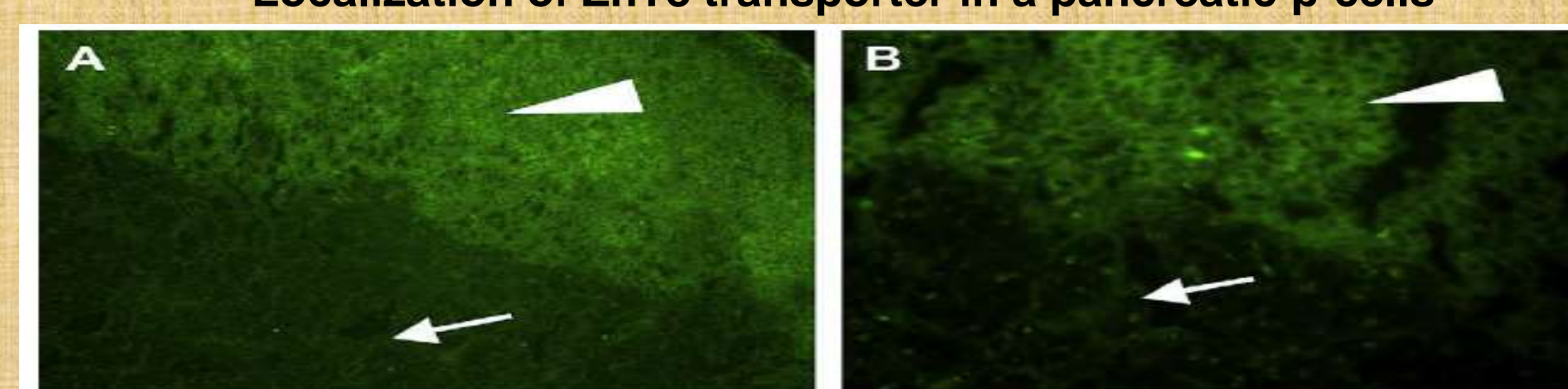
### Zinc transporter - ZnT8 –function and localization



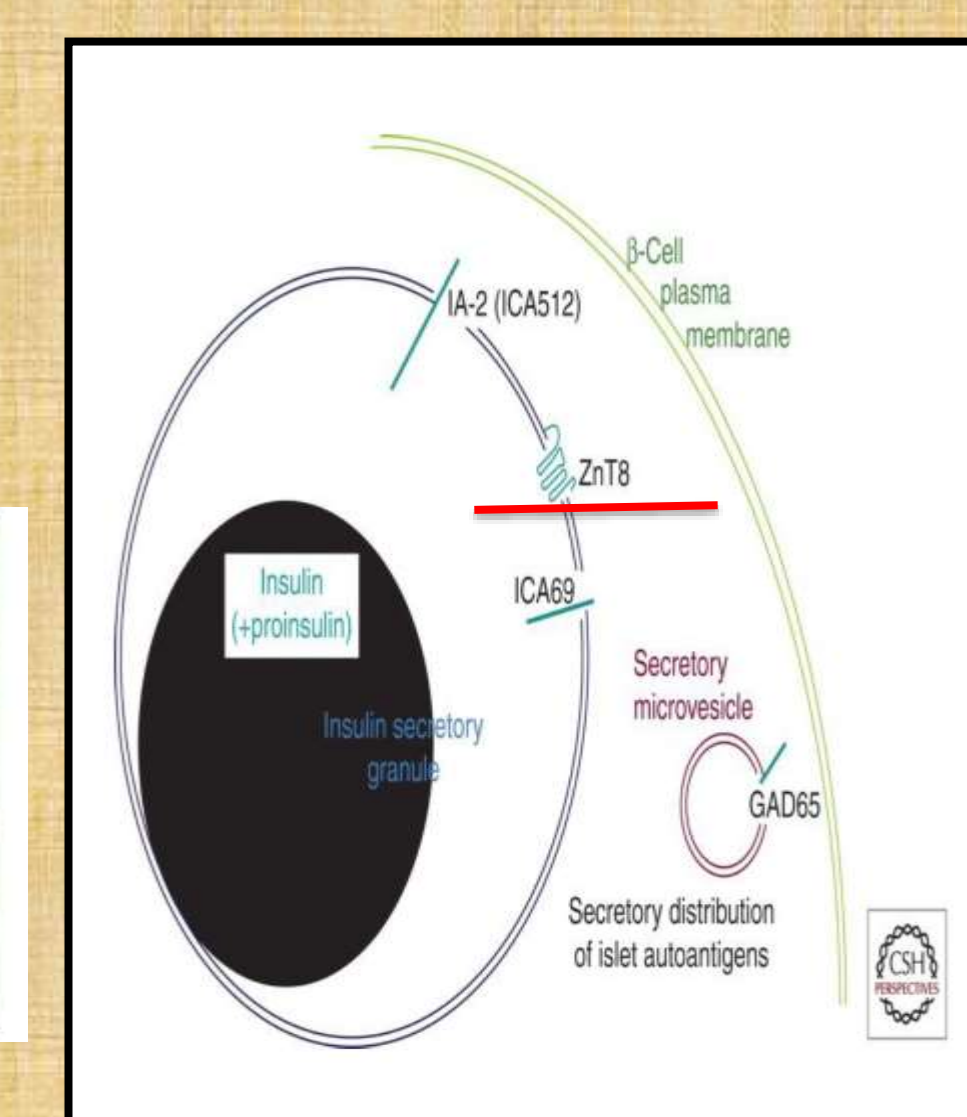
- \* **Zn homeostasis** is regulated by ZnT (SLC30A gene family) and Zip (SLC39A gene family) zinc transporters.
- \* **Zinc transporter 8** is localized in insulin containing secretory granule membrane and transports zinc from the cytosol into the vesicles. **ZnT8** contains six transmembrane domains and a histidine-rich loop between transmembrane domains 4 & 5, which is the putative zinc binding domain.
- \* **Human SLC30A8 gene** is located to **chromosome 8** at the position **q24.11** which contains 8 exons and encoding a 369 amino acid ZnT8 protein.
- \* **Zn** is important for the generation of proinflammatory cytokines: IL-6, TNF- $\alpha$  after LPS stimulations and development of T cells.
- \* **Zinc deficiency** induces thymic atrophy, lymphopenia, suppression of cytolytic T cell responses & NK activity.
- \* **Zinc protects** pancreatic B-cells from cytokine-induced destruction, which is observed in patients with DT1 & DT2.



Localization of ZnT8 transporter in a pancreatic  $\beta$ -cells



Localization of ZnT8 transporter in adrenal cortex in animal model



Murgia C et al. Nutrition, Metab. & Cardiovascular Dis (2009) 19, 431-439

Kawasaki E. Endocrine Journal 2012, 59 (7), 531-537

Immunolocalization of ZnT8 transporter using anti-ZnT8 antibodies (a, b) in epithelium of thyroid follicular cells in animal model.

## Material and Methods

We studied the expression of ZnT8 transporter in thyroid tissues from patients with immune and non-immune thyroid diseases. The study was performed in thyroid tissues after thyroidectomy from patients with thyroid nodular goiter (n=17, mean age 17.8 years  $\pm$  4) and cases with Graves' disease (n=20, mean age 15.6 years  $\pm$  2.8).

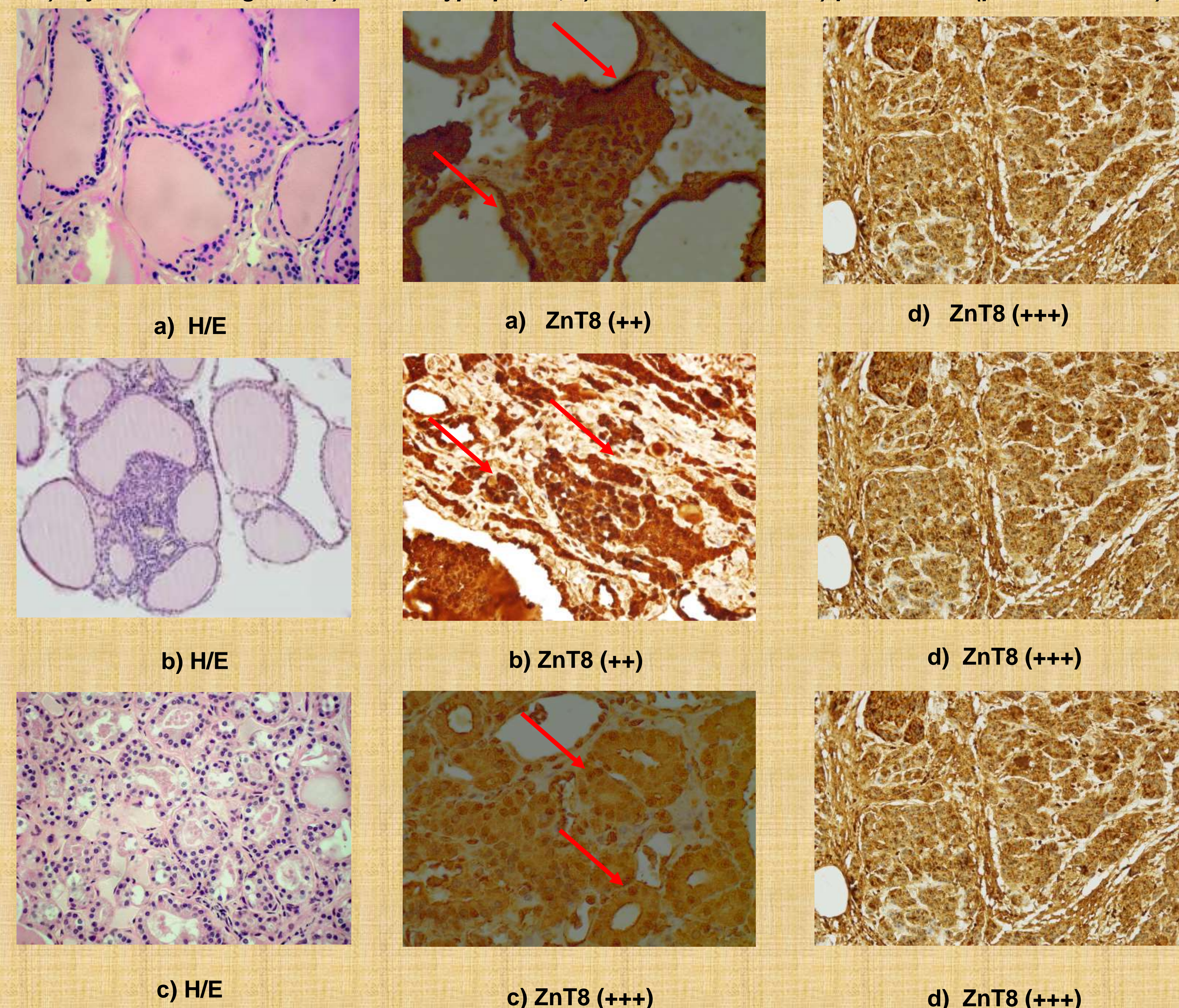
	Graves' disease	TNG	*p
Weight(kg)	56 $\pm$ 5.28	58.2 $\pm$ 7.8	NS
Height (cm)	158.6 $\pm$ 4.3	156 $\pm$ 8	NS
fT4 (ng/dl)	1.8 $\pm$ 0.63	1.2 $\pm$ 0.46	p<0.01
fT3 (ng/dl)	5.08 $\pm$ 0.5	3.2 $\pm$ 0.38	p<0.01
TSH ( $\mu$ U/ml)	0.87 $\pm$ 2.37	3.04 $\pm$ 0.72	p<0.01
TRAb (IU/l)	12.5 $\pm$ 0.31	0.4 $\pm$ 0.22	p<0.0001
anti-TGAb (IU/mL)	620.98 $\pm$ 240.34	98.6 $\pm$ 40.6	p<0.001
anti-TPOAb (IU/mL)	482.2 $\pm$ 62.43	56 $\pm$ 32.3	p<0.01
treatment	methimazole	L-thyroxine	

**Method:** The ZnT8 expression protein was evaluated using immunohistochemistry. The specimens were paraffin embedded tissues, derived from the pediatric patients, who had thyroid nodular goiter or GD. The antibody against ZnT8 was goat polyclonal antibody (Santa Cruz Biotechnology USA; sc-98243). The antigen retrieval was done using high pH (PTLink DAKO) and antibody was incubated in 4°C overnight in 1:50 dilution. The patients with pancreatitis were as a positive controls.

The intensity and the proportion of stained cells were determined by examining the entire slide and section as:  
 + (low staining intensity in less than 10% cells in the section);  
 ++ (moderate staining intensity in 10-40% cells in the section);  
 +++ (high and diffuse staining intensity in more than 50% cells in the section).

## Results

Identification of ZnT8 transporter in thyroid tissues by immunohistochemistry in patients with: a) thyroid nodular goiter, b) C cells hyperplasia, c) Graves' disease & d) pancreatitis (positive control)



## Conclusions

1. Expression of ZnT8 transporter was identified in the thyroid tissues from paediatric patients with Graves' disease and nontoxic nodular goiter.
2. ZnT8 transporter expression was found both in thyroid follicular cells and C cells.
3. Predominant expression of ZnT8 in immune than in non-immune thyroid disorders may suggest potential role of ZnT8 as a new thyroid autoantigen but it requires further study on a larger cohort.