

FAMILY CHARACTER ISOLATED PHEOCHROMOCYTOMA BY MUTATION IN VHL GEN

Concepción Freijo Martín^a, Maria Laura Bertholt Zuber^a, Luis De la Rubia Fernández^a & Cristina Naranjo González^a
Hospital Universitario Marques De Valdecilla, Santander (Cantabria), Spain

Background: Pheochromocytoma is an uncommon tumor in childhood, it is located in the adrenal gland and it secretes an excessive amount of catecholamines.

It is frequently hereditary, it is associated to genetic alterations, being involved more than 13 known genes, the most common is the gen RET.

Method: We presented the case of unilateral single family pheochromocytoma diagnosed in a father and his son, they both carried a single mutation in the VHL gene resulting a change of an arginine by a glycine in the Von Hippel Landau tumor suppressor protein (c.235C > G; p.R79G).

Case:

He is a male, 9 years old, with symptoms of fever, profuse sweating, intense headache and high blood-pressure 190/120.

-Family history: the father was intervened at the age of 40 of unilateral pheochromocytoma, without other adjacent pathology.

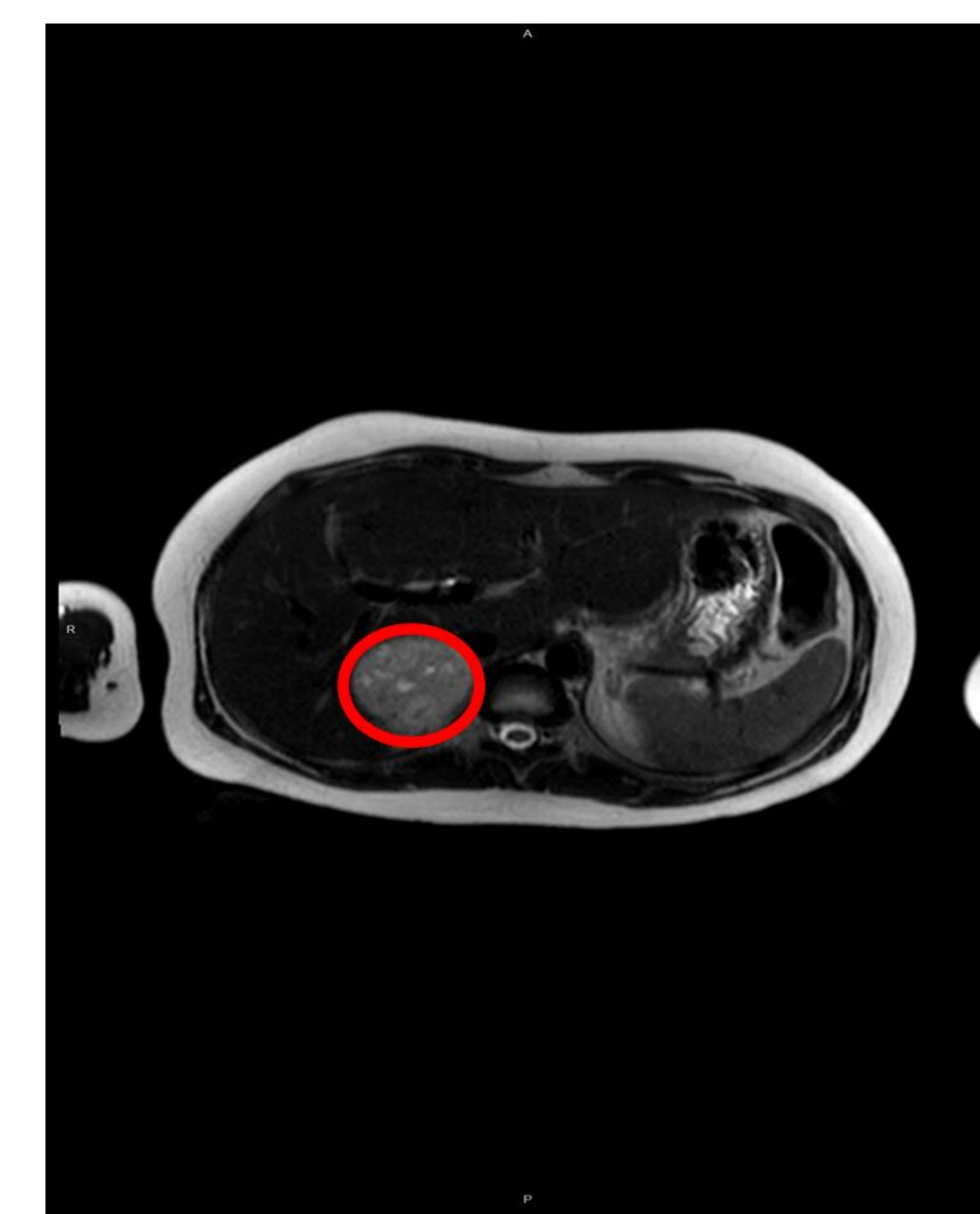
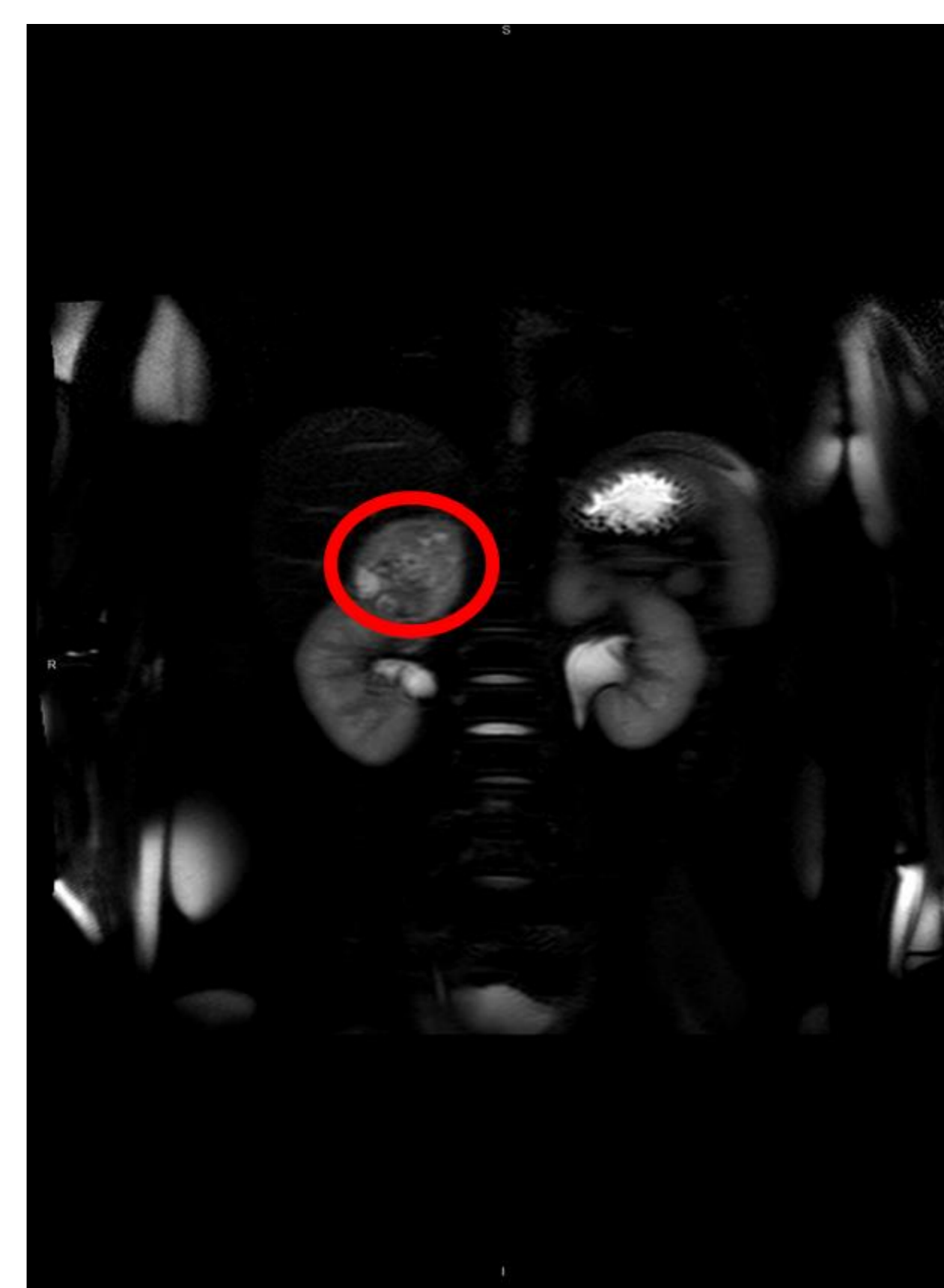
-Biochemical parameters at diagnosis: in blood: glucose 82 mg/dl, cortisol 26.7 µg/dl (3.1-22.4), ACTH 15 pg/ml (10-50), in urine: norepinephrine 1188 ug/24 H (15 - 80), Vanillylmandelic acid 57.6 mg/24h (2 - 8).

-Radiologic studies:

***Renal ultrasound:** identified a right mass 5.5 x 4.4 cm with cystic areas inside and mainly peripheral vascularization.

***Scintigraphy with I-123 MIBG:** pathological uptake in the right adrenal gland, without affecting other levels.

***MRI of abdomen:** right adrenal mass margins defined with cystic areas inside, this mass mark at the bottom contour of the liver and upper pole of kidney without signs of infiltration. Left adrenal gland is normal.



-Treatment : Surgical intervention by laparoscopy after performing block, first with alpha and then beta adrenergic, resecting the tumor completely. In the postoperative he needed important volume, vasoactive drugs and hydrocortisone which were withdrawn within 24 hours.

-Evolution: At the present, the child is asymptomatic with normal hormonal controls.

Conclusion: The genetic study in the child showed the mutation in the VHL gene, which is identical to the one that the father has, this supports that this mutation is associated with unilateral family pheochromocytoma undescribed until now.

pedfmc@humv.es

