



Unravelling the source of elevated β -hCG related to peripheral precocious puberty

Azad Ekberzade, Zeynep Atay, Saygın Abalı, Serpil Bas, Ziya Gurbanov, Tulay Guran, Serap Turan, Abdullah Bereket

Marmara University, Pediatric Endocrinology and Diabetes, İstanbul.

Peripheral precocious puberty (PPP) related to β -hCG secreting tumors (β -hCG-ST) is a rare cause of PPP in boys. β -hCG is usually secreted by germ cell tumors which are generally located in the intracranial region, whereas liver, testis and mediastinal cavity are other rare localizations.

PURPOSE: Here we present a patient with β -hCG-ST of which the localization was found after 6 years follow up and several operations. We aim to emphasize the diagnostic difficulties of β -hCG-ST.

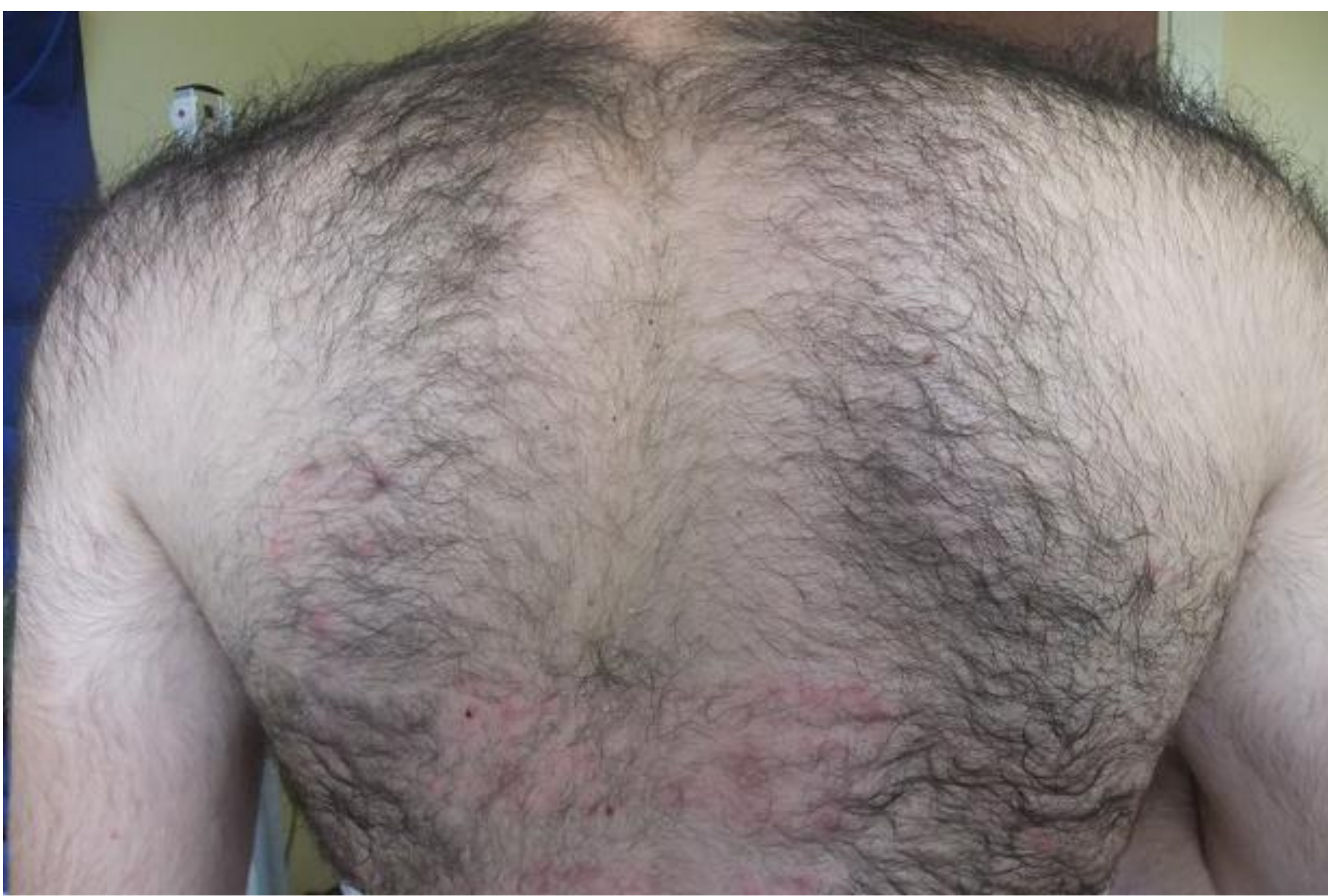

Figure 1: Severe hirsutism on the shoulders and back region of the patient at 10 years old.

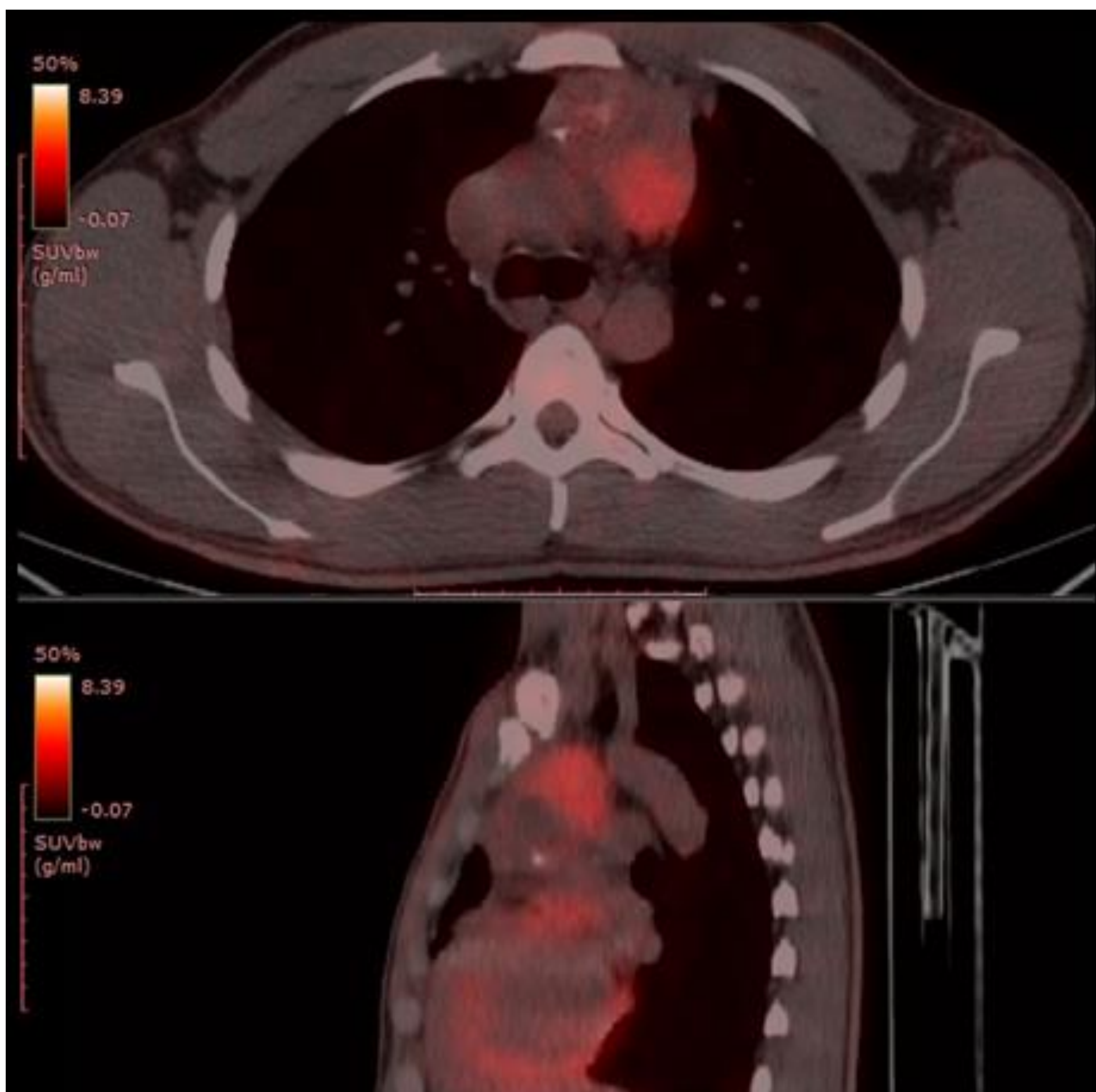


Figure 2: PET/CT of the patient performed due to severe elevation of β -hCG after 6-years follow up demonstrates mediastinal tumor.

CASE: 10.7 years old male patient presented with pubic hair development since the age of 8 years. On physical examination; height was 172 cm (+5 SDS), weight was 60.5 kg (+2.28 SDS), testis size was 10 cc bilaterally with genital and pubic hair staging of Tanner stage 5. Bone age was 16 years of age. Laboratory tests showed suppressed FSH and LH with highly elevated total testosterone, 3-4 x of Tanner stage 5 males (17 ng/ml), and elevated β -hCG level of 104 mIU/ml (0-5). Cranial MRI showed 7 mm contrast labeled pituitary lesion and trans-sphenoidal surgery was performed, however, β -hCG levels remained elevated after surgery. Furthermore, inferior petrosal sinus sampling was performed and no peripheral and central β -hCG gradient has been detected. Testis biopsy was performed due to microlithiasis of testis on USG and resulted mild hyperplasia of Leydig cells. Testicular arterial and venous catheterization also did not show any lateralization or any source of β -hCG production. PET/CT revealed uptake in mediastinal region and excisional biopsy was consistent with thymus hyperplasia. Fundus examination and echocardiography were also normal. Cranial, thorax, abdominal and pelvic MRI were repeated annually at follow-up with β -hCG of 100-154 mIU/ml levels. At 6th years of follow up, hCG levels abruptly raised to 2039 mIU/ml and 5.5 cm in diameter mass was detected at thorax CT. Tumor excision was performed and pathology was consistent with mixed germ cell tumor (70% mature teratoma, 30% seminoma). Karyotype analysis of tumor tissue was 47,XXY(15)/48,XXY,+MAR(12). Peripheral karyotype was 46,XY.

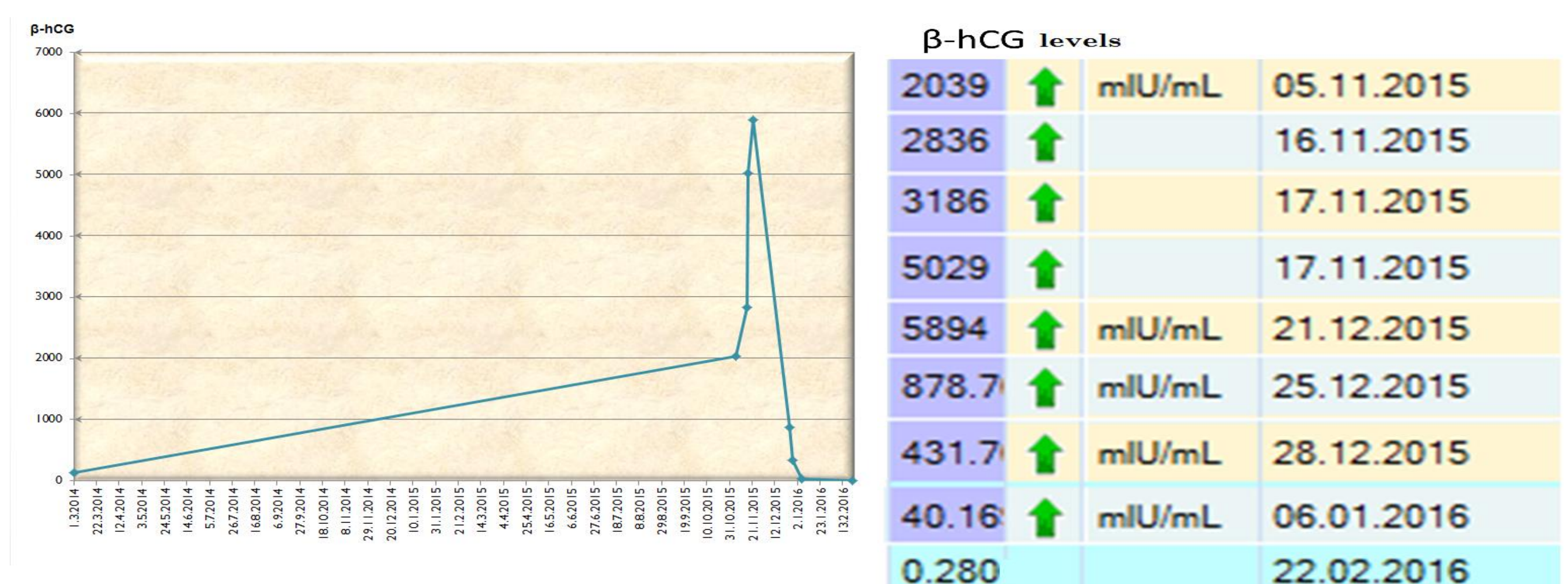


Figure 3: Progression of serum β -hCG concentrations during the follow up (left panel). High β -hCG levels turned to normal range after the excision of the tumor (right panel)

RESULT: β -hCG is important in diagnostic work up of peripheral precocious puberty. Sometimes its is difficult to localize the β -hCG ST, however, close follow up is mandatory for localization and treatment of these tumors.

