

Natacha Dillies¹, Aurélie Brasseur², Stéphanie Rouleau¹, Chantal Metz³, Catherine Naud-Saudreau⁴, Yves Morel⁵, Régis Coutant¹

¹ Pediatric Endocrinology, Angers University Hospital, France

² Pediatrics. Morlaix Hospital, France

³ Pediatric Endocrinology, Brest University Hospital, France

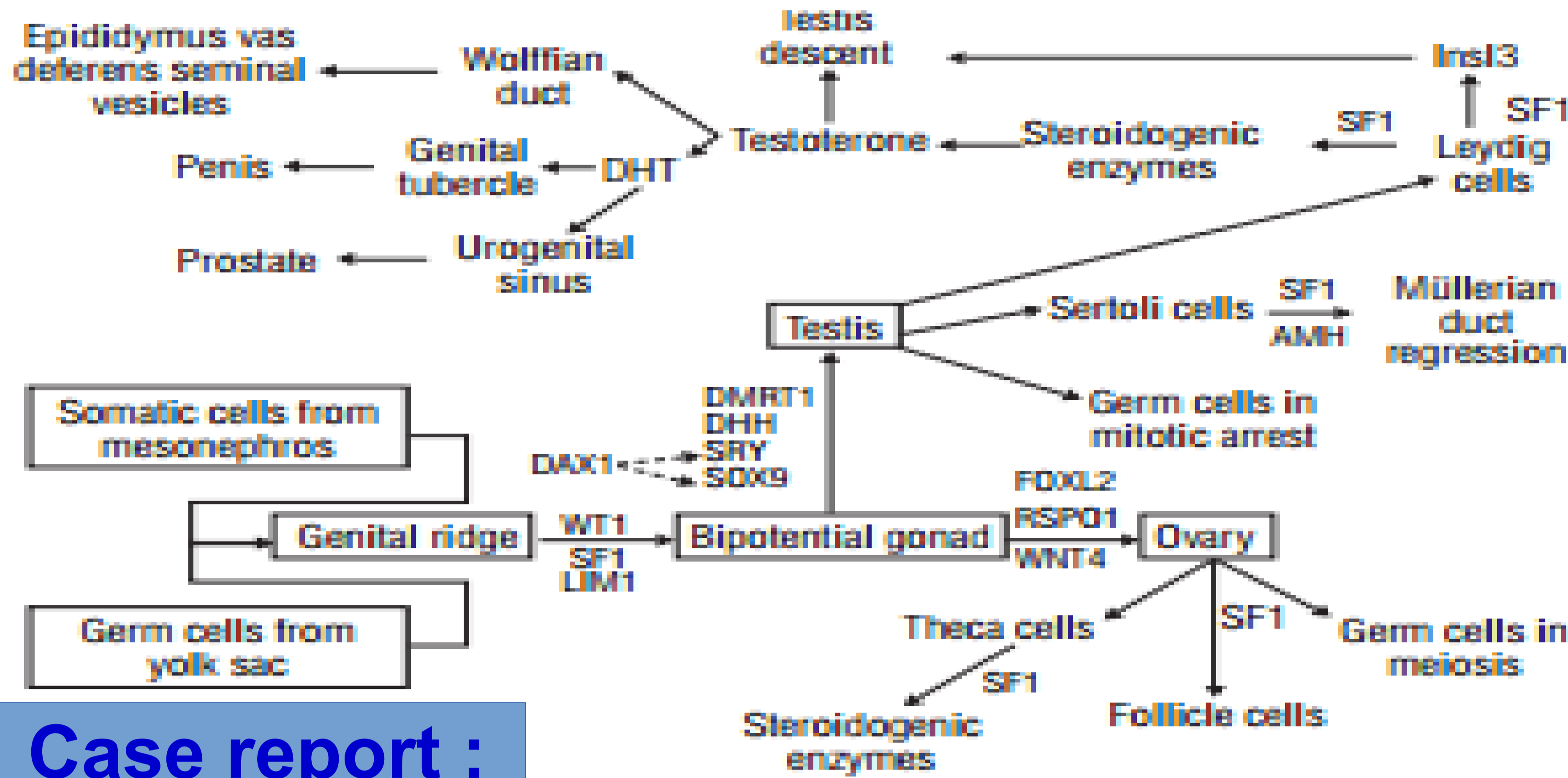
⁴ Pediatrics, Lorient Hospital, France

⁵ Molecular Biology, Lyon University Hospital, France

Introduction :

SF1/NR5A1 belongs to the family of orphan receptors located in chromosome 9. It is expressed in steroid tissue, hypothalamus and anterior pituitary. It plays a role in steroidogenesis, sexual and adrenal development. 46,XY patients with SF-1 mutations have sex reversal or ambiguous genitalia (with or without normal adrenal function) due to dysgenetic testis, with or without Mullerian structures. In most cases, a severe defect in testosterone (T) production has been found owing to dysgenetic gonads. We report 3 cases of SF1-mutations with variable clinical and hormonal phenotype (1).

Role of SF1 (2) :



Phenotypic variability of SF1-mutations (1) :

Complete gonadal dysgenesis

Genital ambiguity

Penoscrotal hypospadias

Micropenis

Cryptorchidism, anorchia

Infertility

Case report :

A was seen at the age of 17 years for primary amenorrhea. Pubic hair appeared at the age of 13, and breast at 14. Tanner stage was B2PH3. External genitalia were normal. FSH was 55 IU/L, LH 17 IU/L, inhibin B <10 pg/mL, AMH 0.3 pmol/L, testosterone 0.22 ng/mL, E2 <10 pg/mL, and DHEA-S 2.4 mg/L. Pelvic ultrasound showed a small uterus, and gonads with no follicles. Karyotype was 46,XY, and a p.Arg362X mutation of NR5A1 was found.

B was born at term with microphallus (L 2.5 cm), penoscrotal hypospadias, and normal scrotum with 2 palpable gonads. Karyotype was 46,XY. T at d13 was 4.5 nmol/L, increasing to 11.8 nmol/L upon hCG stimulation. FSH was 2.9 IU/L, and LH 1.6 IU/L. He was raised as a boy. He entered puberty at 13.5 years, with testis length 3.5 cm. T was then 24 nmol/L, FSH 19 IU/L, LH 10 mIU/L, INHB 65 pg/mL, and AMH 1.7 ng/mL. A p.Val83Met NR5A1 mutation was found.

C was born at term with DSD (genital tubercle 10 mm, fused genital swellings with 2 palpable gonads, and 1 orifice). Karyotype was 46,XY, T was 0.35 nmol/L, and at 1.5 month FSH was 5 mIU/L, and LH 0.8 mIU/L. C was raised as a girl and gonadectomy and feminizing genitoplasty was performed at 2 months. At the age of 11 years, ACTH was 191 pg/mL and cortisol 1.3 µg/dl, indicating adrenal insufficiency. A p.C422X NR5A1 mutation was found.

Hormonal dosage depending on the age

	Neonatal period			Puberty			Adult		
	FSH UI/L	LH UI/L	T nmol/L	FSH UI/L	LH UI/L	T nmol/L	FSH UI/L	LH UI/L	T nmol/L
A							55	18	0,8
B	2,9	1,6	4,5	19	10	24			
C	5	0,8	0,35						

Discussion :

These three cases illustrate the phenotypic and hormonal variability in patients with 46 XY SF1-mutation. A long term clinical and hormonal follow of the adrenal and gonadal function is essential.

References :

1, Pedace L et al. Am J Med Genet A. nov 2014;164A(11):2938-46.111

2. Mello MP de et al. Metabol. nov 2011;55(8):607-12. Endocrinol

The authors have no conflict of interest.