

A RARE CAUSE OF SHORT STATURE: PATIENT WITH 3M SYNDROME REVEALED A NOVAL MUTATION IN *OBSL1* GENE

Melikşah Keskin, Nursel Muratoglu Sahin, Erdal Kurnaz, Elvan Bayramoglu, Şenay Savas Erdeve, Zehra Aycan, Semra Caglar Çetinkaya

Dr. Sami Ulus Obstetrics and Gynecology and Pediatrics Training and Research Hospital, Ankara-TURKEY

INTRODUCTION

The 3M syndrome is characterised by dysmorphic features, skeletal abnormalities, severe prenatal and postnatal growth retardation with normal intelligence. The nomenclature 3M was derived from the initials of the surnames of three researchers who first identified the condition: namely, Miller, McKusik and Malvaux. Although 3M syndrome is considered to be a relatively uncommon disorder, it is thought to possibly be an under-diagnosed condition

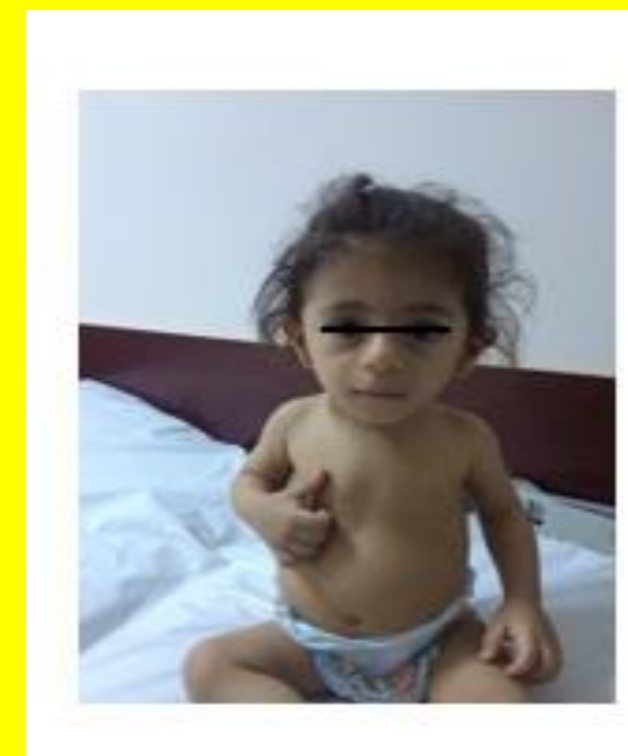CASE PRESENTATION

A-one year and four month-old female patient admitted to our clinic with the complaint of a growth and developmental delay

39th week of gestation with a birth weight of 1740 grams and body height of 42 cm

No known prior case of hereditary disease in her family

Maternal height:164 cm
Paternal height: 187 cm
Midparental height:169 cm



Physical Examination

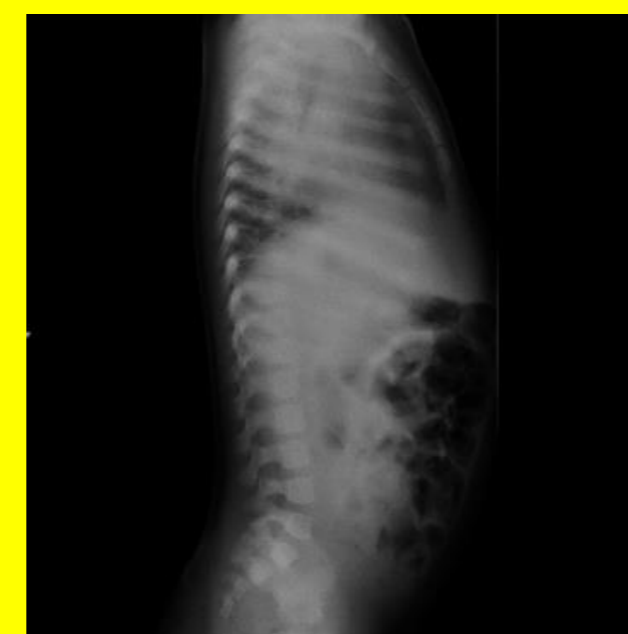
Height: 69 cm (-3.8 Sds)
Weight: 7.2 kg (-3,5 sds)
Head circumference: 42 cm

A fleshy nose tip

A long philtrum

Prominent mouth and lips with a pointed chin

Significant lumbar lordosis and prominent heels



Laboratory Analyses

Hg: 12.3 g/dl

BUN:13 mg/dl

Cr:0.41 mg/dl

ALT: 21 U/L

AST:43 U/L

TSH:1.04 mIU/ml

Ft4:1.25 NG/DL

Tissue Transglutaminase ig A: Negative

Anti-endomysial antibodies: Negative

IGF-1:47 ng/dl (< -2 SD score)

IGFBP-3: 2800 mg/ml (between +1/+2 SD score)

Bone Age: 1 year

Karyotype 46,XX

Whole Gene Sequence Analysis

Homozygous p.T45Nfs*40 (c.1273 dupA) mutation of *OBSL1* gene

CONCLUSION

The 3M syndrome may be more frequent than thought in countries where kin marriage is often practiced, as is the case with Turkey. Pointing out this fact may help clinicians consider early diagnosis for future patients, hence revealing increasing amounts of cases in the near future. Our experience with previous 3M diagnoses is an example to this fact, as our case, which can be identified as a case of early diagnosis, could have been diagnosed mainly with respect to our prior knowledge regarding 3M syndrome. It was previously reported that final body heights of the 3M syndrome patients range between 115 and 150 cm, which can lead to significant degrees of disadvantage in these individuals' lives. We agree on the possibility that, as our patient is of a very young age, the initiation of GH treatment can, with a high chance, lead to a near-normal body height if GH effects are to be successful. Due to the fact that 3M syndrome is inherited via an autosomal recessive, early genetic assessment leading to an early diagnosis can also aid in the genetic counselling for the rest of family members. In conclusion, patients with growth and developmental delay, especially with prenatal onset and characteristic symptoms, should be considered for differential diagnosis of 3M syndrome

