

Hyperphosphatemic familial tumoral calcinosis: novel indication to sevelamer carbonate

¹NA. Fuentes-Bolanos; ¹L. Canovas Sánchez; ¹M. del Toro Codes; ¹G. Martinez Moya; ¹M. Natividad Pedreño and ¹J. Del Cuz Moreno
¹Complejo Hospitalario de Jaen, Jaen, Spain

Non-disclosure statement

Introduction

Hyperphosphatemic familial tumoral calcinosis (HFTC) is a condition characterized by hyperphosphatemia and abnormal deposit of phosphate and calcium most often around the hips, shoulders and elbows and rarely in the brain.

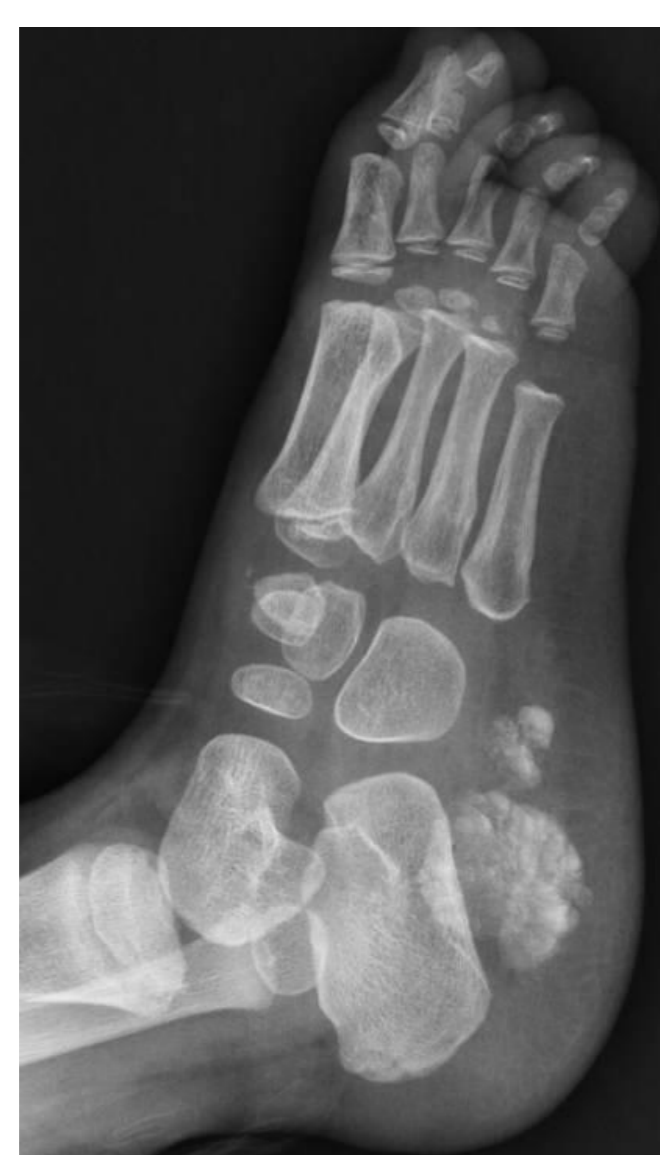Case report

4yr old female referred from the Orthopedics Team due to: recurrent calcinosis of the right calcaneus and incipient right wrist pain.

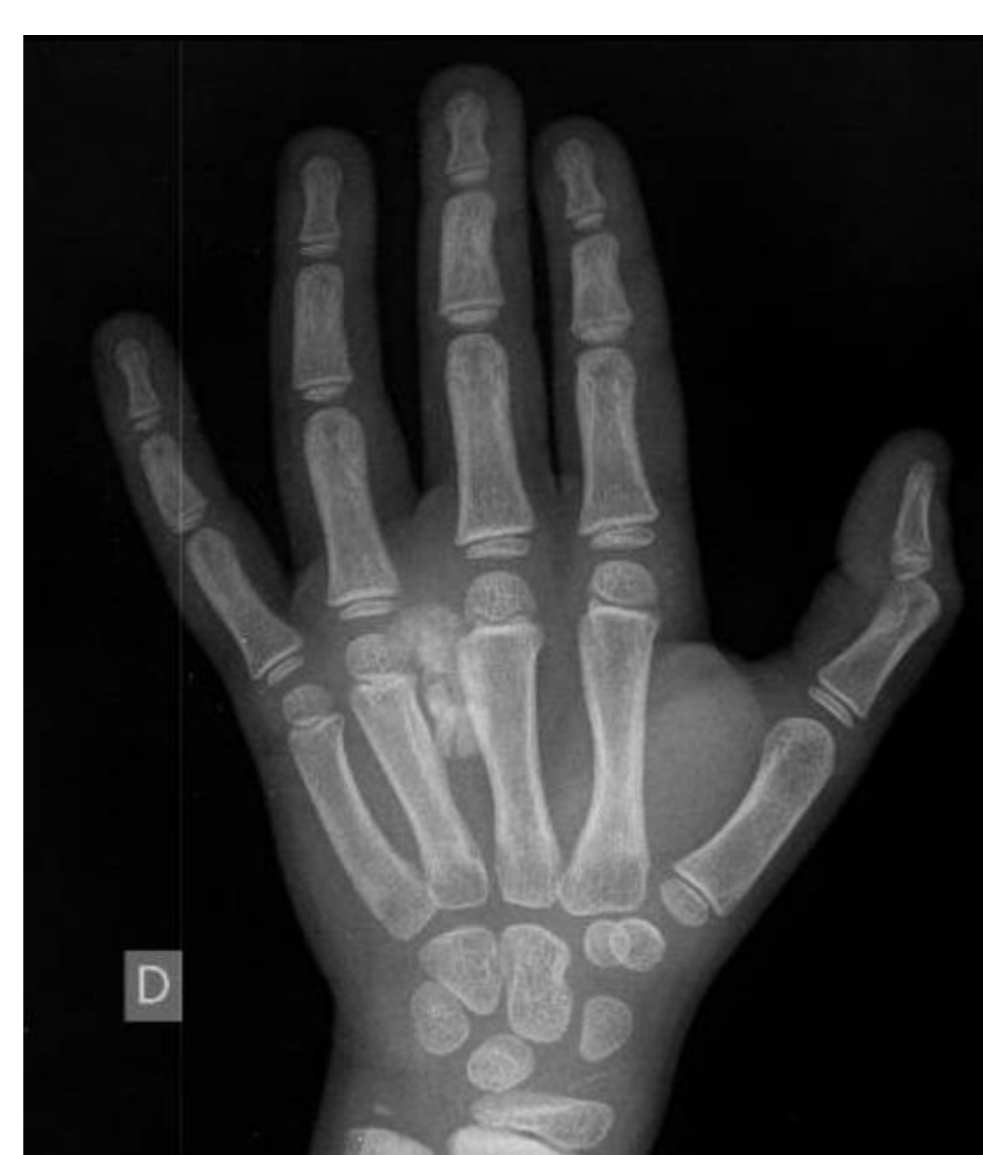Past medical history: no significant
Family history: no significant

Examination

- Growth parameters: adequate by age (height 0.24SD, weight 0.19SD).
- General examination unremarkable.



Right Foot X-ray



Right Hand X-ray

Investigations

Initial investigations

- Serum Na, Cl, K and Cr levels: normal range
- Serum calcium 9.9 mg/dl [N: 8.1- 10.4]
- Phosphorus 8.6 mg/dl [N: 2.7- 4.5]
- Magnesium 2.1mg/dl [N: 1.7- 2.5]
- Intact parathyroid hormone 24.2 pg/ml [N: 15- 88]
- 25-vitamin-D 19 pg/ml [N: 12- 54]
- Random urinary calcium/creatinine ratio 0.015 (TmP/GFR 3.9mg/100ml).

Second line investigations

Genetic test: homozygosity for the mutation c.814_815 insA in the GALNT3.

Further investigations:

- No eye abnormalities
- No cardiac/coronary calcifications,
- No pathological features on kidneys ultrasound scan.
- Head CT scan: **bilateral superficial linear brain calcifications.**

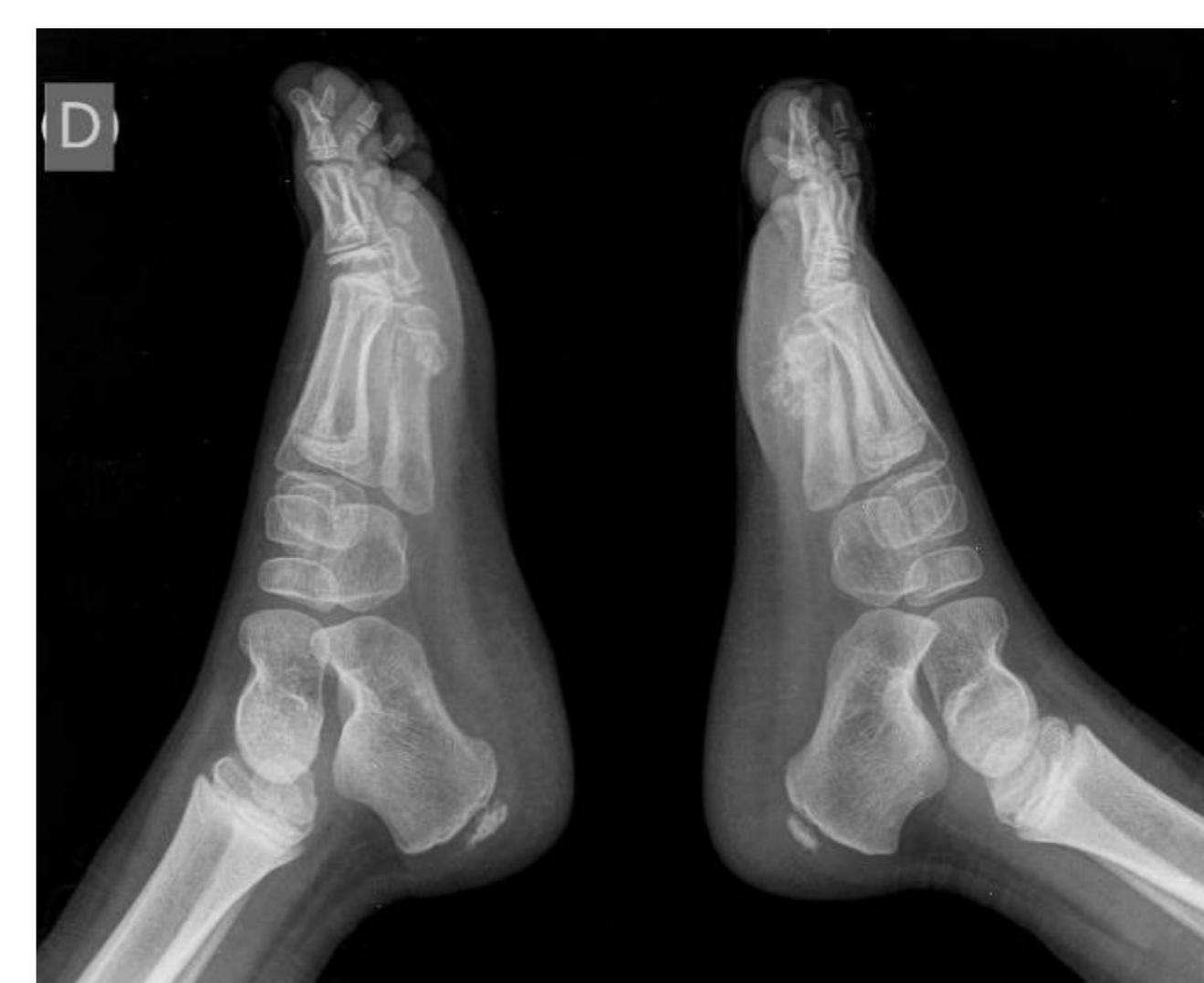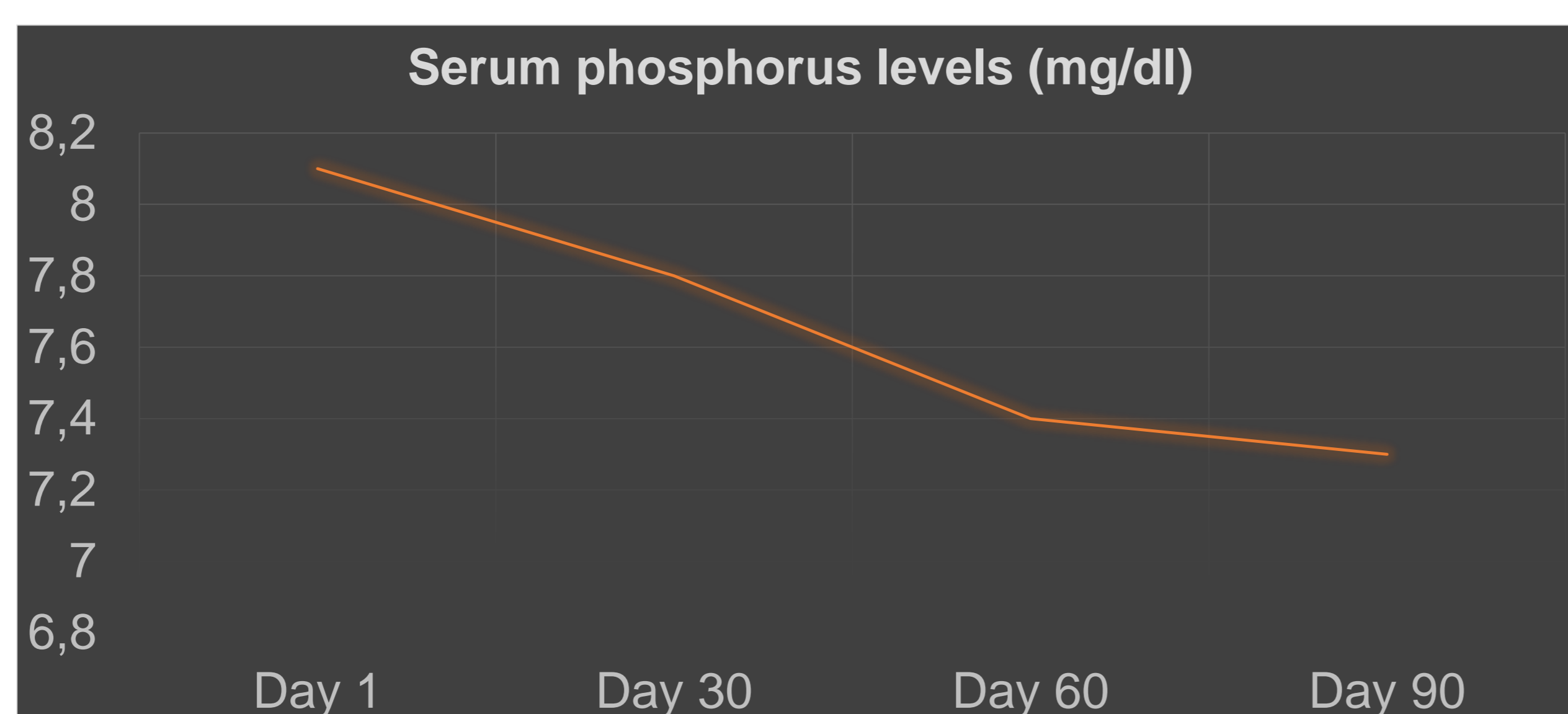
Diagnosis: hyperphosphatemic familial tumoral calcinosis

Initial management: low phosphorus diet intake and calcium acetate

Follow up:

- Biochemical results: phosphorus 8,1 mg/dl and TRP 98.6%.
- Clinical evolution: new joints pain.

Novel indication: Sevelamer carbonate... (800mg, 12hourly, via oral)



Feet X-ray

Discussion

1. In cases of calcinosis in paediatric patients, phosphorus and calcium metabolism assessment is recommended as part of initial approach in order to avoid future complications.

2. Management of hyperphosphatemia is complex in hyperphosphatemic familial tumoral calcinosis.

This case suggests sevelamer carbonate as an option to decrease serum phosphate levels in the setting fail in previous known therapeutic options.

Poster Number: P2- 183
Fuentes-Bolanos, NA.
Email: noemi.fuentesb@gmail.com

