

## Background

T-box factor (*TBX19*) is the first T-box gene identified in the pituitary and encodes T-box pituitary restricted transcription factor (TPIT). TPIT is important for both proopiomelanocortin (POMC) gene expression and differentiation of cells expressing POMC. Biallelic mutations in *TBX19* gene causes severe early-onset adrenal failure due to isolated ACTH deficiency (IAD) associated with low plasma ACTH and cortisol. Pituitary gland is structurally normal.

Here, we report a patient with IAD due to a novel *TBX19* mutation with an emphasis on pubertal and physical growth characteristics.

## Case

- 4<sup>8/12</sup> years old girl was admitted to the pediatric emergency unit with loss of consciousness. She was found to be hypoglycemic with a capillary glucose of 25 mg/dL (1.4 mmol/L). Her parents were first degree cousins. She was born at term and birth weight was 3800 g (1.6 SDS). She had been hospitalized for 10 days in a neonatal care unit for mild respiratory disease. Her brother died at postnatal third day with unidentified etiology and a preterm born sister died at postnatal 23<sup>rd</sup> day after an operation for esophageal atresia. Her first teeth eruption was late (18 months) and she had began to walk at the age of two. At about 3 years of age, she had recurrent seizures especially in the morning after a prolonged fasting.
- At her presentation, weight and height were 23.1 kg (1.8 SDS) and 116.5 cm (2.2 SDS) respectively. She had no facial dysmorphism, hypo/hyperpigmentation or red hair (Figure 1). Cardiac and abdominal examination were normal. Her pubic and breast stages were Tanner I and bone age was 7.8 years at admission. At initial evaluation her developmental milestones were (gross motor, communication and language) delayed for her chronological age. However, fine motor skills were appropriate for chronological age.
- Pituitary MRI was normal.
- Central adrenal insufficiency due to ACTH deficiency was diagnosed and hydrocortisone treatment (10 mg/m<sup>2</sup>/day) was started. Her hypoglycemic episodes and recurrent infections recovered after hydrocortisone replacement.
- Her height SDS were in the upper range at admission and during follow up. In the first year of follow up, height was +1.6 SDS. Her pubic and breast stages were Tanner I.
- At the age of 5<sup>4/12</sup> years, she had Tanner 2 breast development with high basal serum LH value (0.63 mIU/ml) and bone age was between 7.8-8.8 years. Pelvic USG revealed enlarged ovaries. LHRH stimulation test was in prepubertal ranges.
- At the last visit when she was 6<sup>9/12</sup> years of age, her weight and height were 26.8 kg (1.1 SDS) and 126.1 cm (1.3 SDS), respectively.

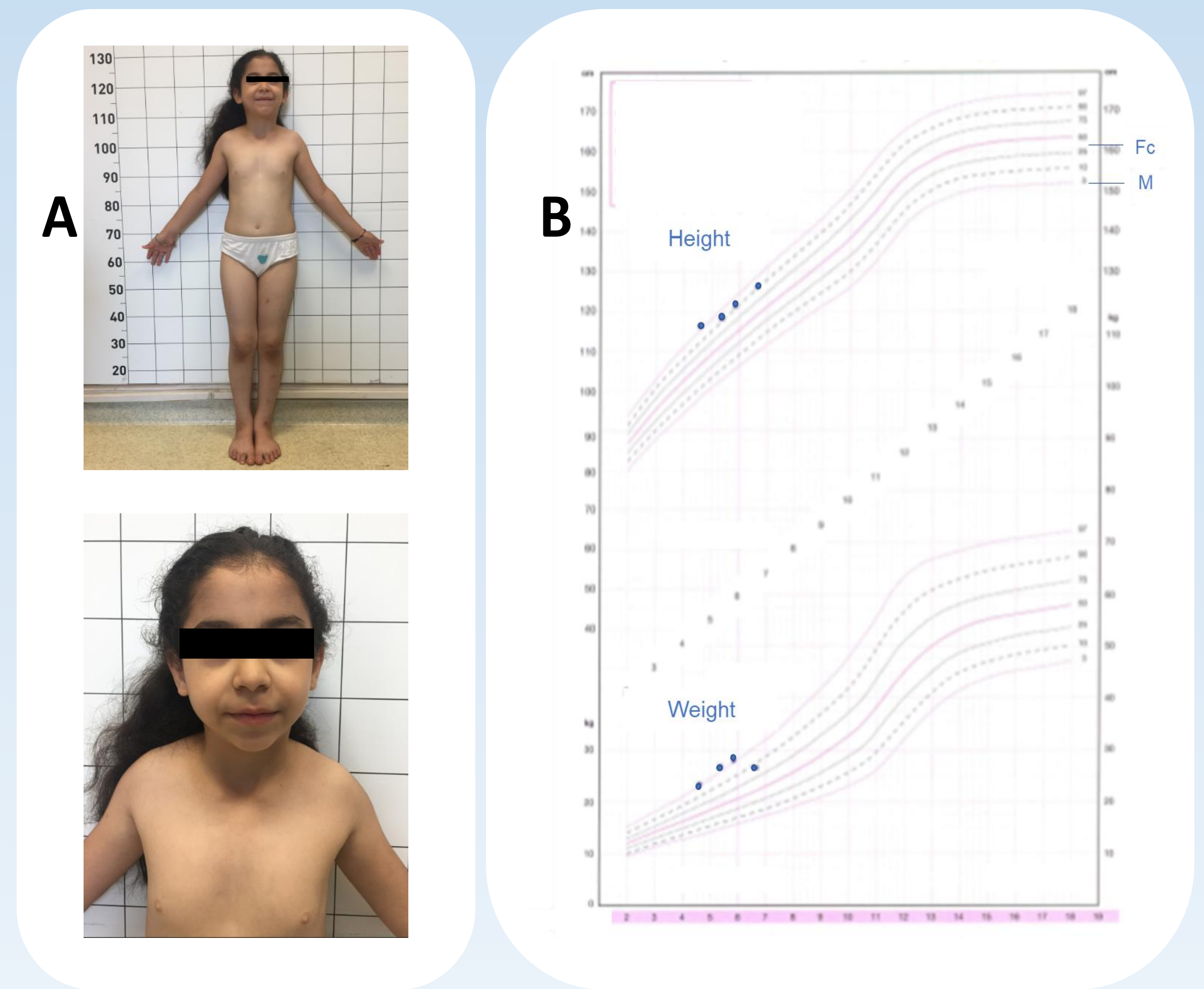


Figure 1. A. Patient at the last evaluation B. Growth chart of the patient

Table 1. Laboratory investigations

	At the presentation	At last evaluation
Age (years)	4 <sup>8/12</sup>	6 <sup>9/12</sup>
Serum glucose (mmol/L)	1.4	4.0
Na (mmol/l)/K (mmol/l)	135/4.5	143/4.3
Blood pH/HCO <sub>3</sub>	7.38/25.8	
Insulin (2.6-24.9µIU/ml)	0.2	
ACTH (0-46 pg/ml)	< 5.0	<5.0
Cortisol (5-25µg/dl)	0.1	
Prolactin (4.1-18.4 ng/ml)	23.1	19.0
FT4 (0.61-1.12 ng/dl)	1.1	0.97
TSH (0.34- 5.6µIU/l)	6.1	4.27
Peak cortisol response to low dose (1µg) ACTH	0.4	
IGF1 (ng/ml)	<25	76.8
IGFBP3 (µg/ml)	1.0	3.0
Genetic abnormality (by WES)	<i>TBX19</i> gene homozygous c.302G>A (p.Trp101Ter) (novel) (Figure 2)	

## Conclusion

We reported a novel mutation in the *TBX19* gene in a patient with isolated ACTH deficiency. While overgrowth is a known feature of some types of familial glucocorticoid deficiency, it may be a novel feature for IAD as in our patient.

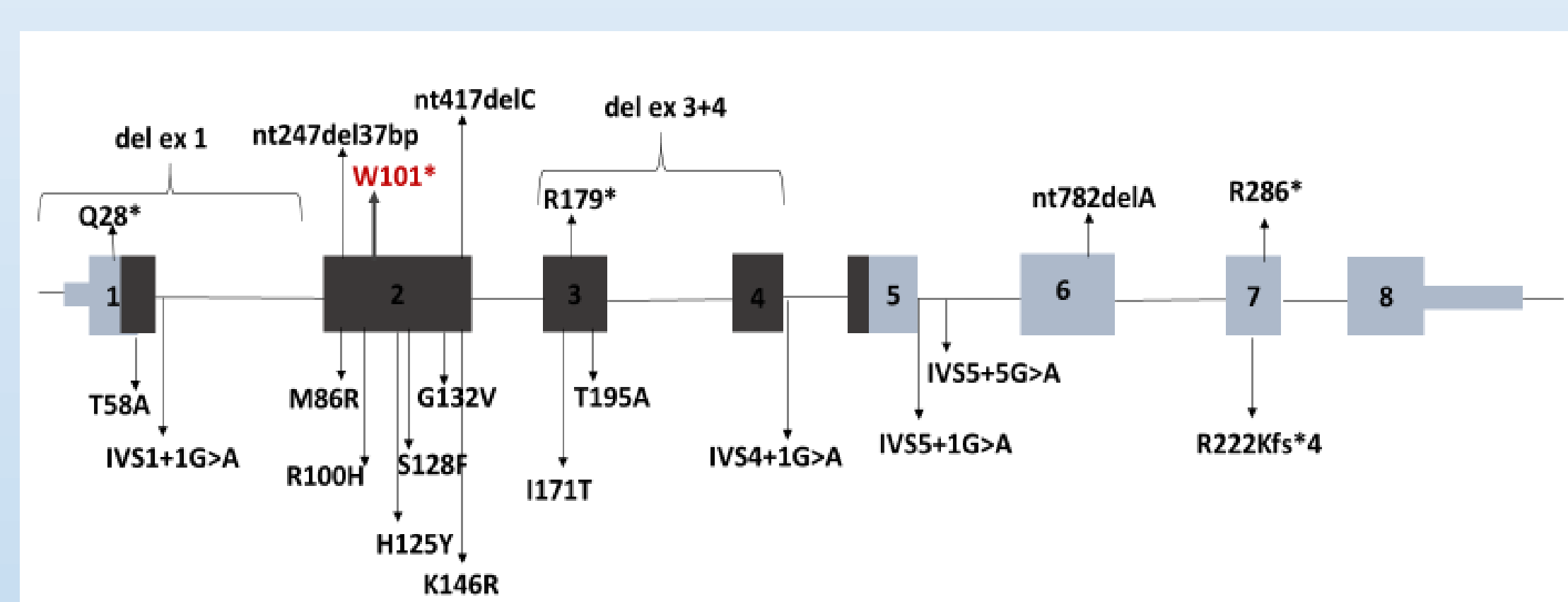


Figure 2. *TBX19* mutations identified in isolated ACTH deficiency patients. W101\* mutation found in our patient is indicated in red.