



Adequate interpretation of cortisol level in children

M Chueca, M Villarreal, C Andrés, S Berrade, T Durá, LM Nova, P Rodriguez
Pediatric Endocrinology, Pathology and Radiology. CHN, Pamplona, Spain.



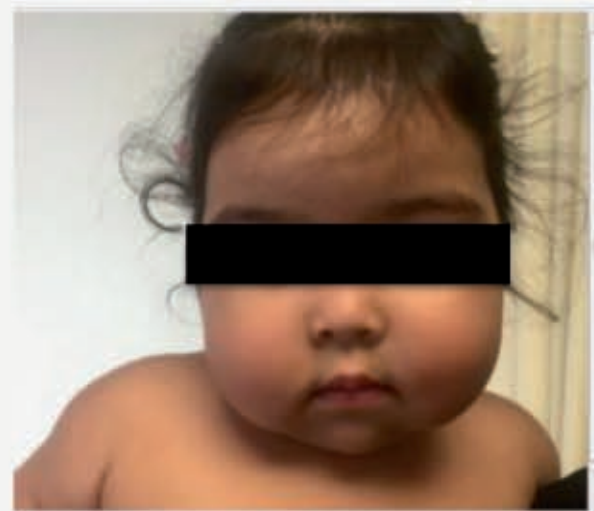INTRODUCTION

Adrenocortical tumours are a rare disease in the paediatric population, with a higher prevalence in children under 5 years. The aetiology is partially known; in some cases it is related to mutations in the tumour suppressor gene p53 (TP 53). The classical symptoms of the Cushing syndrome are not usually present in children, so we should suspect this disease in children and teenagers with obesity or with slow growth velocity.

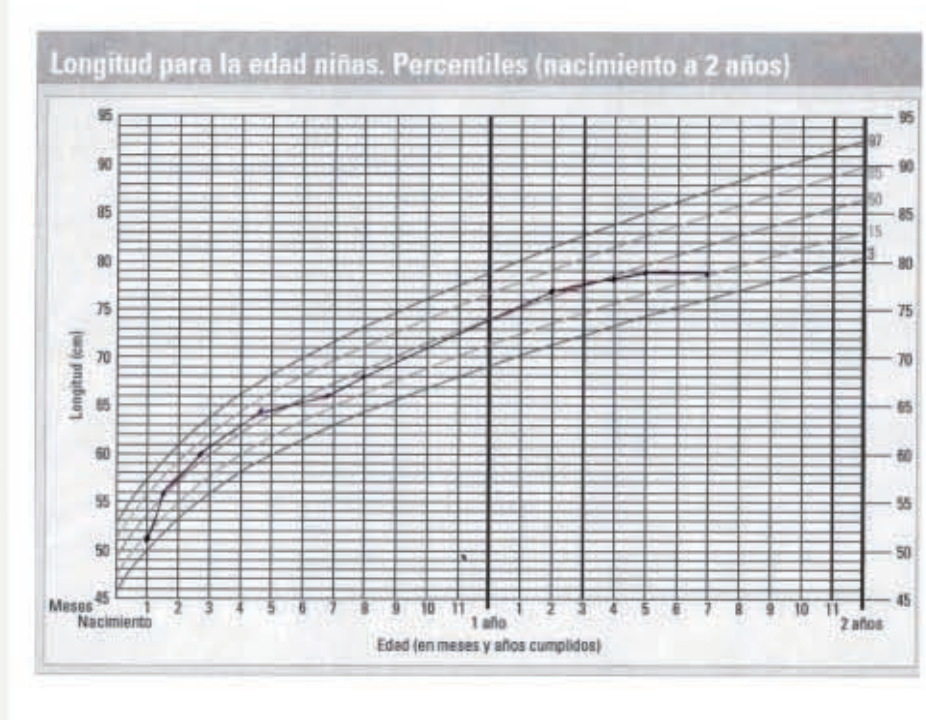
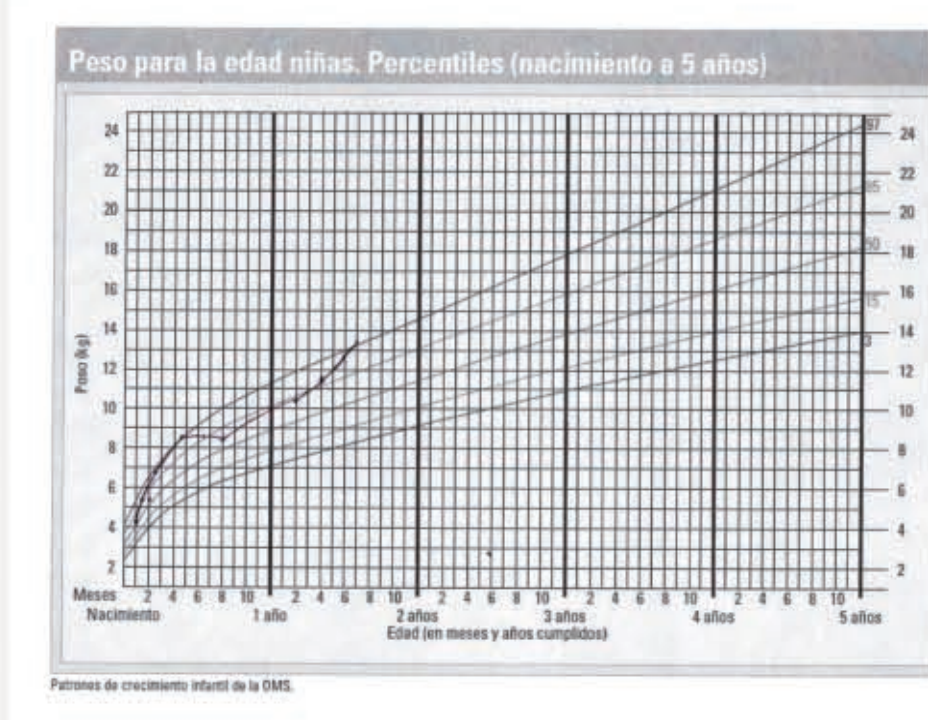
We report a case of adrenal tumour in which cortisol levels at diagnosis were in the normal reference range for age.

CASE REPORT

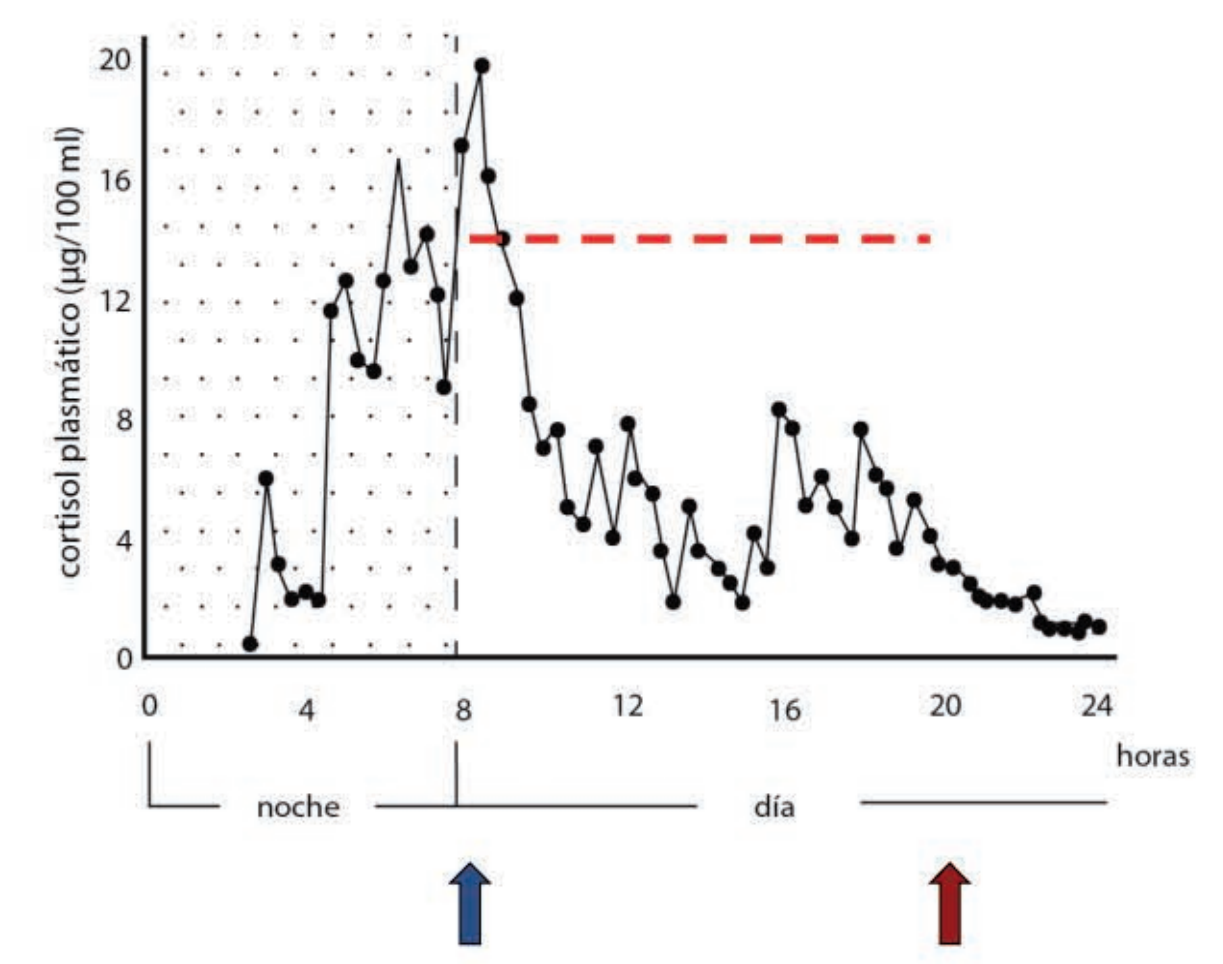
An **18 month old girl** was referred to the endocrinology unit because of **obesity**. She showed no other symptoms or personal background of interest.



BMI: 21,5 kg/m² +3,21 DE
BP: 114/74 mm Hg P 90/97



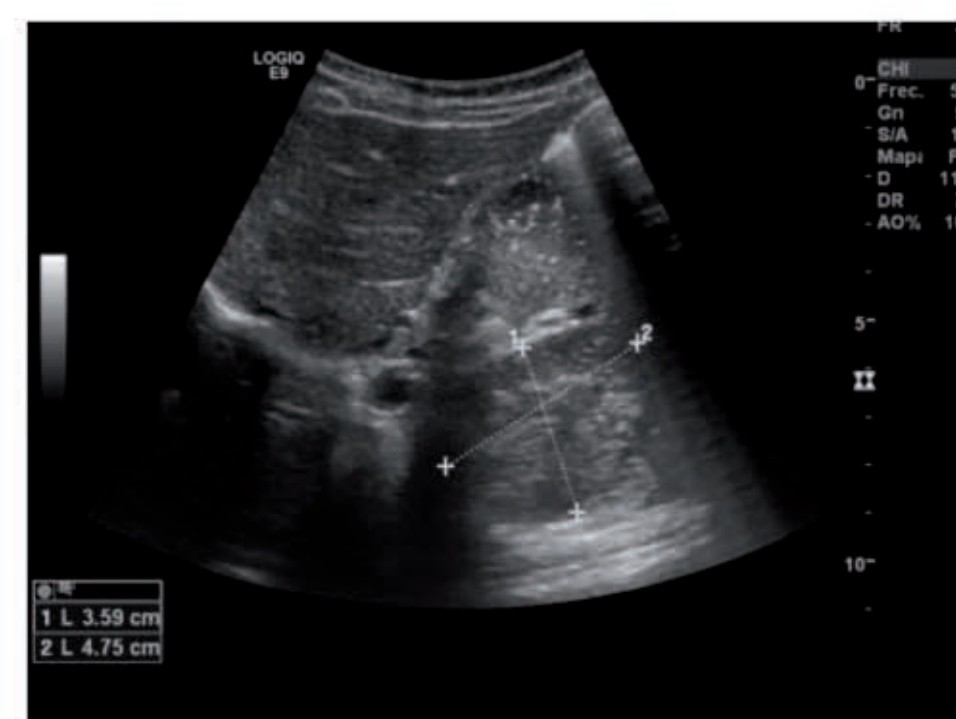
The endocrine analysis showed cortisol levels within normal range, 14,8 ug/dl (VN 5-18), Cortisol levels at 8:00 pm showed a loss of normal circadian cycles (14,1 ug/dl), with suppressed ACTH levels 2 pg/ml (VN 10-46).



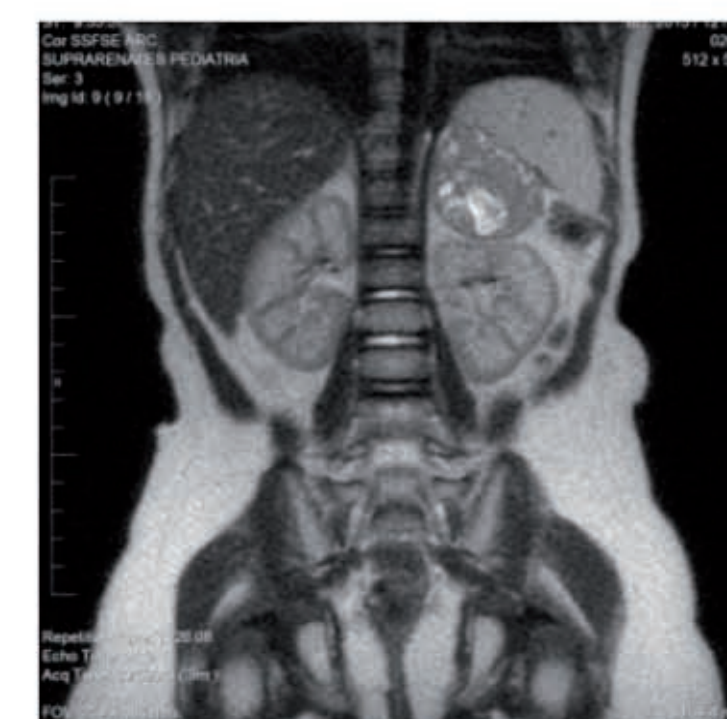Cortisol levels were not suppressed after the short dexamethasone test (13,8 ug/dl).

With the suspicion of a cortisol producing adrenal tumour the study was completed with image tests.

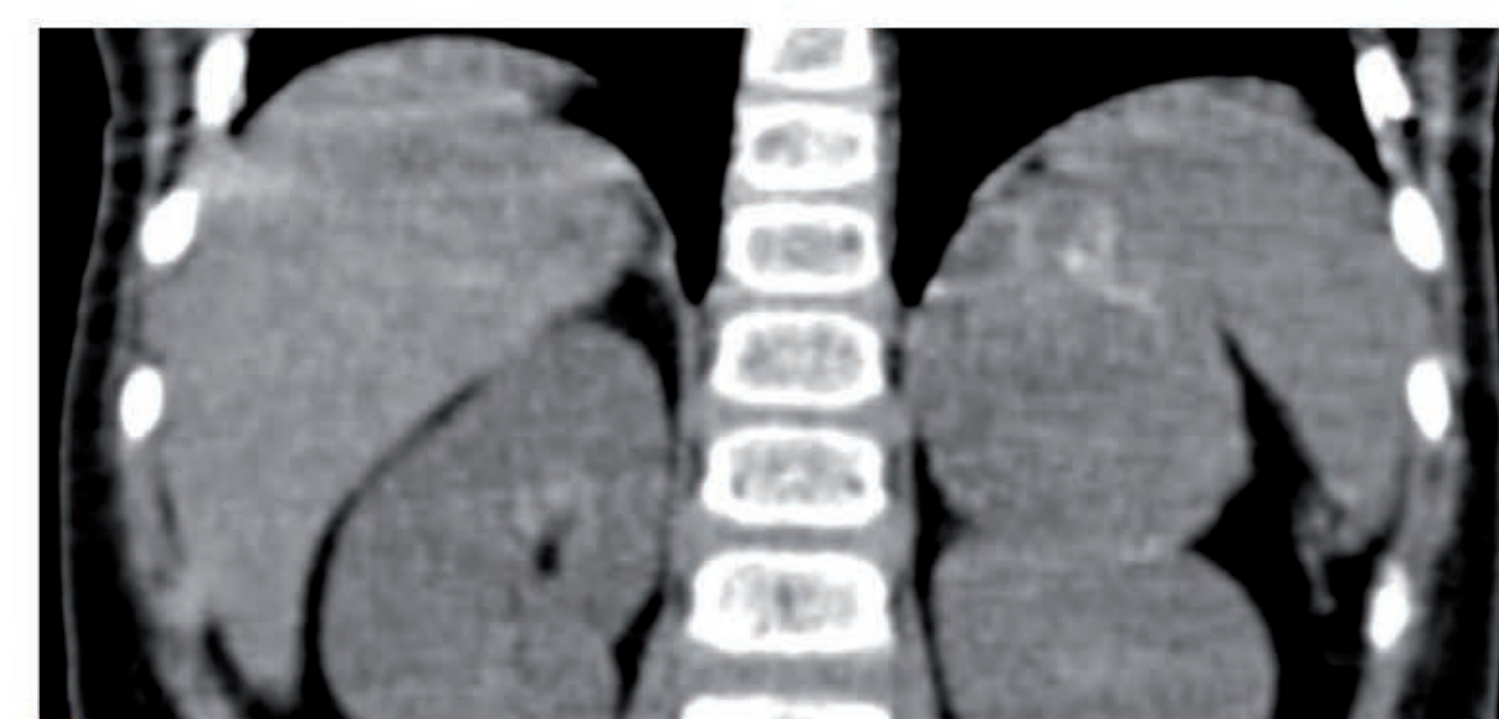The images were compatible with left adrenal neuroblastoma (diameter 41,5 cm), so an extension study was performed with catecholamines in urine, enolase and MIBG scintigraphy; they were all negative.



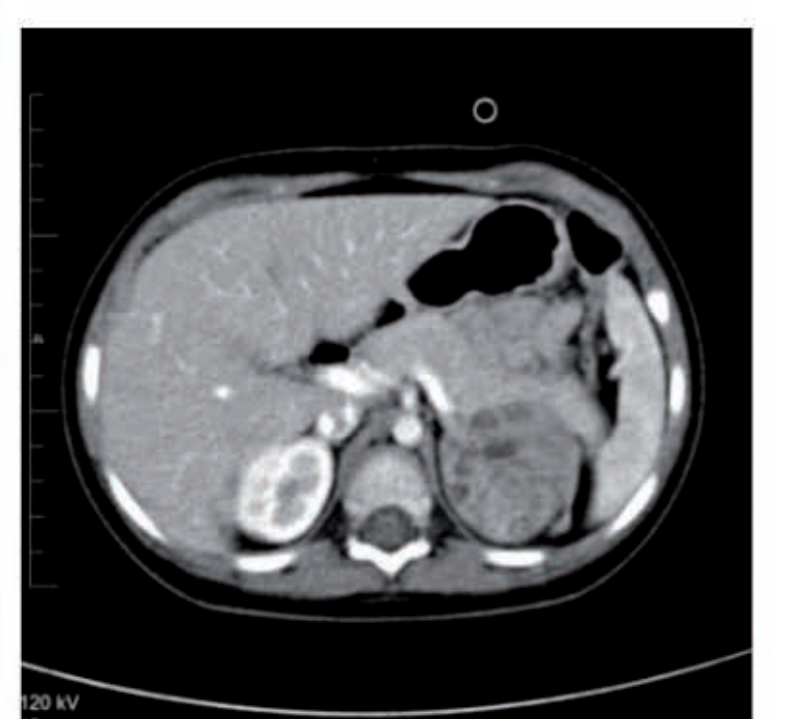ULTRASOUND



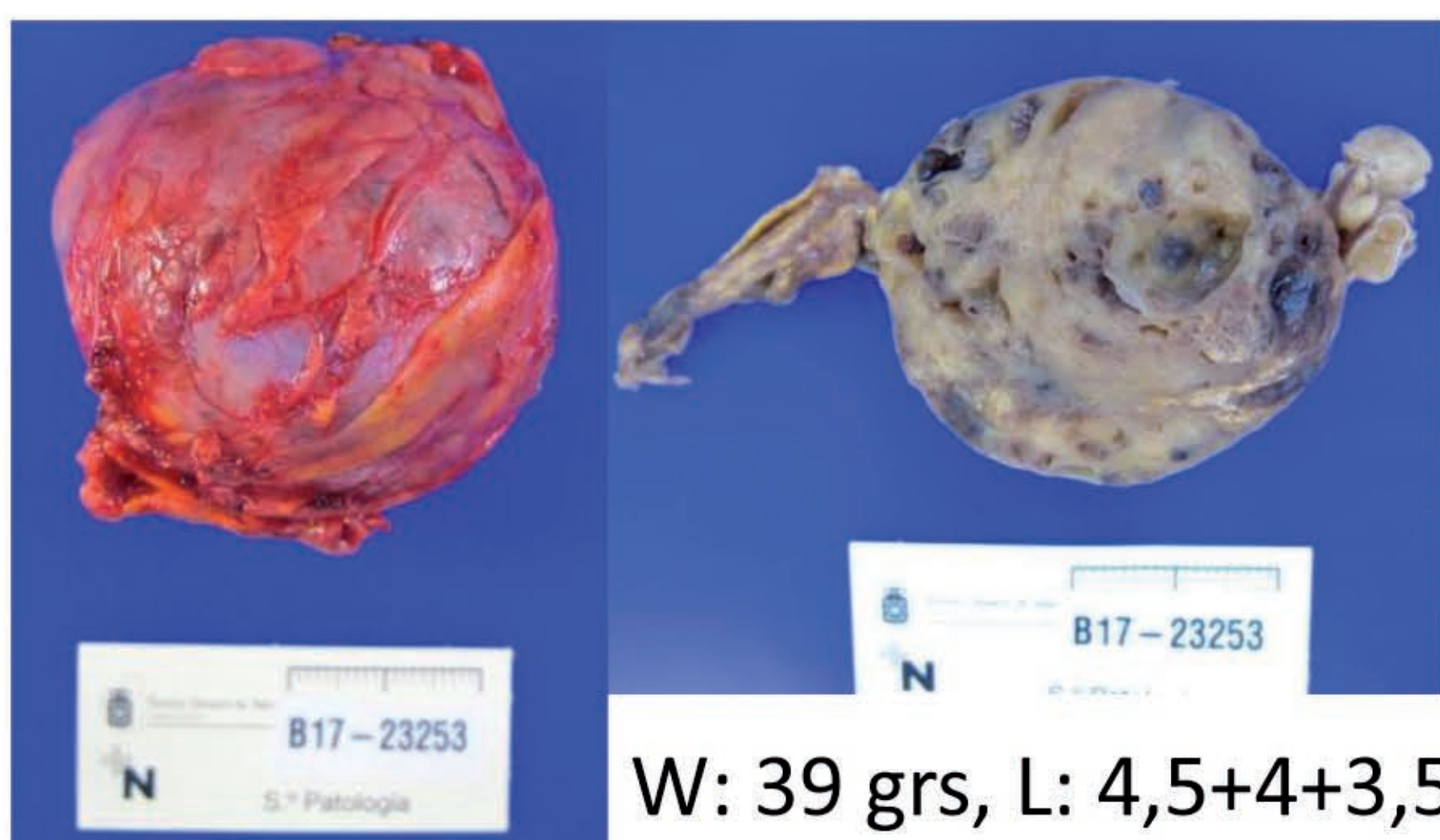
MRI



CT

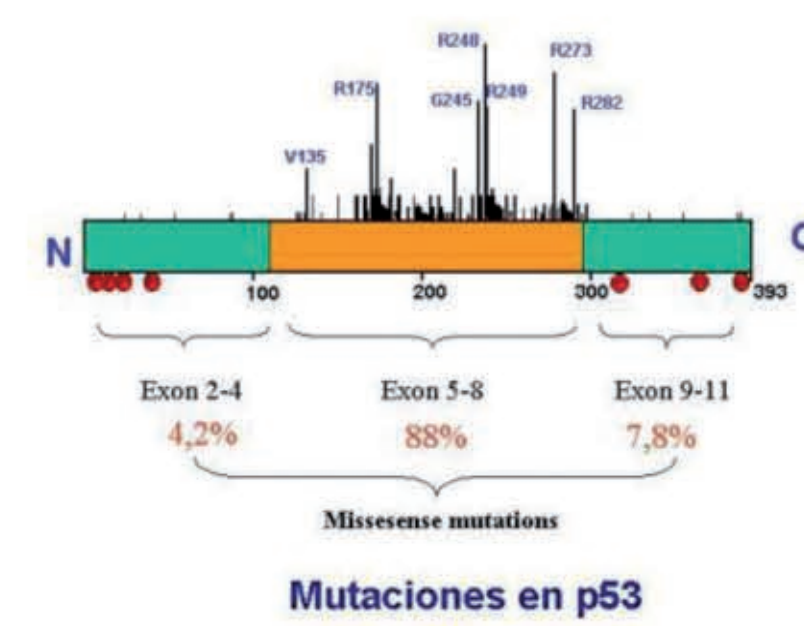
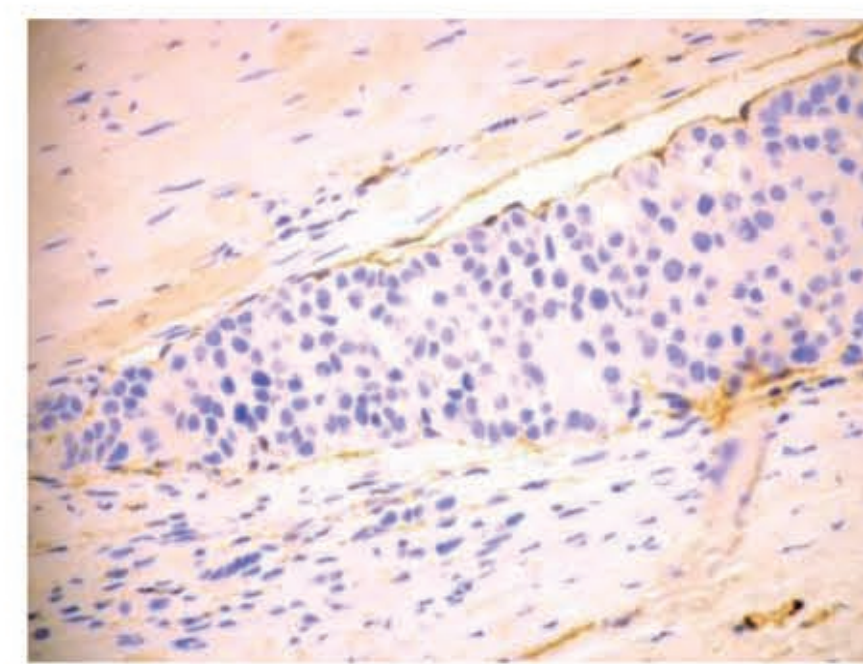


She was **diagnosed** of cortisol producing adrenal tumour, and surgery was performed with no incidences.

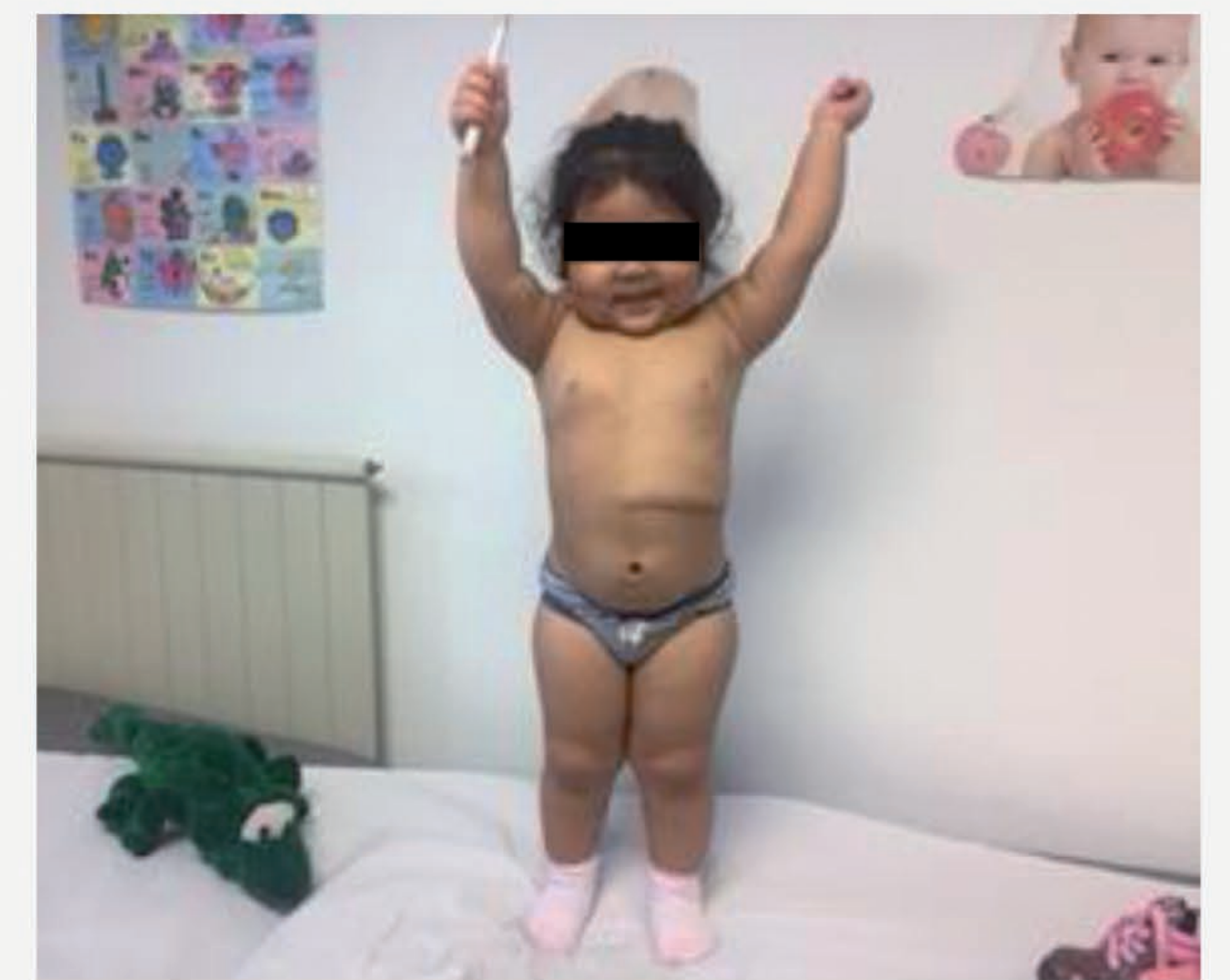

W: 39 grs, L: 4,5+4+3,5

The **histological study** confirmed that it was a benign adrenocortical tumour (Score Wieneke). Extension studies were negative (thoracic TC, bone scintigraphy).



At present, she has had a satisfactory evolution, with normal cortisol levels under substitutive treatment with hydrocortisone.



Genetic study was also negative (TP53, APC, CDKN1C, MEN1, NF1, RET, SDHB, SDHC, SDHD, VHL genes).

CONCLUSIONS

- An appropriate interpretation of the cortisol levels, based on age, with the clinical manifestations is required.
- Alteration of the cortisol circadian cycles with suppressed ACTH levels and the loss of suppression of cortisol with the dexamethasone test, guide to the diagnosis of cortisol producing adrenal tumour.
- An early diagnosis is crucial to prevent the morbidity of the Cushing syndrome.