

Mariella Valenzise, Laura Cannavò, Giuseppina Zirilli, Graziella Iaria¹, Mario Lima², Filippo De Luca

Department of Human Pathology of Adulthood and Childhood, University of Messina, Messina, Italy

¹Grande Ospedale Metropolitano, Reggio Calabria, Italy

²Department of Medical and Surgical Science, University of Bologna, Bologna, Italy

P3-P019

Disclosure statement: nothing to disclosure

BACKGROUND

Erythrocytosis is characterized by increased number of red blood cells. Primary form is also known as polycythemia vera, while secondary forms can be due to several causes, among which hyperandrogenism. Although the association of severe hyperandrogenism and polyglobulia is known, literature data concerning this comorbidity are overall scanty, and completely lacking in pediatric age.

CASE REPORT

We report the history of a 14 years-old girl admitted to our Pediatric Unit due to both polyglobulia (Hb 18.1 gr%) and virilization, as a consequence of a testosterone-secreting adrenal cancer.

In this girl increased Hb levels were incidentally demonstrated for the first time when she was 13 years-old, but no specific investigations were performed until a clinical picture of hyperandrogenism became evident (severe hirsutism, clitoromegaly and deepening of the voice). Biochemical evaluation showed a very severe increase of total testosterone, dehydroepiandrosterone-sulfate and delta-4 androstenedione with normal cortisol levels. Ultrasonography and computerized tomography showed a wide solid lesion (14 x 11 cm) in the right adrenal gland. On the basis of the severe virilization and the imaging features, a unilateral adrenalectomy was performed. The adrenal mass measured 14 cm and was 500 g of weight. Histology was compatible with an adrenal cortical carcinoma. Both hematological abnormalities and hyperandrogenism rapidly regressed after tumor removal. CT total body did not show remnant lesions, and for this reason no adjuvant therapy was performed.

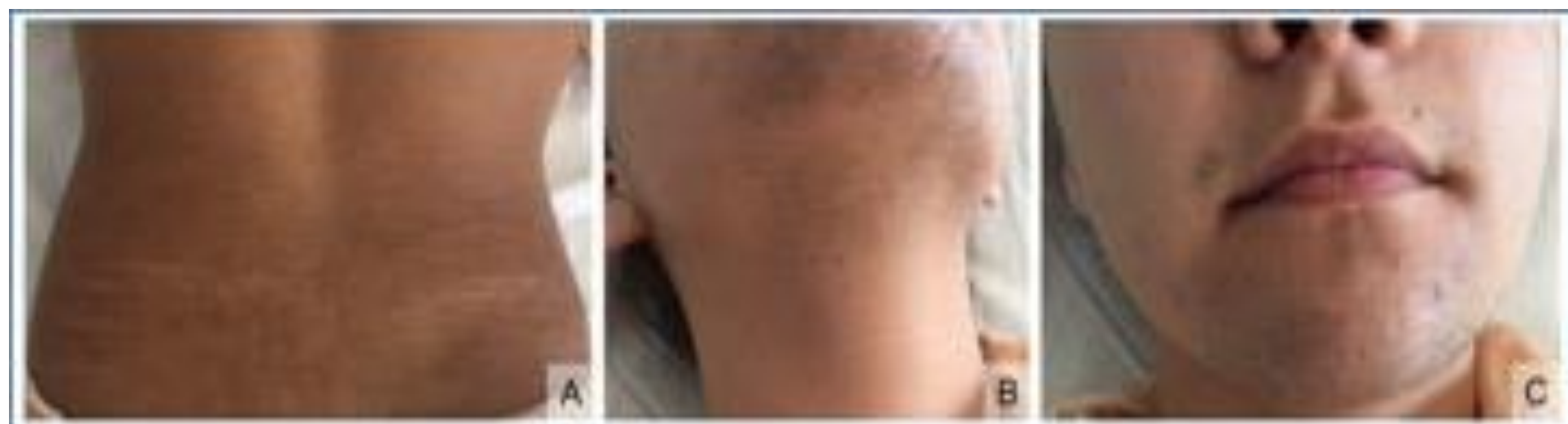

Figure 1. Virilization of face, neck and lumbar area in the 14 years old girl.

Hormone	Basal	Two months after adrenalectomy	Six months after adrenalectomy	Normal range
Total Testosterone (ng/dl)	268.2	45.9	29.1	5.0-75.0
DHEAS (mcg/dl)	1874.0	160	191.8	18-391
OH-Pg (ng/ml)	6.4	1.0	1.4	< 2.9
Androstenedione (ng/ml)	21.0	1.9	1.5	<2.83
Cortisol (mcg/dl)	8.0	8.85	8.41	6.7 – 22.6
UFC (mcg/24h)	124.8	168.56	139.70	58 - 403
ACTH (pg/mL)		13.4	6.95	0.0 – 50.0

Table 1. Hormonal profile of the patient, evaluated before and two and six months after adrenalectomy. DHEAS: dehydroepiandrosterone-sulfate. OH-Pg: 17OH-progesterone. Androstenedione: delta-4 androstenedione. UFC: urinary free cortisol. ACTH: adrenocorticotropic.

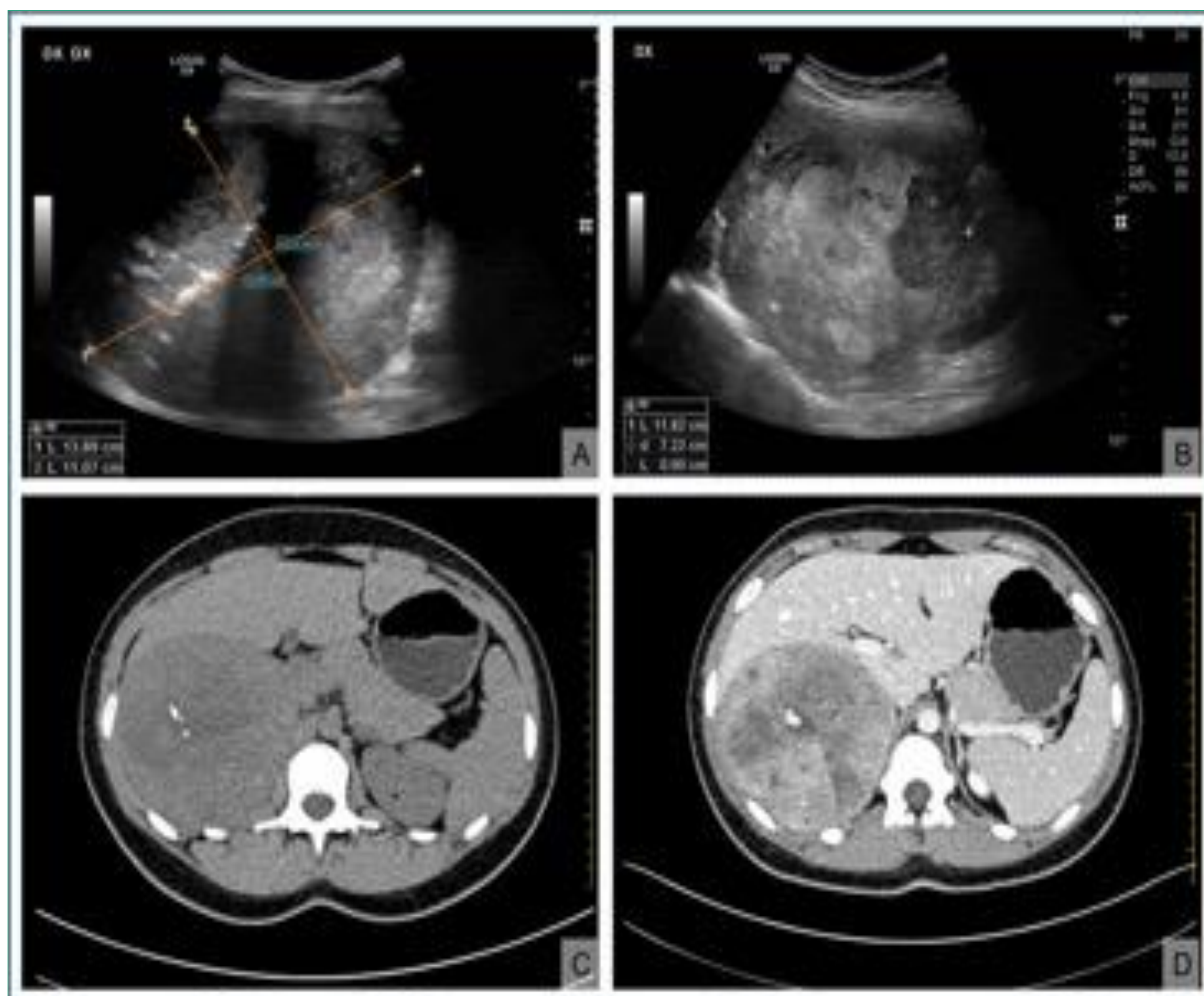


Figure 2. Ultrasound images (A-B) and CT scan (C-D) of the tumor mass in the right adrenal gland.

CONCLUSIONS

Hyperandrogenism due to adrenal tumors is a very rare cause of secondary erythrocytosis, especially in children. For this reason, the diagnosis can be challenging and delayed. The physicians should consider this etiology in the diagnostic work-up of erythrocytosis, in order to obtain a correct diagnosis and a rapid normalization of clinical picture.