

Identification of X-linked Adrenoleukodystrophy in Boys Presenting with Adrenal Insufficiency in the Absence of Adrenal Antibodies

MR Ryalls¹, H-W Gan^{2,3}, J Biedenkapp⁴, JE Davison⁵

¹Paediatric Department, Royal Surrey County Hospital NHS Foundation Trust, Guildford, UK; ²Paediatric Endocrinology & Diabetes, Great Ormond Street Hospital for Children NHS Foundation Trust, London, UK; ³UCL Great Ormond Street Institute of Child Health, London, UK; ⁴bluebird bio, Inc., Cambridge, MA, USA; ⁵Metabolic Medicine, Great Ormond Street Hospital for Children NHS Foundation Trust, London UK

INTRODUCTION

Adrenoleukodystrophy (ALD) is an X-linked, metabolic disorder caused by mutations in the *ABCD1* gene that result in deficiency of peroxisomal membrane ALD protein and accumulation of very long chain fatty acids (VLCFA) in plasma and tissue, primarily in the adrenal cortex and central nervous system.

- Approximately 35-40% of boys with ALD develop cerebral ALD (CALD), resulting in rapidly progressive cerebral demyelination, loss of neurologic function, and death. Disease progression can be stabilized by allogeneic hematopoietic stem cell transplantation (HSCT) if performed early in the course of cerebral disease. Radiologic diagnosis of CALD in presymptomatic boys is critical to ensure early treatment and favourable long-term outcomes.
- Mutations in the *ABCD1* gene are associated with genetic forms of primary adrenal insufficiency (PAI), therefore, PAI in boys in the absence of adrenal antibodies (21-OH antibodies) can be an early red flag for a potential ALD diagnosis.
- PAI may be the only clinical manifestation before onset of cerebral disease in CALD.

OBJECTIVES

1. Describe the clinical course of a boy diagnosed with ALD after presentation with antibody negative PAI, and who upon progression to CALD, received timely, successful allogeneic HSCT.
2. Assess reflex VLCFA testing in cases of negative adrenal antibodies in boys with PAI via a pilot educational program in major laboratories in the US, UK, and Italy conducting 21-OH antibodies and VLCFA tests.

1. CASE HISTORY

11.5 year old boy with CALD

Term birth; non-consanguineous parents	Age (yr)	No antenatal or perinatal concerns
• Episodes of vomiting, febrile convulsions with hypoglycaemia and ketonuria • Plasma cortisol levels 221-470 nmol/L	0	• Idiopathic ketotic hypoglycaemia • Normal insulin suppression, ketone body mobilization on prolonged fasting test
• Vomiting episode with hypoglycaemia • Plasma cortisol 550 nmol/L	2-2.5	• Synacthen tests: cortisol 178-163 nmol/L, ACTH 1106 ng/L • 21-OH antibody negative • Hydrocortisone replacement 10.3mg/m ² /d
	5.2-5.5	
	7-7.5	

VLCFA testing (Table 1) consistent with abnormal peroxisomal function suggestive of ALD

- Pathogenic hemizygous mutation (c.1849C>T, [p.Arg617Cys]) of *ABCD1* gene
- Lorenzo's oil*/low fat diet initiated *oleic acid and erucic acid 4:1 = 20% of dietary energy

Baseline MRI brain scan identifies features consistent with CALD (Figure 1)

- Neurological exam normal and no significant behavioural or psychological issues
- Repeat MRI after 3 months shows progression (Figure 1)

8	11.5yr
<p>HLA-matched unrelated allogeneic HSCT</p> <ul style="list-style-type: none"> • Pretransplant conditioning: alemtuzumab 0.2mg/kg x 5 doses, fludarabine 40mg/m² x 4 doses, busulfan 1.9mg/kg to target cumulative AUC 80mg/l/hr • No significant peritransplant complications, 100% engraftment in the myeloid lineage <p>Performing well in mainstream school 25th percentile for weight/50th for height Under assessment for delayed puberty Hydrocortisone replacement ongoing Moderately brisk reflexes in lower limbs, normal tone and power, no gait disturbance</p>	<p>Post-transplant MRIs show initial progression at one year, with subsequent stabilisation and no further progression through 3 years of follow-up (Figure 1)</p>

Table 1. VLCFA ANALYSES

Parameter (µmol/L)	Test 1	Test 2	Outcome	Reference
C22	43.3	47.6	Normal	(33.2 - 96.3)
C24	63.0	68.3	Normal	(25.2 - 71.4)
C26	3.32	3.72	↑ ↑ ↑	(0.23 - 1.79)
C24/C22 ratio	1.45	1.43	↑	(0 - 1.01)
C26/C22 ratio	0.077	0.078	↑ ↑	(0 - 0.026)
Phytanate	2.89	6.11	Normal	(0 - 15.00)
Pristanate	0.24	0.55	Normal	(0 - 2.00)

VLCFA testing assesses hexacosanoic acid (C26:0), tetracosanoic acid (C24:0), docosanoic acid (C22:0) levels and the ratios C26:0/C22:0 and C24:0/C22:0. Pristanic and phytanic acids (branched chain fatty acids that undergo oxidation in peroxisomes), are typically elevated in peroxisome biogenesis disorders in the Zellweger spectrum, but not in ALD.

VLCFA analysis obtained at 7 years of age and confirmed at 7.5 years of age showed elevated C26 fatty acids with moderately raised C26/C22 ratio, mildly raised C24/C22 ratio, and normal phytanate and pristanate.

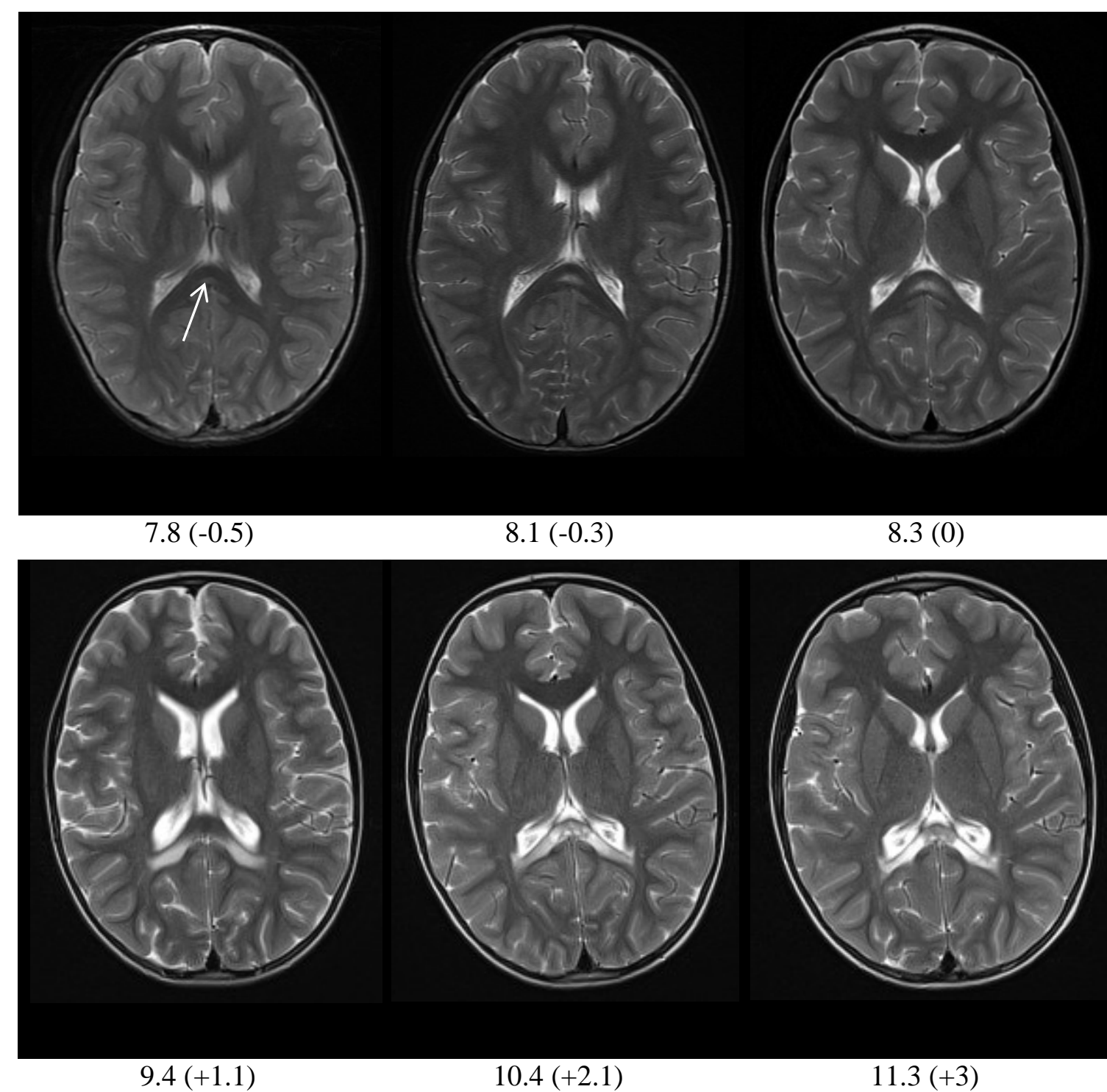
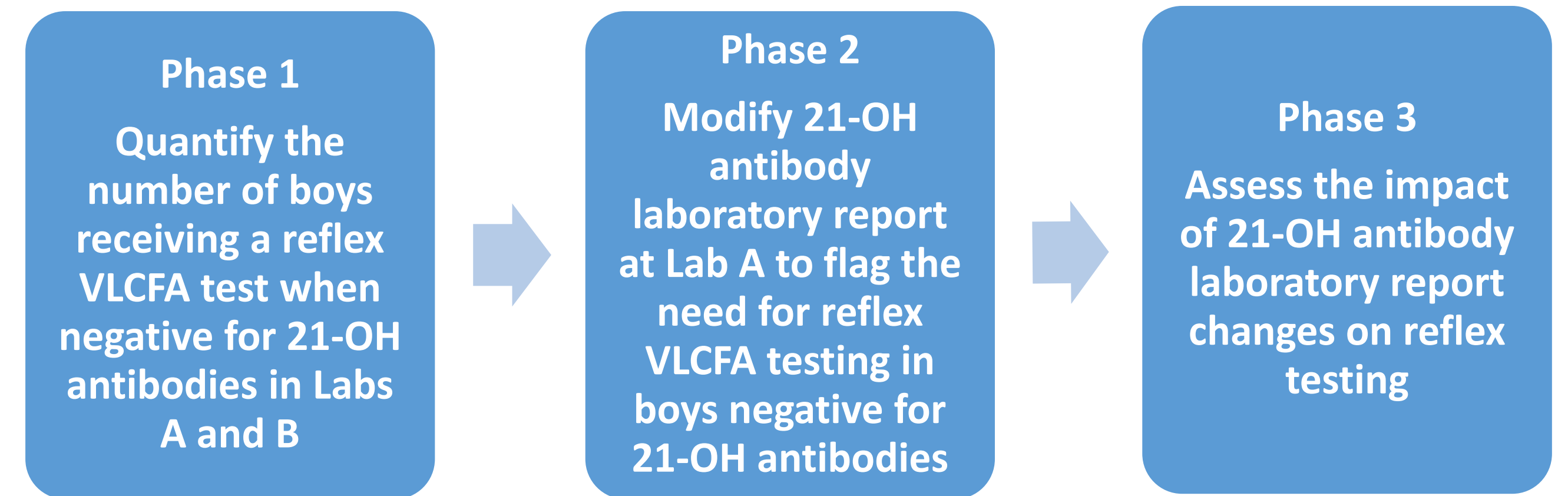


Figure 1: BRAIN MAGNETIC RESONANCE IMAGING

T2-weighted axial images. Top row: pre-transplant, bottom row post-transplant. Interval of scan in years (years before [-] or after [+] transplant). Arrow indicates increased signal lesion in splenium of corpus callosum that progressively enlarged pre-transplant, further progressed at 1.1 year post-transplant, but subsequently stabilized.

2. PILOT EDUCATIONAL PROGRAM

Initiated to encourage reflex VLCFA testing in boys being evaluated for adrenal insufficiency who test negative for 21-OH antibodies. Conducted in three phases at centers in the UK, US, and Italy:



Modifications made to Lab A:

- Emailed clients who requested either 21-OH antibody or VLCFA test
- Altered consult documents for 21-OH antibody testing on website
- Altered consult documents for VLCFA testing on website
- Made additional comment on 21-OH antibody report to emphasize need for VLCFA testing when 21-OH antibody test is normal

RESULTS

UK: Assessment at 3 centers of 2000 samples showed that VLCFA testing was performed in parallel with 21-OH antibody testing in young boys.

US: Parallel or reflex VLCFA testing low at two centers. Rate did not significantly change with modification of lab report at Lab A; modest increase in the number of VLCFA tests performed.

Italy: No reflex or parallel VLCFA testing performed prior to or after lab report modification.

		21-OH antibody test in boys < 10 yr		Parallel or reflex VLCFA testing *
		# Samples	Results	# (%)
US Lab A	Phase 1 2016	69	Normal 60	3 (5%)
	Phase 2 2017	62	Normal 54	8 (15%)
US Lab B	Phase 1 2016	129	Normal 122	3 (2%)
	Phase 1 2017	127	Normal 91	6 (7%)
Italy Lab A	Phase 1 2016	4	Normal 3	0
	Phase 2 2017	4	Normal 4	0

* VLCFA testing at different laboratories not captured

SUMMARY and CONCLUSIONS

- Recognition of PAI without adrenal antibodies or other clinical symptoms in a 7 year old boy prompted VLCFA analysis that identified the underlying ALD diagnosis.
 - MRI surveillance detected early, pre-symptomatic cerebral disease and permitted a timely bone marrow transplant which successfully arrested cerebral disease progression.
- Results of an educational program in the US and Italy show that modifying information on 21-OH antibody reports with the need for reflex testing did not change the low levels of parallel or reflex VLCFA testing performed. This could be because:
 - Endocrinologists may refer patients to a neurologist that uses a different VLCFA testing lab
 - Endocrinologists are not acting on the new recommendations in the lab report
 - VLCFA testing may occur in laboratories different from those that conducted the 21-OH antibody test
- The need for early CALD diagnosis in order to initiate timely treatment mandates awareness of the need to screen boys with unexplained PAI with a VLCFA panel. Newborn screening for ALD remains limited, therefore the potential for delayed diagnosis of CALD persists.
- There is continued need for education that PAI in the absence of adrenal antibodies is a red flag for a potential ALD diagnosis.

REFERENCES

Information on CALD:

- Engelen M, Kemp S, de Visser M, et al. X-linked adrenoleukodystrophy (X-ALD): clinical presentation and guidelines for diagnosis, follow-up and management. *Orphanet J Rare Dis.* 2012;7:51.
- Miller WP, Rothman SM, Nascene D, et al. Outcomes after allogeneic hematopoietic cell transplantation for childhood cerebral adrenoleukodystrophy: the largest single-institution cohort report. *Blood.* 2011;118(7):1971-8.

Information on PAI in CALD:

- Brett EM, Auchus RJ. Genetic forms of adrenal insufficiency. *Endocr Pract.* 2015;21(4):395-9.
- Dubey P, Raymond GV, Moser AB, et al. Adrenal insufficiency in asymptomatic adrenoleukodystrophy patients identified by very long-chain fatty acid screening. *J Ped.* 2005;146(4):528-32.
- Polgreen LE, Chahla S, Miller W, et al. Early diagnosis of cerebral X-linked adrenoleukodystrophy in boys with Addison's disease improves survival and neurological outcomes. *Eur J Pediatr.* 2011;170(8):1049-54.
- Ronghe MD, Barton J, Jardine PE, et al. The importance of testing for adrenoleukodystrophy in males with idiopathic Addison's disease. *Arch Dis Child.* 2002; 86:185-189.

DISCLOSURES

JB is an employee of bluebird bio, Inc., who provided editorial support for this poster. MRR, HWG and JED report no conflicts of interest.