

# Congenital adrenal hyperplasia due to a rare homozygous mutation R483P in the *CYP21A2* gene and coexisting growth hormone deficiency

<sup>1</sup>Akulevich N, <sup>1</sup>Makarava Yu, <sup>2</sup>Boiko G, <sup>3</sup>Mirabelli S,  
<sup>3</sup>DeLuca F, <sup>3</sup>Wasniewska M

<sup>1</sup>State Center for Medical Rehabilitation, Minsk, Belarus;  
<sup>2</sup>Kaliningrade Children Hospital, Russian Federation; <sup>3</sup> Messina University, Italy

## Background and Objective

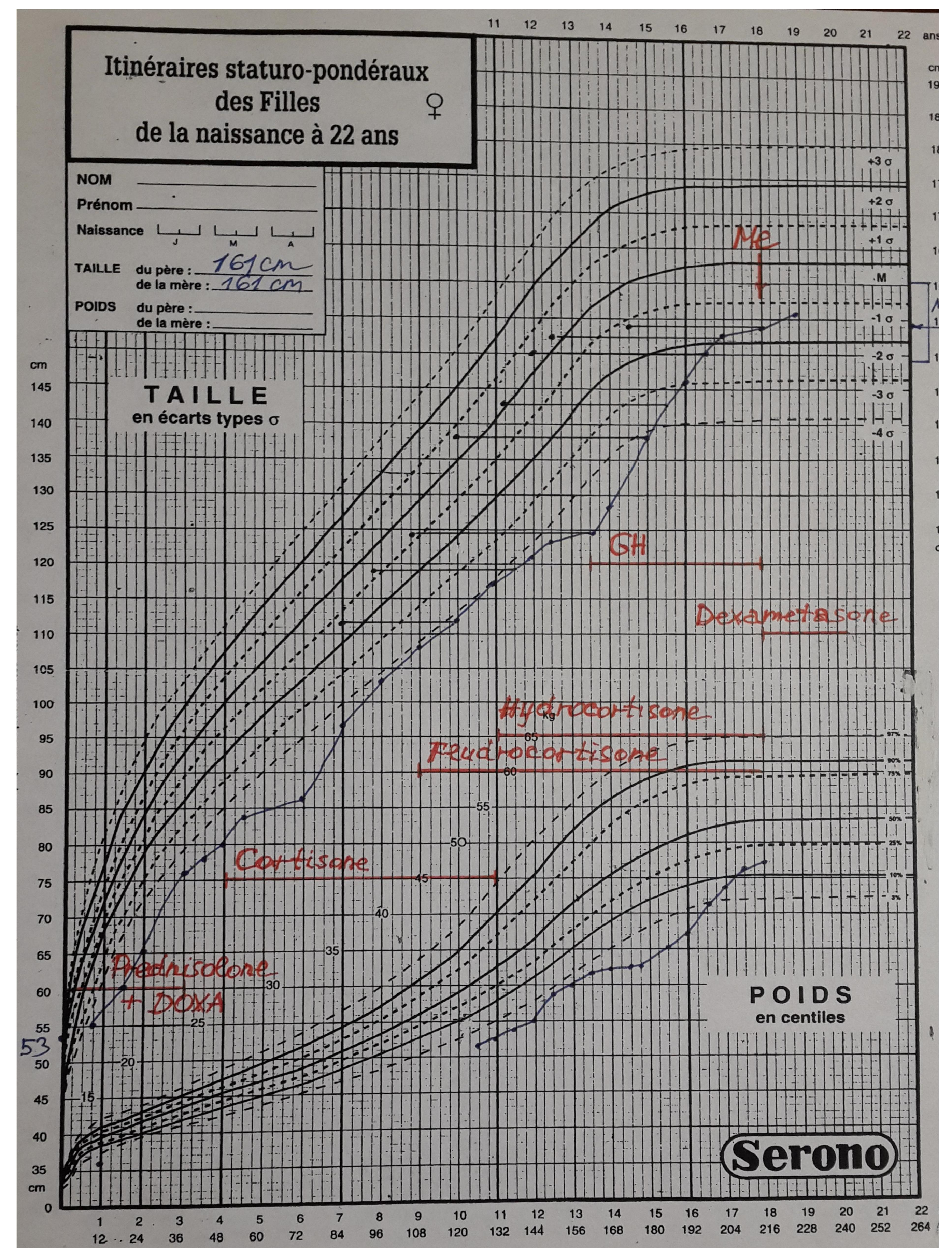
In CAH due to 21-OH deficiency, GH treatment combined to GC and MC replacement is still considered to be experimental.

## Methods

We present a patient who has benefited from such treatment.

## Results

A baby girl was born in term with **clitoromegaly and manifested with salt loose at neonatal period**. Low serum morning cortisol and sodium with high potassium and 17-OH levels were found resulted in the clinical diagnosis of CAH. The karyotype was 46,XX. **Prednisolone and DOXA**, the only available hormone replacement therapy in the country, was initiated with patient condition's improvement. Later, the therapy was switched to **hydrocortisone** 12 mg/m<sup>2</sup>/day divided in 3 times, combined to small daily fludrocortisones dose, as 0,025-0,050 mg. However, the girl height was -4SDS and MPH was -1SDS. The bone age was 4 y. delayed, while the girl was euthyroid. Two GH stimulation tests performed demonstrated GH deficiency. Pituitary MRI was normal. After Institution Review Board approval, **GH therapy was started at the age of 13,5 y. and completed when she was 18 y.e.** after bone plate fusion. In 4,5 y. of GH treatment she has got 32 cm (3SDS) in height. Her final adult height is 157 cm. Puberty was delayed, clitorovaginoplasty was performed at the teen age, **menarche started at 18y.** Due to menstrual irregularities, hydrocortisone was switched to **dexamethasone** 0,375mg daily, with regular cycle and no adverse metabolic effects. Finally, genetic diagnosis of CAH was done due to **homozygous point mutation R483P in the *CYP21A2* gene.**



## Conclusion

The story of our patient presents an example of the association of CAH with GH deficiency which mimics the typical clinical course of main disease. This particular case emphasizes that treatment with prednisolone at early age may worsen final patient's height; however, the patient may benefit from combined GC, mineralocorticoid and GH treatment.

According to our knowledge, this is the first case of the R483P homozygous mutation in the *CYP21A2* gene described in patient with salt-wasting CAH.

The authors have nothing to disclose

Correspondence for Dr. Natallia Akulevich: [natamedical@mail.ru](mailto:natamedical@mail.ru)

### References

1. Speiser PW. et.al 2010 J Clin Endocrinol Metab.
2. Han TS. et al. 2013 Clinical Endocrinology.

