

# Hypercalcaemia after treatment with Denosumab: bisphosphonates as option for therapy and/or prevention?

Heinrich Schmidt, Claudia Weißenbacher, Julia Roeb, Susanne Bechtold-Dalla Pozza, Hans-Jürgen Dürr, Carmen Sydlík

**Conclusion:** Although denosumab is not yet licensed in children and adolescence, it is used more often as it shows good effects not only in aneurysmatic bone cysts but also several other osteolytic diseases. However, severe hypercalcaemia after the ending the treatment seems to be rather frequent, due to the generally higher bone turnover in growing children. So it is mandatory to think about strategies of treatment and even more, prevention. From our experience, bisphosphonates could be an option for both. To find out the right timing and dose regimens for preventive use studies are needed.

**Background / Aims:** Pharmacologic options for treatment of osteolytic diseases especially in children are limited. Although not licensed for use, denosumab, a fully humanized antibody to RANKL, is used in children and shows good effects, e.g. in giant cell tumors and aneurysmatic bone cysts. However, there are reports of severe hypercalcemia after stop of denosumab, an adverse effect which is rarely seen in adults.

**Methods:** We report on four patients, aged 6 to 17 years, so far the largest group in literature, who developed severe hypercalcemia after the end of successful treatment with denosumab (dose regimen: 60 mg on day 1, 8, 15, 28, then every fourth week) for unresectable giant cell tumors of the bone and aneurysmal bone cysts. Treatment options for hypercalcemia and their effects are presented. Consequences for further patients will be discussed.

## Patient 1: 11 year old boy

- 10/2014: diagnosis of an aneurysmatic bone cyst in the left os sacrum
- no option for surgery because of localisation and extension
- 11/2014: start of off-label-use treatment with denosumab:
- 03/2016: stop of denosumab because of good ossification of the cyst
- 04/2016: hypercalcemia (max. 3,77 mmol/l) with dizziness, nausea, vomiting, abdominal and generalized pain
- intensified hyperhydration, furosemid and prednisolone with only transient effect
- bisphosphonate treatment: normalisation of calcium on the next day (2,21 mmol/l)
- 14 days later: recurrent symptomatic hypercalcemia (3,68 mmol/l)
- another dose of bisphosphonats: calcium of 2,33 mmol/l two days later
- follow-up for half a year: stable calcium levels

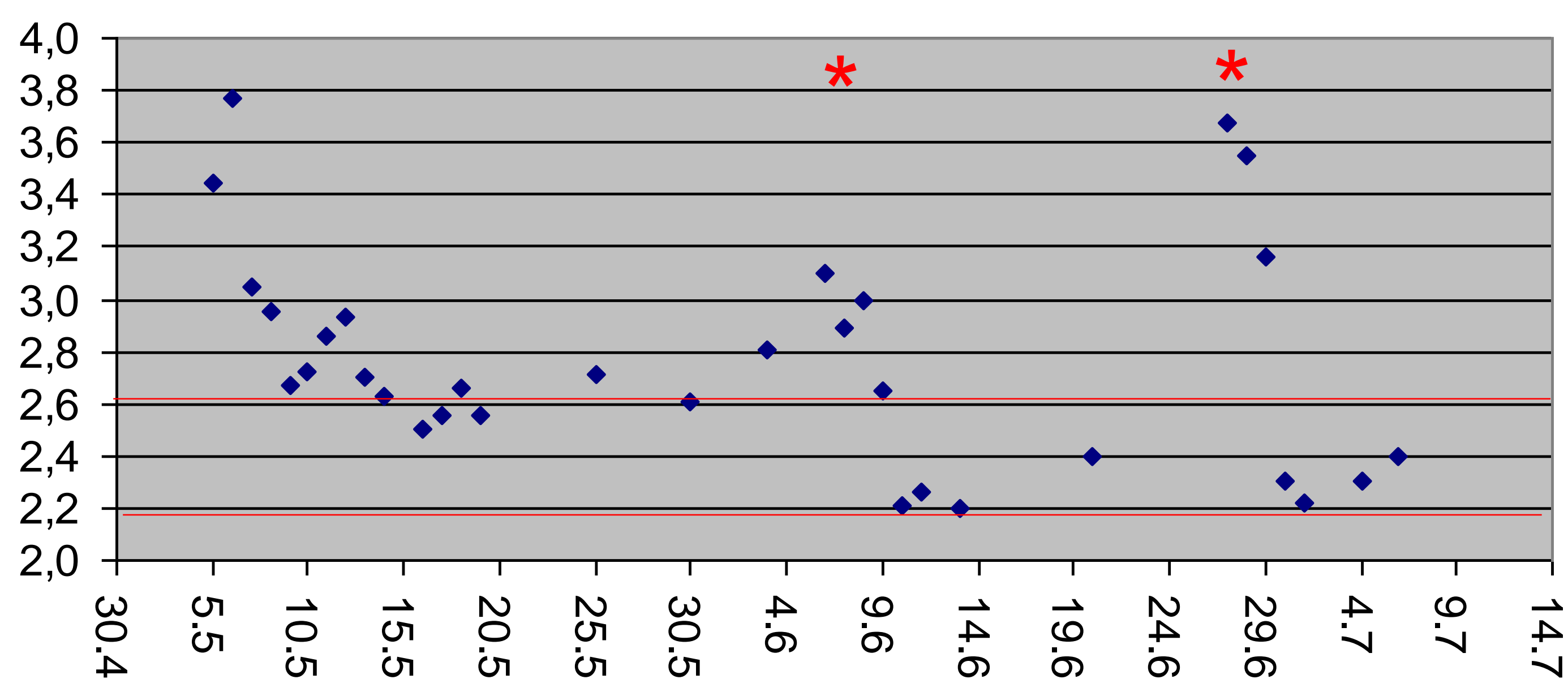


Fig. 1: Calcium-levels since start of hypercalcemia of Patient 1; red asterixes: dose of bisphosphonates; red lines: range of normal calcium levels

## Patient 2: 11 year old girl

- 10/2014: diagnosis of a giant cell tumor L5/S1
- 10/2014 – 12/2015: off-label treatment with denosumab
- 12/2015: resection of the tumor after shrinking by denosumab treatment;
- 02/2016: hypercalcemia (initial level: 3,93 mmol/l) with vomiting, nausea, abdominal pain and prerenal failure
- treatment with hyperhydration, furosemid (ineffective)
- high-dose prednisolone: normalisation of calcium levels
- 10/2016: presentation at our clinic with reduced, but ongoing prednisolone therapy, (0,25 mg/kg/d) and Cushing`s syndrome
- slow tapering of cortisone treatment until 12/2016: no recurrence of hypercalcemia but still symptoms of Cushing`s syndrome (elevated weight and arterial hypertension)

## Discussion:

Although rarely seen in adults, in children there seems to be a quite high risk for severely symptomatic hypercalcemia after stopping treatment with denosumab. It is supposed that the body`s mechanostat realizes the additional bone mass, gained by the blocked formation of osteoclasts, as too high, leading to a reactive hyperactivity of osteolysis after the end of the treatment and by this to hypercalcemia.

As use of denosumab in children increases, we think it is urgently needed to evolve effective strategies for treatment and, preferably, prevention of post-treatment hypercalcemia. As shown by patients 2 and 3, long-term corticosteroids and restarting denosumab cannot be recommended.

Instead, bisphosphonates could be an option for treatment as well as prevention by their long-lasting adherence to bone matrix and by this preventing bone resorption. Given after stop of denosumab, they could inhibit the activity of the reactively formed new osteoclasts. But, as seen in patient 4, the right time point and frequency of bisphosphonate doses would still have to be found out. Alternatively a pretreatment with bisphosphonates before the start of denosumab could be considered to achieve a stabilisation of the newly formed bone mass by the action of denosumab. A combination of both methods might also be worth a try.

## Patient 3: 6 years old boy

- 07/2011: diagnosis of an aneurysmatic bone cyst in the left thigh, inoperable due to high risk for extensive bleeding
- 07/2011 – 09/2012: off-label-use treatment with denosumab
- 10/2011: additional embolisation of the tumor vessels
- 12/2012: hypercalcemia (initial level: 4,14 mmol/l) with dizziness, vomiting, lacking appetite and tiredness, metabolic alkalosis
- restart with denosumab 30 mg every third month
- 09/2013 - 05/2016: 2 further episodes of hypercalcemia after each stop of denosumab, each time treated again with denosumab; then lost to follow up

## Patient 4: 13 year old boy

- 11/2012: diagnosis of a giant cell tumor in Th2 with osteodestruction of Th2 and compression of the spinal channel
- 12/2012 – 01/2014: off-label-use treatment with denosumab
- 01/2014: dorsal decompression, spondylodesis of Th1-3, partial cyst resection
- 08/2016: recurrent extension of the cyst: spondylodesis of C7 - Th4
- 09/2016 – 04/2017: treatment with denosumab for stabilisation; at the end precautonal treatment (patient 1 in mind !) with one dose of bisphosphonates
- 07/2017: symptomatic hypercalcemia (initial level > 4 mmol/l), including mild renal failure and elevated RR
- hyperhydration, furosemide and prednisolone without success
- bisphosphonate treatment: normalized calcium lwithin 2 days
- 14 days later: hypercalcemia (3,90 mmol/l) with identical symptoms
- another dose of bisphosphonates: normalisation of calcium, but soon rising again
- 10 days later: third dose of bisphosphonates: normalisation of calcium
- during follow up no recurrence of hypercalcemia

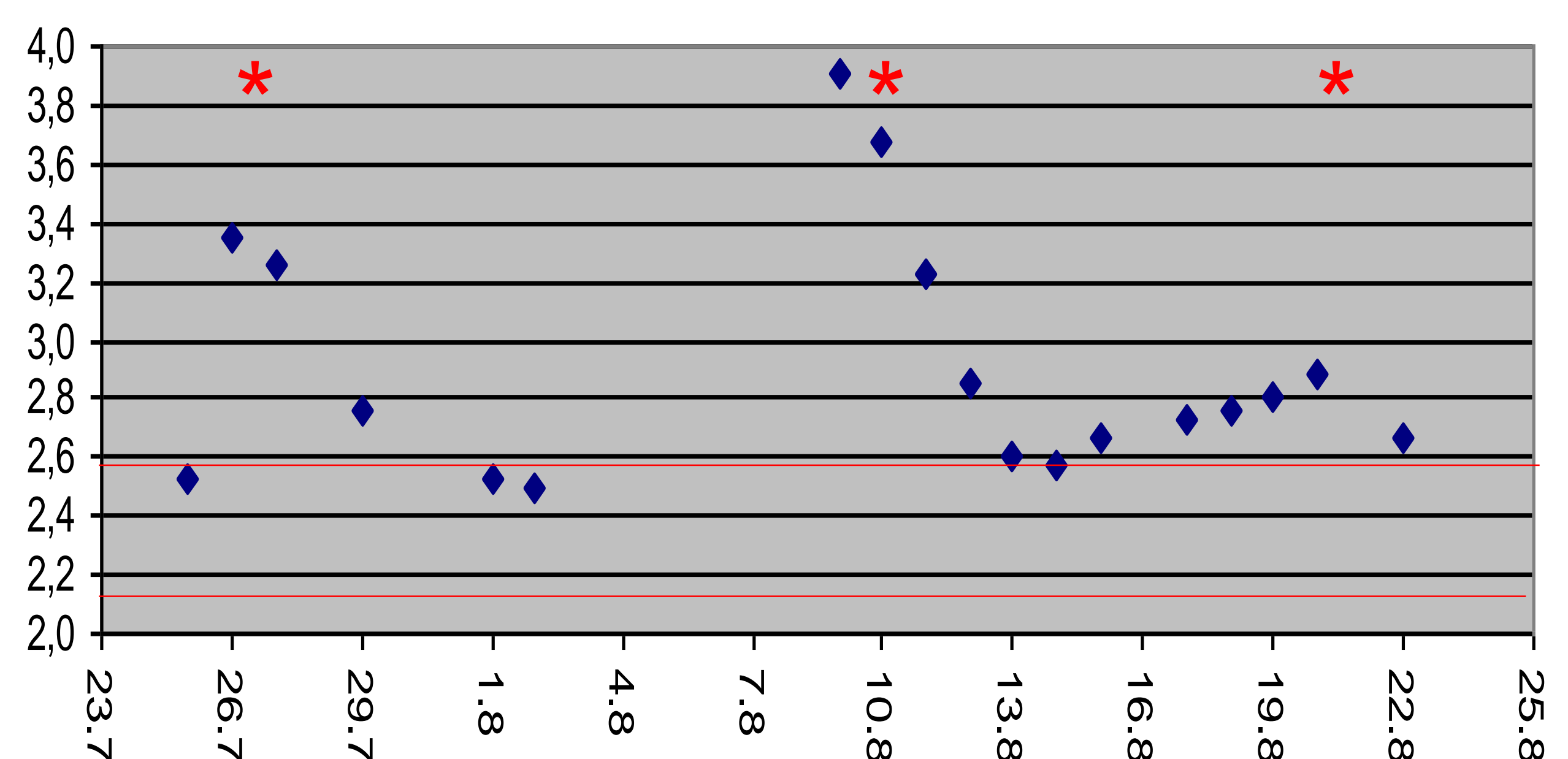


Fig. 2: Calcium-levels since start of hypercalcemia of Patient 4; red asterixes: dose of bisphosphonates; red lines: range of normal calcium levels