

Infantile Arterial Calcification and Subsequent Hypophosphatemia Due to ENPP1 mutation

A case followed through to adulthood

Munier A Nour¹, Mark Inman¹, Terra Arnason²

1) Division of Pediatric Endocrinology; Department of Pediatrics; University of Saskatchewan
2) Division of Endocrinology; Department of Medicine; University of Saskatchewan

Introduction

- Infantile Arterial Calcification (IAC) is a rare and frequently lethal condition.
- Children who survive the infantile period may develop fibroblast-growth-factor 23 (FGF23) mediated hypophosphatemia and rickets when IAC is due to mutations in the *ENPP1* gene.

Case Progression

- Term female was born with extensive calcifications noted *in utero* involving the coronary arteries and cardiac valves.
- Family history of previous sibling death at 4 months due to extensive vascular calcifications.
- Genetic testing as an adult confirmed compound heterozygous pathogenic mutations of *ENPP1* gene:
 - c.2191del, p.(Asn731Ilefs*5); and
 - c.583T>C, p.(Cys195Arg)
- Treated by 1 week of life with a first-generation bisphosphonate (Etidronate).
- Developed Rickets by 4 months of age.

Ca	2.7 mM	(2.2 – 2.8 mM)
PO ₄	1.10 mM	(1.25 – 2.1 mM)
ALP	2117 U/L	(150 – 450 U/L)
PTH	1.5 pM	(1.3 – 7.6 pM)
- Rickets initially attributed to Etidronate therapy leading to dose reduction then discontinuation at 2.5 yrs.
- Hypophosphatemia persisted

Ca	2.6 mM	(2.2 – 2.6 mM)
PO ₄	1.07 mM	(1.30 – 1.70 mM)
ALP	647 U/L	(150 – 300 U/L)
PTH	118 pM	(1.3 – 7.6 pM)
1,25(OH) ₂ VitD	70 pM	(40-140 pM)
TRP	23%	
- Phosphate & Rocaltrol initiated by 4yrs.
- During puberty, new calcifications developed with worsening renal artery stenosis, SMA/IMA/Celiac artery stenosis and Aortic valve calcifications. Hypophosphatemia therapy stopped. (See Figures 1 and 2)

Ca	2.35 mM	(2.1 – 2.6 mM)
PO ₄	0.59 mM	(0.87 – 1.45 mM)
ALP	142 U/L	(30 – 110 U/L)
PTH	8 pM	(1.3 – 6.8 pM)
1,25(OH) ₂ VitD	105 pM	(60-160 pM)
- Calcifications remained stable as an adult until the initiation of an oral contraceptive pill (OCP), with acute worsening of calcifications noted. Serum phosphate increased from ~0.4mM pre-OCP to 0.75mM.
- Recently, off-label therapy with Acetazolamide is being trialed to reduce systemic calcifications through renal excretion.

Radiographic Investigations

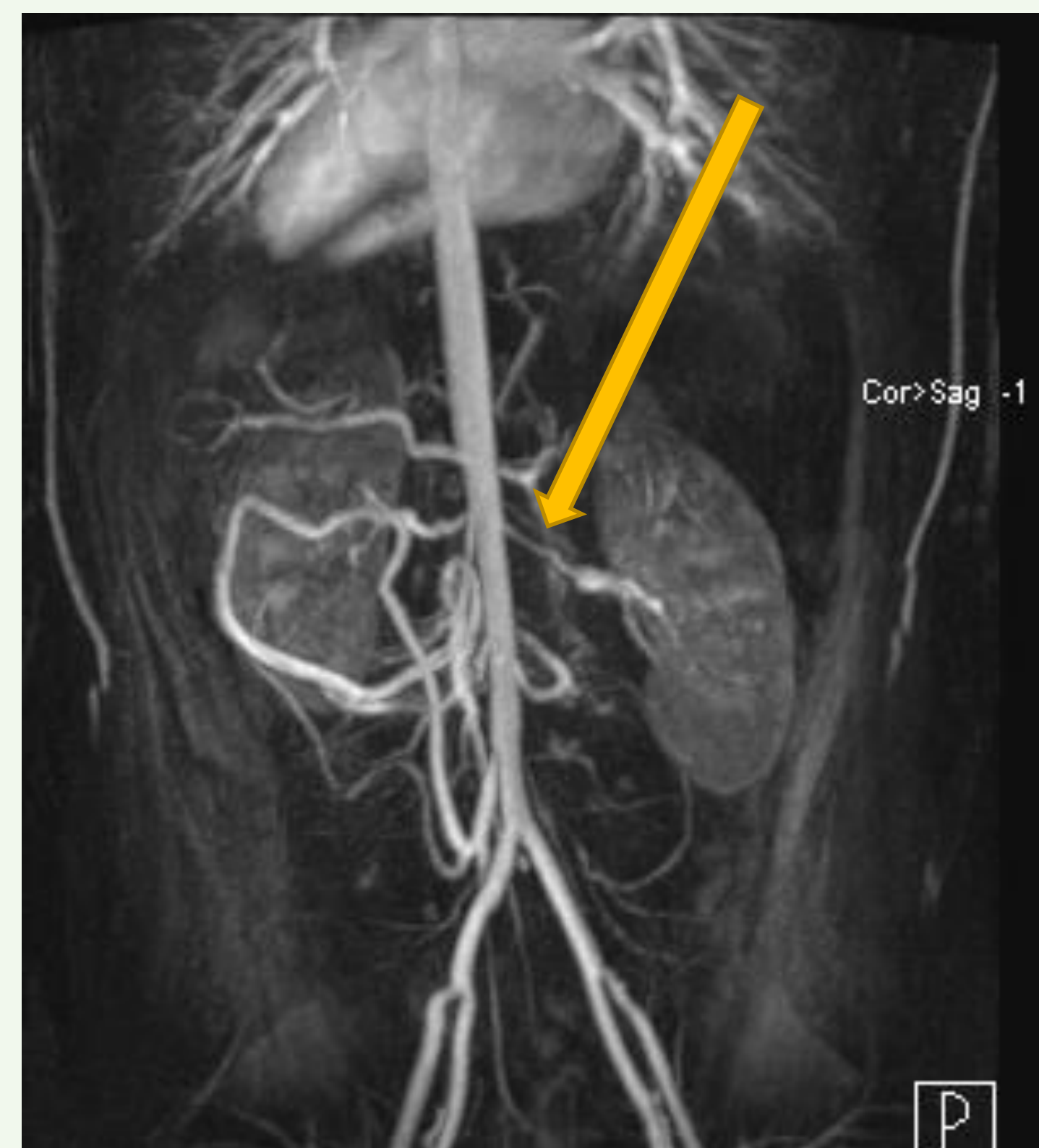


Figure 1. At 12 years old, CT Angiogram demonstrates severe stenosis of the origins of the major branches of the aorta including the celiac artery, SMA, renal arteries, and IMA.

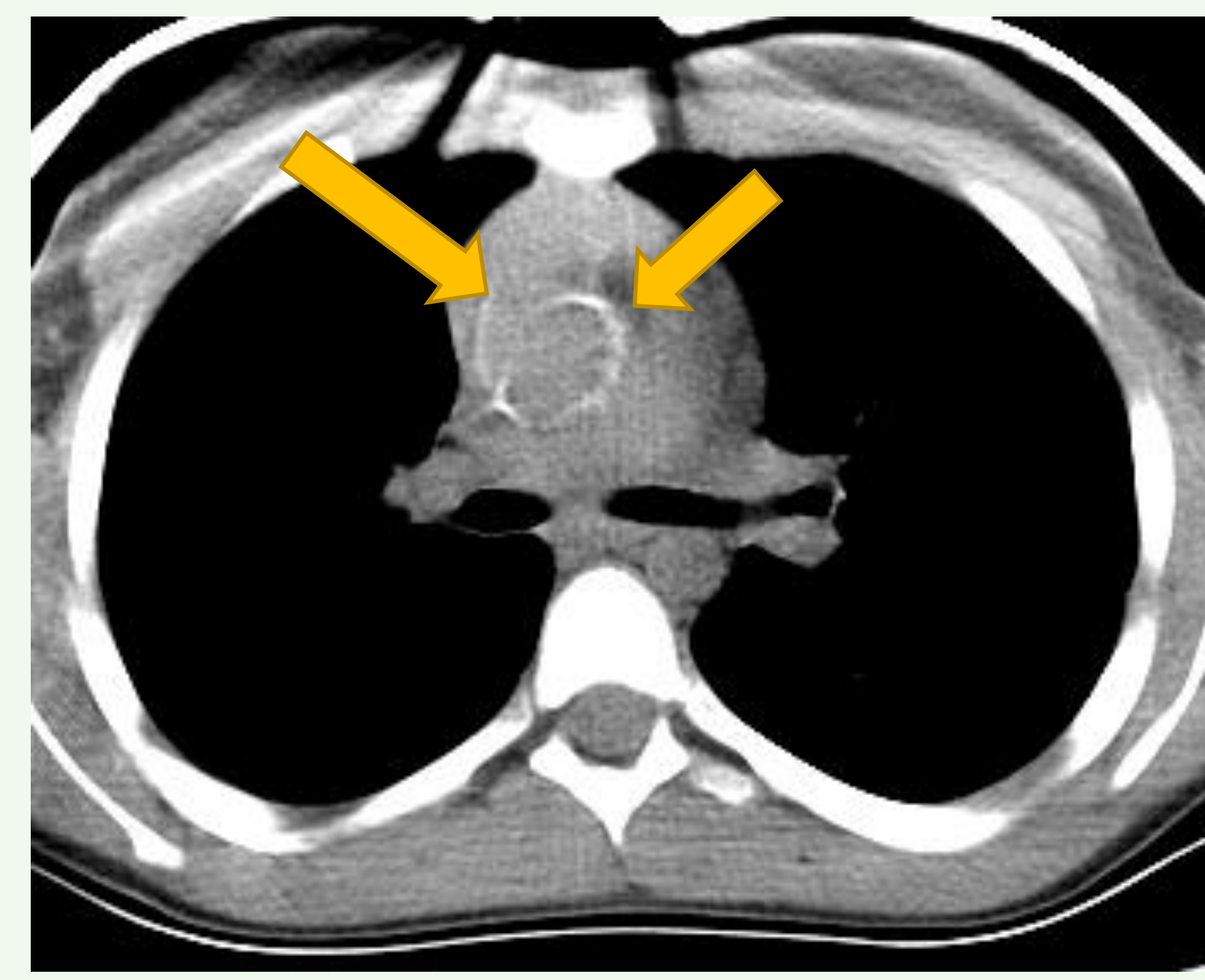


Figure 2. At 12 years, cardiac CT demonstrates significant intimal calcification of the aortic arch and coronary arteries.

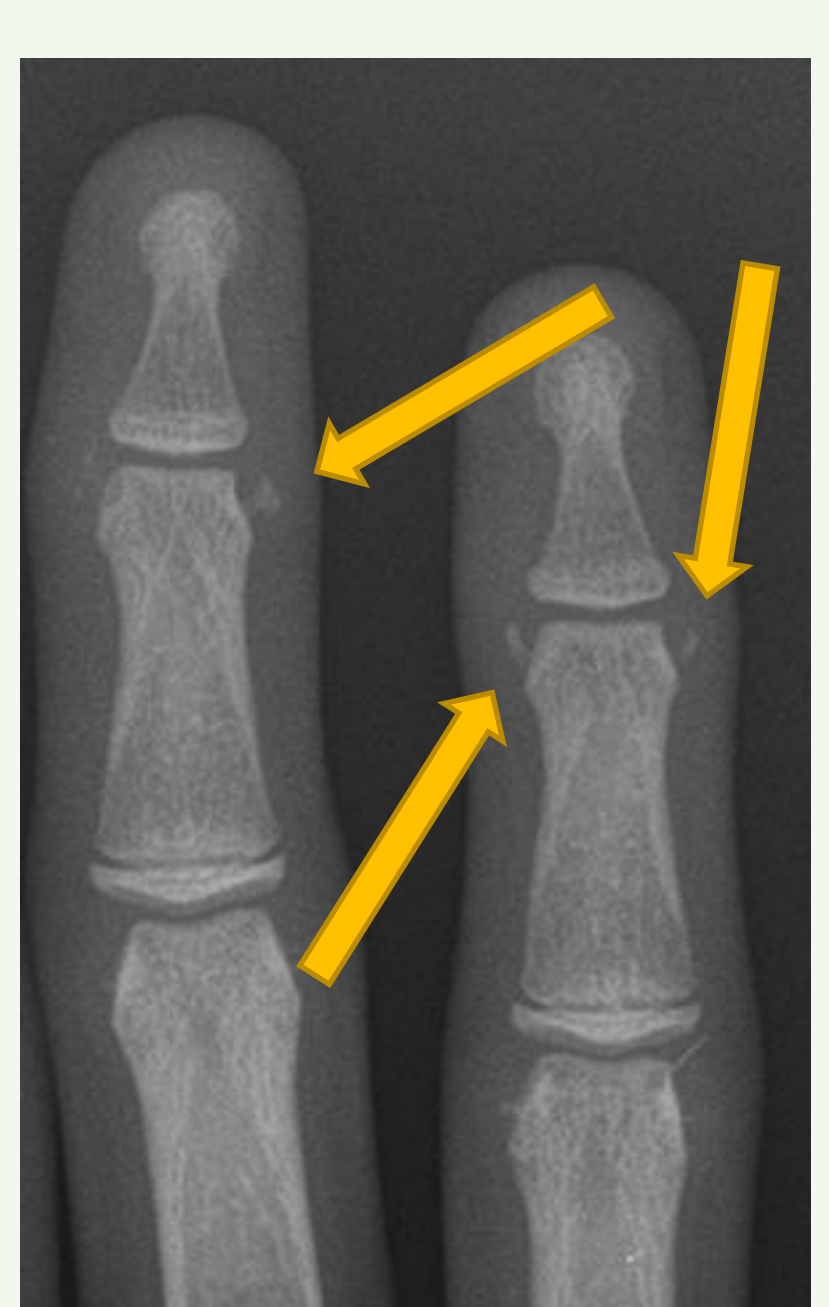


Figure 3. Painful calcifications of 3rd and 4th DIP developed following introduction of OCP at 18 years.

Discussion

- Patients with *ENPP1* mutations that survive infancy present a unique balance between bone hypomineralization that paradoxically coexists with extraskeletal calcifications.

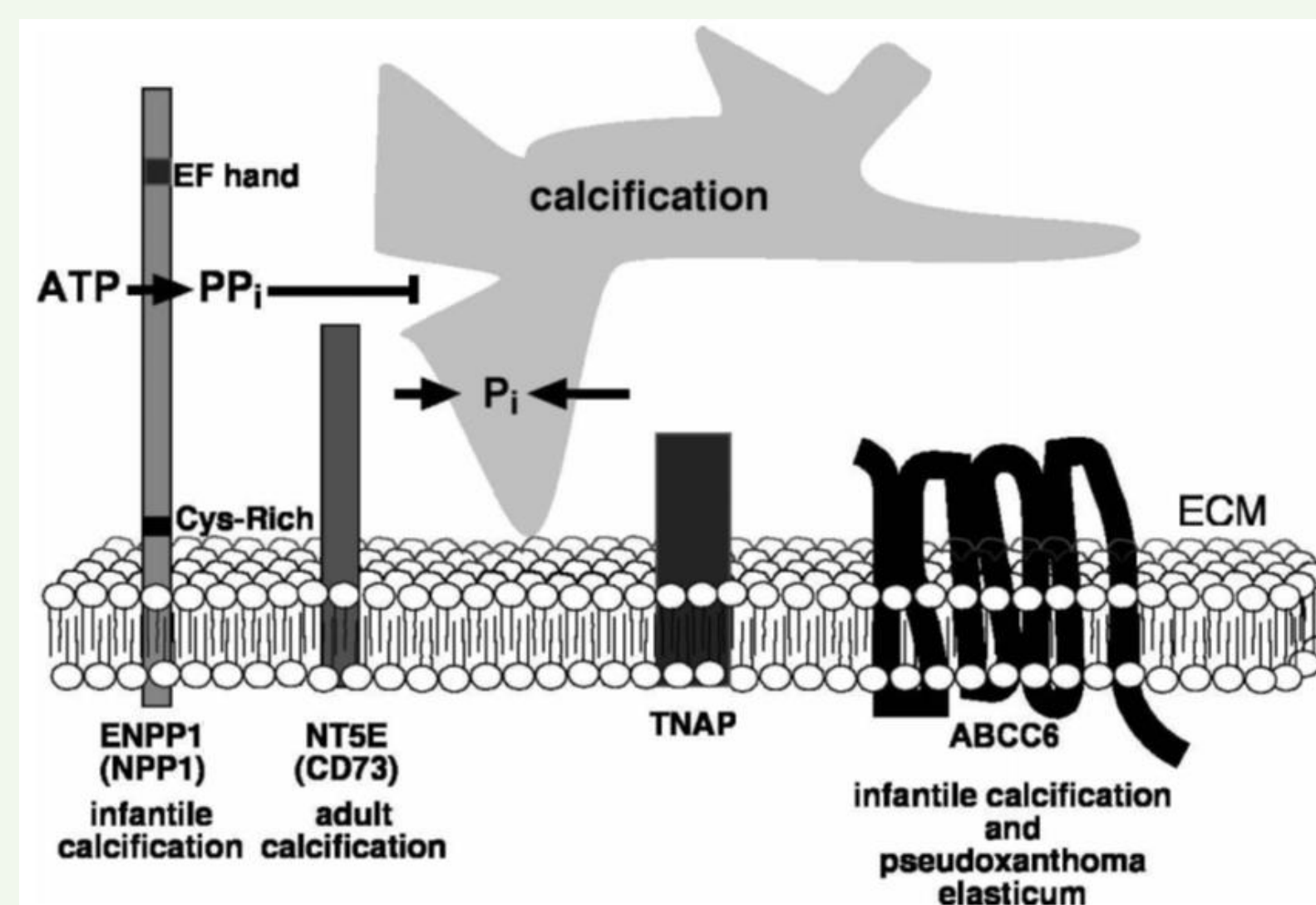


Figure 4. *ENPP1* encode the NPP1 protein, which hydrolyzes extracellular ATP to generate pyrophosphate (PP_i), an inhibitor of hydroxyapatite formation¹.

- Our patient developed painful and compromising calcium deposition during periods of elevated estrogen levels (neonate, puberty, OCP initiation) leading the authors to query if estrogen may modulate extra-skeletal calcifications.
- Population studies have demonstrated a reduction in FGF23 levels associated with estrogen hormone replacement².
- While a great deal remains to be delineated in FGF23 regulation, clear differences have been observed in infancy, adolescence and between sexes that suggest estrogen may contribute in this case, and may offer insights into mineral homeostasis³.
- Experimental therapies to minimize calcium deposits and reverse systemic calcifications in IAC and other conditions have been proposed; including: first-generation bisphosphonates, sodium thiosulfate and acetazolamide.

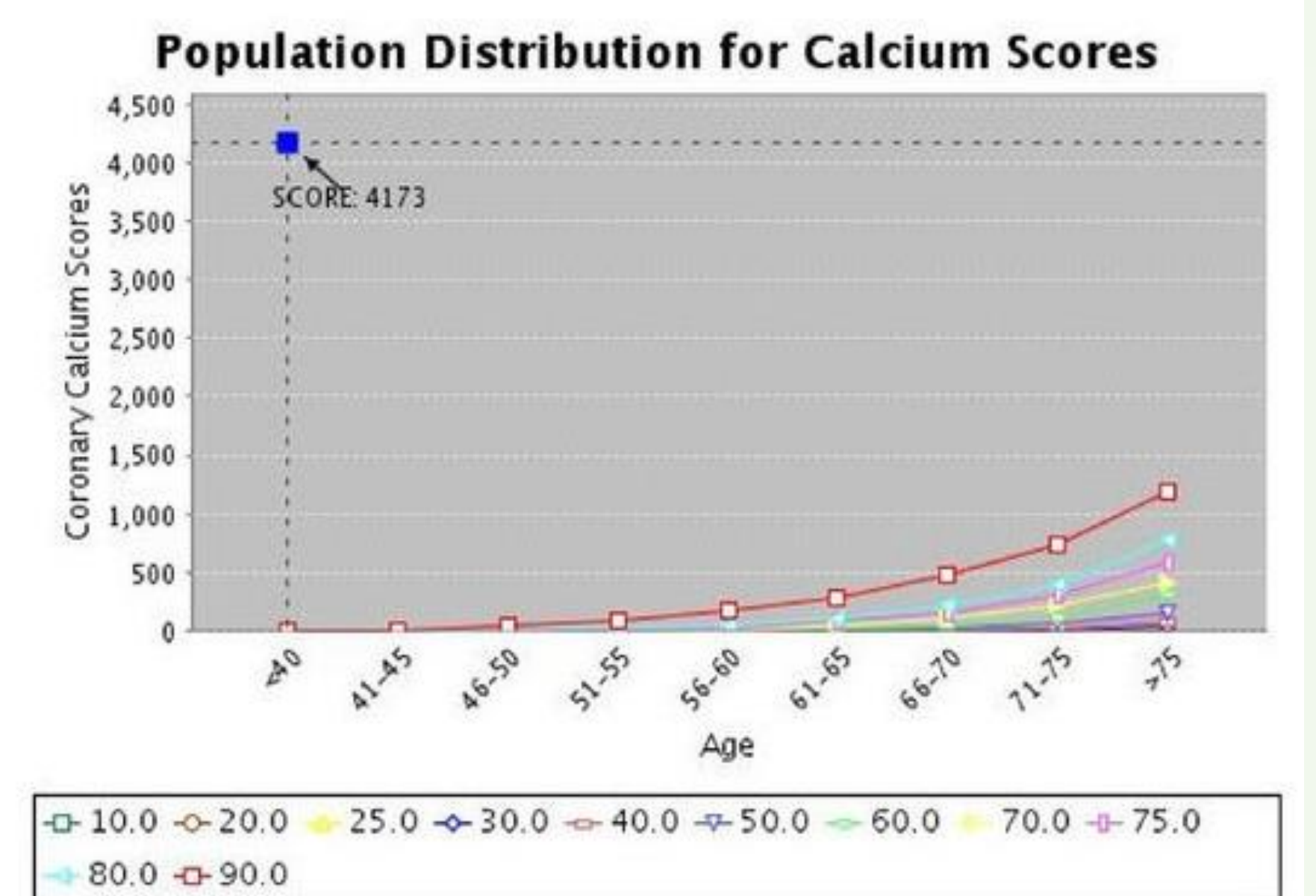


Figure 3. Gross elevations of coronary artery calcium content in 20 year old IAC patient compared to expected levels by age.

Conclusion

- IAC is a rare and often fatal condition in infancy, such that our adult survivor is allowing rare insights into clinical outcomes through to full maturation.
- Here, we present an adult survivor of IAC arising from a proven compound heterozygous *ENPP1* mutations, allowing a unique look at possible exacerbating and mitigating factors for calcium-phosphate deposition.
- The apparent exacerbation of calcification formation during times of increased estrogen suggest a possible estrogen-signaling mechanism for future investigation.
- Further analysis of the disease course may offer insights into the underlying mechanisms of mineral homeostasis and opportunities for future therapeutic targets.

References

1. Bowman, M.A.H., McNally, E.M. Trends in Cardio Med 2012 May; 22(4): 93–98.
2. Ix, J.H et al. Am J Kidney Dis. 2011 Nov;58(5):737-45
3. Holmlund-Suila, E., et al. Horm Res Paediatr 2016; 85(4):232-41

