



Brenzoni L, Cassinelli H, Bergadá I.

Centro de Investigaciones Endocrinológicas "Dr. César Bergadá" (CEDIE), CONICET – FEI – División de Endocrinología, Hospital de Niños Ricardo Gutiérrez

Background: skeletal morbidity has been recognized as a complication of Acute Lymphoblastic Leukemia (ALL) in children as well as for its treatment (osteotoxic drugs specially glucocorticoids and methotrexate may further affect bone strength), occurring at diagnosis, during chemotherapy and/or years later.

Aim: to describe the adversely effect on bone health, in terms of vertebral fractures (VF) and bone mineral density (BMD), in the follow-up of children with ALL.

Design: descriptive and retrospective study.

Patients: children from 1 to 17 years of age with ALL were included to assess bone health. To be included, they should have at least one lateral thoracolumbar spine radiographs (LTSR) and/or dual-energy x-ray absorptiometry (DXA) during follow up.

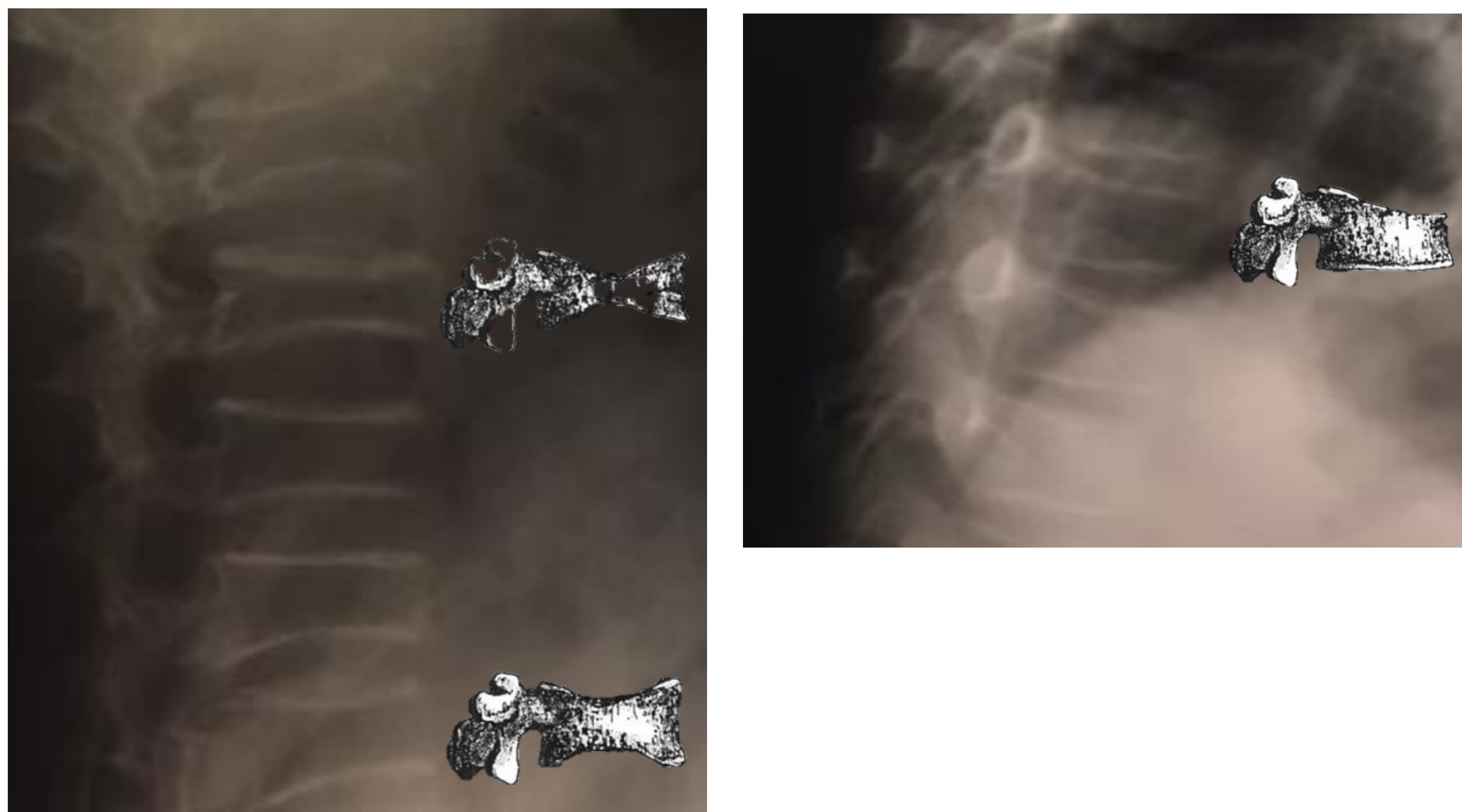
Exclusion criteria:

- Relapsed ALL or bone marrow transplant-
- Oral/inhaled glucocorticoids treatment during ≥ 3 months in the 12 months preceding ALL diagnosis.
- Other comorbidities: malabsorption, eating disorders, skeletal dysplasia or other bone diseases.
- Patients with missing data on their clinical charts

Results: 29 children with ALL were included.

Table 1. Clinical and auxological characteristic of the cohort of children with ALL (n= 29)	
Demographic data	
Sex F/M (%)	13/16 (45/55)
Age at diagnosis (years)*	4.4 (1.31-15.7)
Diagnosis	
B-cells ALL/ T-Cells ALL	29/0
First endocrinology assessed	
Age (years)*	7.1 (2.9-15.7)
Pubertal development (Tanner)	
Prepubertal (%)	24/29 (83)
Pubertal (%)	5/29 (17)
Weight Z score**	0.91 \pm 1.38
Height Z score**	-0.09 \pm 1.16
BMI***	19 \pm 2.9
Overweight (%)	3/26 (11.5)
Obesity (%)	8/26 (31)
Comorbidity (%)	6/29 (21)
Follow up time (months)	46 \pm 42.3
* Median (range)	
** Data expressed as mean \pm SD	
*** BMI: Body Mass Index	

Fig. 1. Lateral thoracic radiographs shows multiple fractures with moderate and severe biconcave deformity (left), and moderate wedge deformity (right).



Methods:

Clinical and auxological characteristic were recorded. We registered bone injury at diagnosis, during treatment and/or once finished chemotherapy. Bone injury was defined as:

- VF which were assessed by LTSR. We determined the height of the fractures (in case it was feasible) and characterized them using Genant semiquantitative method.
- Low lumbar spine BMD evaluated by DXA (using either Hologic or Lunar Prodigy). We considered low BMD a Z-score below -2 SD.

The occurrence of VF or abnormal BMD were recorded (in months) since diagnosis. In addition, bone pain, fractures in other areas and/or other skeletal lesion were registered.

Table 2. Bone assessment	
Patients assessed with LTSR (n)	22/29
Patients with vertebral fractures (n)	7/22
Sex (F/M)	1/6
12 month following initiation of therapy	5/7
Follow up (12-24 months)	2/7
VF with low BMD	2/7
Patients assessed with DEXA (n)	26/29
BMD Z score (<12 month following initiation of therapy)*	-3.9 (-4/+1.6)
BMD Z score in follow up (>12 month)*	-0.6 (-4/+2.5)
Patients with low BMD (n)	5/26
Sex (F/M)	1/4
12 month following initiation of therapy	2/5
Follow up (>12 months)	3/5
Time since diagnosis (months)*	60 (25-168)
BMD Z score*	-2.6 (-4/-2.1)
Bone pain (%)	6/29 (21.7)
Back pain	5/6
Other localization ‡	1/6
Back pain + VF	2/6
Other skeletal lesion (%)**	3/29 (10.3)
* Median (range)	
**Hip and knee osteonecrosis, spondylolisthesis and spondylolysis.	

- According the morphology of VF, 4 patients had wedge deformity, 2 of them with multiple compromise. The other 3 children combined wedge and biconcave deformity. The T4, T5, T6, T7, T8, L1 and L5 were commonly affected.
- No VF were observed after having completed treatment.
- Those patients with low BMD improved their Z score in further visits.

Conclusion:

VF are common in children with ALL and more prevalent along the first year of treatment. Usually are asymptomatic, therefore might remain undetected if routine surveillance is not performed.

The BMD can be affected as well, so an early diagnosis and intervention should be considered in order to avoid an altered future peak bone mass.

Bibliography:

- Alos N, Grant RM, Ramsay T, et al. High incidence of vertebral fractures in children with acute lymphoblastic leukemia 12 months after the initiation of therapy. *J Clin Oncol.* 2012.
- Halton J, Gaboury I, Grant R, et al. Advanced vertebral fracture among newly diagnosed children with acute lymphoblastic leukemia: results of the Canadian Steroid-Associated Osteoporosis in the Pediatric Population (STOPP) research program. *J Bone Miner Res* 2009.
- Fracture prediction and the definition of osteoporosis in children and adolescents: the ISCD 2013 Pediatric Official Positions. Bishop N, Arundel P, Clark E, et al. *J Clin Densitom.* 2014 Apr-Jun;17(2):275-80.

