



# A novel homozygous mutation in the CASR gene in A neonate with severe primary hyperparathyroidism; A case report.

Ali Alqadi, Enaam Raboei, Abdullah Ghafouri, Albandari alquthami, Razan Alghanmi. King Fahad Armed Forces Hospital, Jeddah –Saudi Arabia  
Address for correspondence : Ali Alqadi, E-Mail : alqadi\_1425@yahoo.com

## INTRODUCTION

Neonatal severe primary hyperparathyroidism (NSHPT, MIM239200) is a potentially lethal autosomal recessive disorder characterized by severe hypercalcemia, markedly elevated serum PTH levels and skeletal abnormalities that include multiple fractures, demineralization and erosions(1). Children present with failure to thrive, poor feeding, lethargy and respiratory distress at any time in the first six months of life, however, symptoms often manifest in the first few days after birth. NSHPT is often refractory to medical therapy and requires surgical treatment with subtotal parathyroidectomy or total parathyroidectomy with autotransplantation(1,2,3,11). Prompt diagnosis and early appropriate intervention for NSHPT is so crucial to avoid death or devastating neurological sequelae (1,2,3,11). NSHPT is secondary to biallelic loss of function mutation in the CASR gene that encodes the calcium sensing receptor (CaSR) (4,5,6,7). It is located at chromosome 3q13.3-q21.1 as it spans over 50 kb of genomic DNA and has a coding region of 3234 bp, which is contained within 6 exons (7,8). About 200 Mutations have been previously described in the CASR gene can result in gain or loss of receptor function. Gain of function mutations are associated with autosomal dominant hypocalcemia while loss of function mutations are associated to two recognized phenotypes; familial hypocalciuric hypercalcemia(FHH) and neonatal severe primary hyperparathyroidism(NSHPT)(8,9,14,15). The calcium-sensing receptor (CaSR) is a G-protein coupled receptor (GPCR) family member that adjusts the extracellular calcium set point regulating PTH secretion and renal calcium excretion. CaSR is expressed in various tissues but mostly in the parathyroid chief cells and in epithelial lining of renal tubules (5,6).

## OBJECTIVE

Is to report clinical and genetic findings in Saudi baby boy with NSHPT due to a novel homozygous mutation in the CASR transmitted as an autosomal recessive trait that has never been described and to run over the monitoring of his biochemical data throughout the clinical course.

## SUBJECTS AND METHODS

A-3200 grams –male newborn with 39 weeks gestation was born to first degree consanguineous Saudi parents by normal vaginal delivery after eventless pregnancy. On the postnatal 10<sup>th</sup> day, he was hospitalized via our pediatric emergency room for poor feeding, hypoactivity and moderate dehydration. His physical examination was largely unremarkable. Laboratory work up revealed an incidental severe hypercalcemia 5.4 mmol/l (N:2.1-2.7), hypophosphatemia 0.76 mmol/l(N:1- 1.95), 25- Hydroxyvitamin D 59.3 nmol/l(N:75-250) and markedly elevated PTH level 55.7 pmol/l (N: 1.6-6.9). So the diagnosis of NSHPT was suspected, He was connected to intravenous fluids in the form of 0.9 normal saline double maintenance volume along with intravenous furosemide 1-2 mg/kg BID in an attempt to induce diuresis. Low calcium formula was introduced and intravenous glucocorticoid therapy was added. Calcium levels, initially, went down but remained significantly in the hypercalcemic references. In order to intensify the treatment we added pamidronate therapy however because of respiratory illness we did hold after a single dose(10,13). Calcimimetic drug is not available in our institution(10,12). Skeletal survey revealed generalized osteopenia and demineralization with minimal erosion in the right femur, no pathologic fractures were noted (fig1). Neck ultrasound failed to demonstrate enlarged parathyroid glands and renal sonography was negative for stones and nephrocalcinosis. 99M-Tc-sestaMIBI scan showed homogenous uptake of the radiotracer and no evidence of parathyroid adenoma (fig2). Molecular analysis identified a homozygous inactivating mutation in the CASR gene, so the diagnosis of NSHPT was eventually established. On the 25<sup>th</sup> day postnatally and as intensive medical therapy has failed to restore eucalcemia, surgical intervention was considered. Total parathyroidectomy with autotransplantation of a portion of a gland in the right sternocleidomastoid muscle was carried out. Histological examination of parathyroid glands revealed diffuse chief cell hyperplasia consistent with NSHPT (fig 3). He was transferred to NICU where he stayed in for 72 hours, extubated, successfully, on the 3<sup>rd</sup> day post operatively. Post operative Hypocalcemia (1.8 mmol/l) ensued on the 2<sup>nd</sup> day so parenteral calcium infusion and alfacalcidol commenced and continued for few days till oral intake is established. The follow-up of the patient for biochemical profile throughout the course of treatment is shown in (table 1). The child is currently at age of 18 months exhibiting normal milestones and anthropometrics for age and maintaining eucalcemic values on 1 mcg of oral alfacalcidol (table 1).

**METHODS**: Both parents have signed informed consent and protocol was approved by the research ethics committee at King Fahad Armed Forces Hospital- Jeddah. Genomic DNA was extracted from peripheral white blood cells for the patient and his parents, 5 cc of blood collected from each one in EDTA tubes using the standard methods and sent to unilabs in Germany. The gene /regions of interest was captured with TruSight One kit (Illumina). High throughput sequencing on Miseq sequencer. Bioinformatics analysis restricted to CASR (NM\_001178065.1, mean depth of reads: 102+/- 33, coverage 100%). PCR amplification and bidirectional sanger sequencing of the exon 7 of CASR gene was undertaken. This analysis technique can not detect mutations in the promoter repeats and large deletions or duplications.

## TABLES And FIGURES

Test	Reference values	On admission	2 weeks post medical treatment (Day of OR)	6 months post parathyroidectomy	18 months post parathyroidectomy
Ca	2.1 – 2.7 mmol/L	5.44	3.31	2.6	2.34
Po4	1.45 – 2.1 mmol/L	0.76	1.28	2.1	1.98
PTH	1.6 – 6.9 pmol/L	55.78	161.2	0.72	0.1
ALP	70-250 U/L	279	125	198	131
25-OH vitamin D	75 – 250 nmol/L	59.3	74.2	79.2	90.6

Table 1

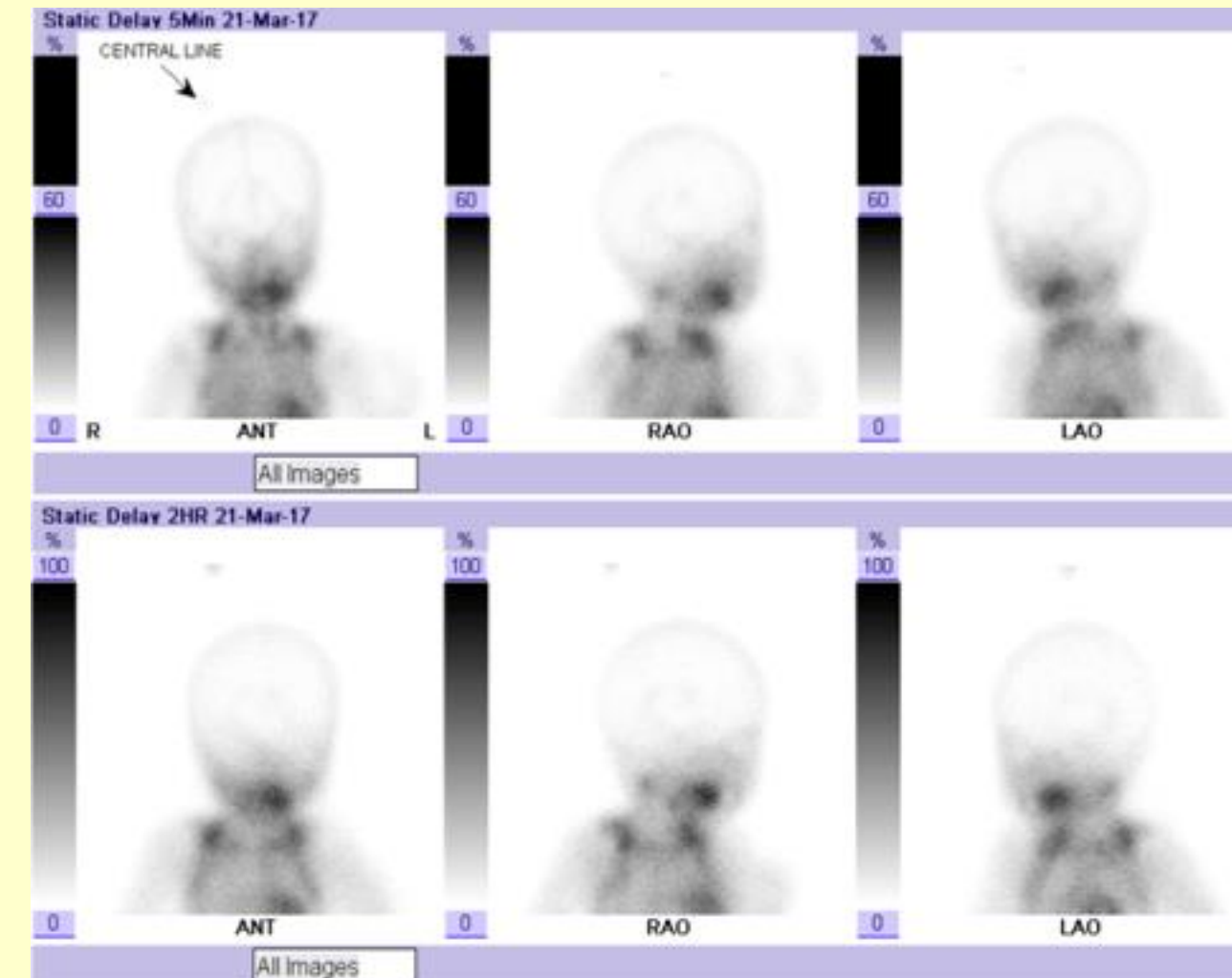


Figure 2

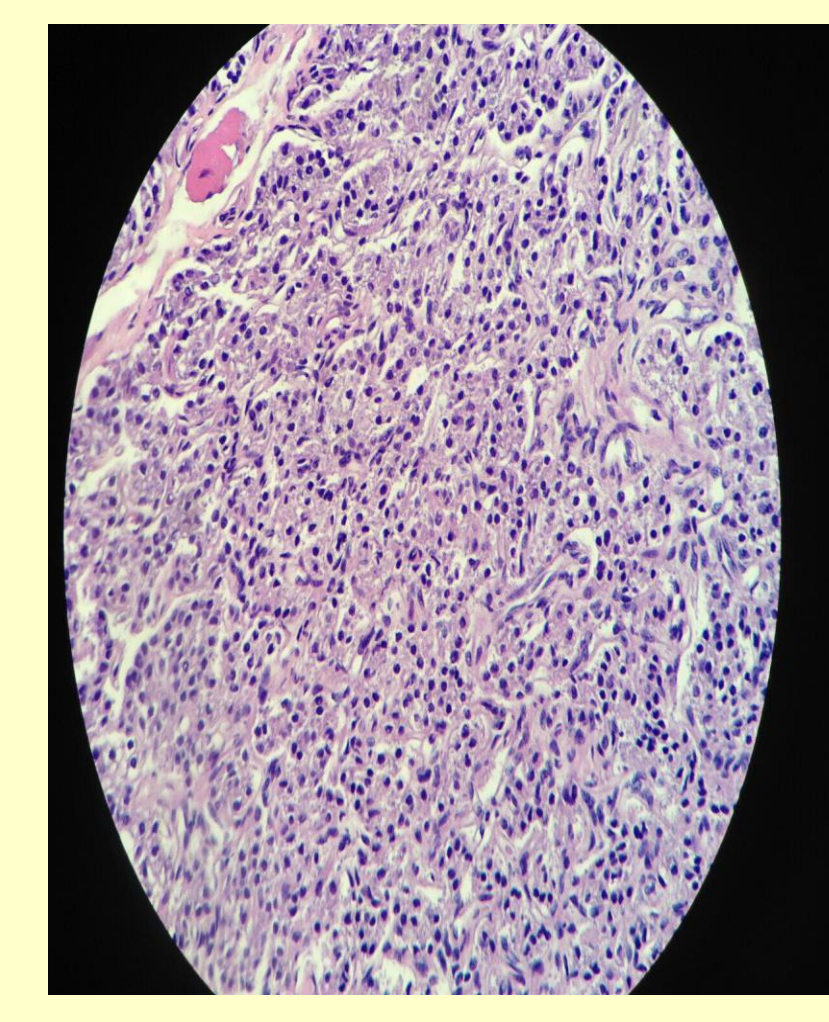


Figure 3

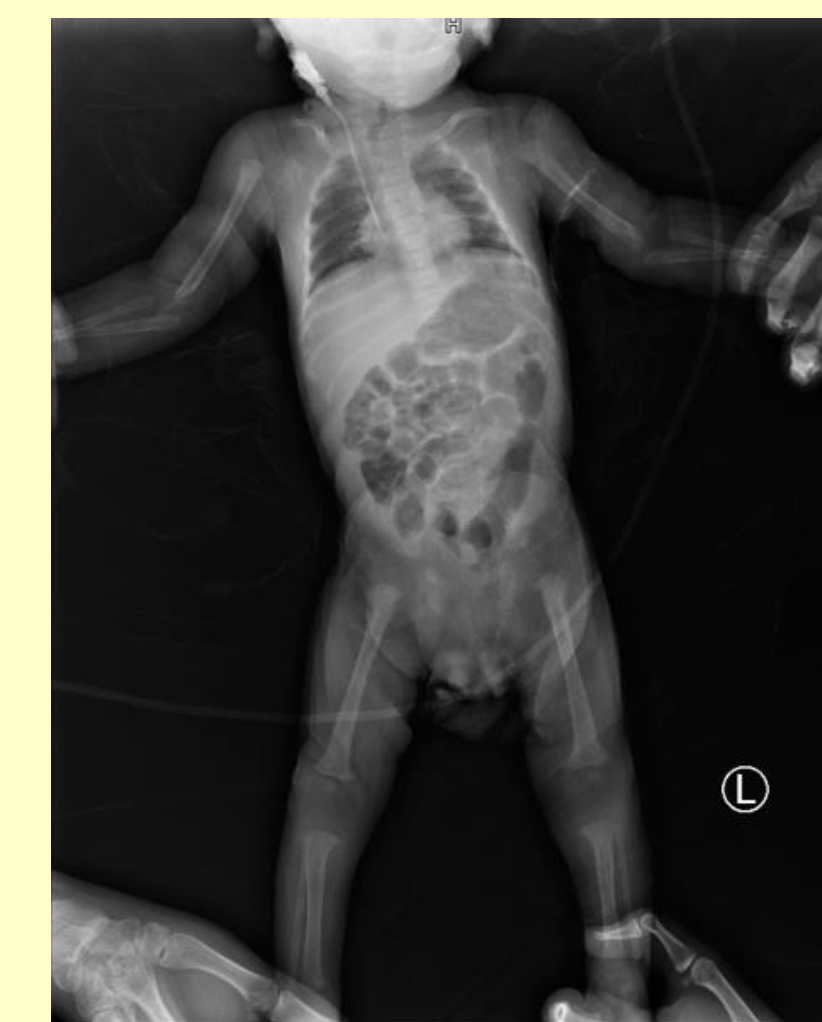

Figure 1

## RESULTS

A sequence variant in the CASR was identified (G>T point mutation at nucleotide c. 2084 in exon 7 (c.2084 G>T) resulting in the replacement of Glycine with a big Valine at codon 685 (p.Gly685Val). Two copies of this CASR variant were present in the genome of this neonate while a single copy of the CASR variant was present in both of the clinically and biochemically normal Parents, confirming that the pattern of transmission is consistent with autosomal recessive inheritance. This region is a very well conserved region of the protein, namely the transmembrane domain, which is indeed very important for regulation of the channel and is recognized as a mutational hotspot for hypercalcemia. It is a very rare variant, not present in the Exome Aggregation Consortium (ExAC) nor in the ClinVar databases and following the ACMG guidelines is classified as likely pathogenic.

## CONCLUSION

We, hereby, report the identification of a novel homozygous loss of function mutation in the CASR gene Gyl685Val in this Saudi neonate with severe hypercalcemia which has never been described before. Unaffected parents were heterozygous carriers. Functional studies are needed to examine the role of this mutation in CASR activity.

## References

- 1- S. Al-Shanafey, R. Al-Hosaini, A. Al-Ashwal, and A. Al-Rabeeah, "Surgical management of severe neonatal hyperparathyroidism: one center's experience," *Journal of Pediatric Surgery*, vol. 45, no. 4, pp. 714–717, 2010.
- 2- Blair JW, Carachi R. Neonatal primary hyperparathyroidism - a case report and review of the literature. *Eur J Pediatr Surg*. 1991;1(2):110-4.
- 3- Doria AS, Huang C, Makitie O, et al. Neonatal, severe primary hyperparathyroidism: a 7-year clinical and radiological follow-up of one patient. *Pediatr Radiol*. 2002;32(9):684–689
- 4- Hendy GN, Canaff L. Calcium-Sensing Receptor Gene: Regulation of Expression. *Front Physiol*. 2016;7:394.
- 5- Zhang C, Miller CL, Gorkhali R, Zou J, Huang K, Brown EM, Yang JJ. Molecular Basis of the Extracellular Ligands Mediated Signaling by the Calcium Sensing Receptor. *Front Physiol*. 2016;7:441.
- 6- Thakker RV. The calcium-sensing receptor: and its involvement in parathyroid pathology. *Ann Endocrinol (Paris)*. 2015;76:81–3.
- 7- Ward BK, Magno AL, Walsh JP & Ratajczak T. The role of the calcium-sensing receptor in human disease. *Clinical Biochemistry* 2012 45 943–953. (doi:10.1016/j.clinbiochem.2012.03.034)
- 8- Hannan FM, Nesbit MA, Zhang C, Cranston T, Curley AJ, Harding B, Fratter C, Rust N, Christie PT, Turner JJ et al. Identification of 70 calcium-sensing receptor mutations in hyper- and hypo-calcemic patients: evidence for clustering of extracellular domain mutations at calcium-binding sites. *Human Molecular Genetics* 2012 21 2768–2778. (doi:10.1093/hmg/dds105)
- 9- Al-Khalaf FA, Ismail A, Saliman AT, Cole DE & Ben-Omran T. Neonatal severe hyperparathyroidism: further clinical and molecular delineation. *European Journal of Pediatrics* 2011 170 625–631. (doi:10.1007/s00431-010-1335-z)
- 10- Wilhelm-Bals A, Parvex P, Magdelaine C, Girardin E. Successful use of bisphosphonate and calcimimetic in neonatal severe primary hyperparathyroidism. *Pediatrics* 2012;129:e812e6.
- 11- Lutz P, Kane O, Pfersdorff A, Seiller F, Sauvage P, Levy JM. Neonatal primary hyperparathyroidism: total parathyroidectomy with autotransplantation of cryopreserved parathyroid tissue. *Acta Paediatr Scand* 1986;75:179e82.
- 12- Atay Z, Bereket A, Haliloglu B, Abali S, Ozdogan T, Altuncu E, et al. Novel14 homozygous inactivating mutation of the calcium-sensing receptor gene (CASR) in neonatal severe hyperparathyroidism-lack of effect of cinacalcet. *Bone* 2014;64:102e7.
- 13- Waller S, Kurzawinski T, Spitz L, Thakker R, Cranston T, Pearce S, et al. Neonatal severe hyperparathyroidism: genotype/phenotype correlation and the use of pamidronate as rescue therapy. *Eur J Pediatr*. 2004;163(10):589-94.
- 14- J Pediatr Endocrinol Metab. 2014 Sep;27(9-10):851-6. A novel CASR mutation associated with neonatal severe hyperparathyroidism transmitted as an autosomal recessive disorder. Diaz-Thomas A, Cannon J, Iyer P, Al-Maawali A, Fazalullah M, Diamond F, Mueller OT, Root AW, Alyaarubi S.
- 15- Clin Cases Miner Bone Metab. 2017 Sep-Dec;14(3):354-358. Neonatal severe hyperparathyroidism secondary to a novel homozygous CASR gene mutation. Ahmad N1, Bahasan M1, Al-Ghamdi BAA1, Al-Enizi HF1, Al-Zahrani AS2.

