

# Familial hypercholesterolemia due to homozygous *LDLRAP1* mutation: variability of phenotype and response to medical therapy

E. Panou<sup>1</sup>, S. Schumacher<sup>2</sup>, J. Woelfle<sup>1</sup>

Pediatric Endocrinology Division, Children's Hospital, University of Bonn, Germany  
Institute of Human Genetics, University of Bonn, Germany

## Background:

Familial hypercholesterolemia (FH) leads to markedly elevated circulating levels of low-density lipoprotein cholesterol (LDL-C) and is associated by a significantly increased cardiovascular mortality already in childhood and adolescence. FH is caused by dominant mutations in the genes encoding LDL-receptor (LDLR), ApoB-100 and pro-protein convertase subtilin/kexin9 (PCSK9), whereas rarely recessive forms due to mutations in LDL receptor adaptor protein 1 (LDLRAP1) have been reported.

Statins have proven efficacy as the mainstay of treatment in FH. Even at the highest doses of the most efficacious statins, however, only modest reductions in LDL-C plasma levels are observed in most patients. Addition of the cholesterol absorption inhibitor ezetimibe further lowers LDL-C levels. Combinations of statins with other cholesterol-lowering medications, including niacin, fibrates, bile acid sequestrants and PCSK9 inhibitors, have been used successfully in FH and can be considered to further lower LDL-C levels. Further treatment strategies include lipid apheresis, plasmapheresis and in few cases liver transplantation.

## Objective:

To describe the clinical course and response to pharmacotherapy in two patients with homozygous familial hypercholesterolemia due to a homozygous *LDLRAP1* gene mutation.

## Methods/Results:

We report on two siblings of consanguineous Syrian parents with a late diagnosis of familial hypercholesterolemia.

The older sibling, a 10.5 year-old girl presented in our outpatient clinic for treatment of „molluscum contagiosum“ after a five-year-long history of exanthema on the extensor surfaces of her extremities. Based on the morphological appearance we suspected eruptive xanthomas. Subsequent biochemical analysis revealed drastically elevated levels of total cholesterol (18.4 mmol/l) and LDL-C (14.3 mmol/l). In addition, ultrasound of the carotid arteries demonstrated an abnormal carotid intima-media thickness with small atherosclerotic plaque lesions. A 9-year-old brother did not yet present xanthomas. However, his laboratory tests also demonstrated significantly elevated levels of total cholesterol (9.8 mmol/l) and LDL-C (7.2 mmol/l). All remaining family members did neither exhibit hyperlipidaemia nor any history of cardiovascular diseases.

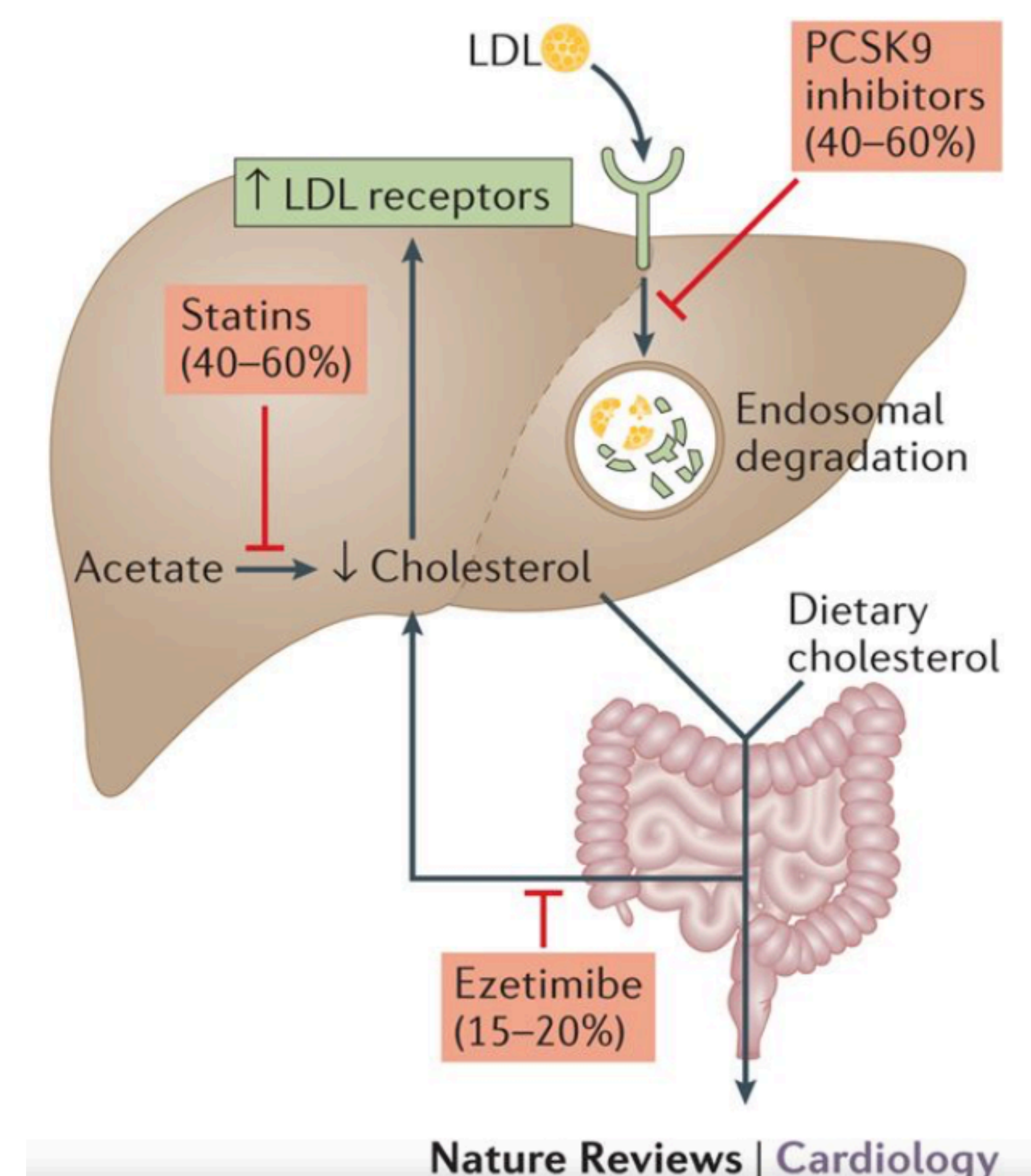
Based on the biochemical findings and clinical picture, we suspected familial hypercholesterolemia and started atorvastatin and ezetimibe treatment in both subjects, with a final daily dosage of atorvastatin 40 and 20 mg, respectively, and ezetimibe 10mg in both patients. Combination therapy led to a decrease of total cholesterol to 5.5 mmol/l (girl) and 4.8 mmol/l (boy), respectively, and LDL-C of 3.2 mmol/l and 3.3 mmol/l, respectively after 3 months. So far combination pharmacotherapy was efficient and safe for 12 months, with no relevant adverse events.

Genetic analysis of the *LDLRAP1* gene revealed a previously described homozygous mutation in the *LDLRAP1* gene (c.406C>T; p.Gln136\*) in both siblings, probably leading to an extremely shortened, non-functional protein.

## Conclusion:

Pharmacological combination therapy with statin/ezetimibe can effectively decrease cholesterol concentrations into the target range in homozygous familial hypercholesterolemia. Still, to avoid accelerated atheromatous disease, an earlier diagnosis of familial hypercholesterolemia through a general screening program would be warranted.

**Figure 1: Statins, ezetimibe, and PCSK9 inhibitors all increase the expression of LDL receptors and reduce LDL-cholesterol levels (by percentages shown).**



S. Grundy et al, Nature Reviews Cardiology, vol. 13; 74-75 (2016)

