

BARIATRIC SURGERY AS TREATMENT OF PRIMARY PSEUDOTUMOR CEREBRI IN A MALE ADOLESCENT: CASE REPORT

Marina Ybarra¹; Tiago Jeronimo dos Santos¹; Edjane Santos Queiroz¹; Ludmilla Rachid¹; Ruth Rocha Franco¹; Louise Cominato¹; Frederico Castelo Moura²; Manoel Carlos Velhote³; Durval Damiani¹

1. Endocrinology Unit – Department of Pediatrics – Children’s Institute – University of São Paulo – Brazil

2. Department of Ophthalmology – University of São Paulo – Brazil

3. Department of Pediatric Surgery – Children’s Institute – University of São Paulo - Brazil

BACKGROUND

Primary *Pseudotumor cerebri* characteristics includes:

- Increased intracranial pressure
 - lumbar puncture > 90th percentile (28 cm of H₂O)
- Alert and oriented patient
- Normal neuroimaging
- Normal cerebrospinal fluid analysis
- Papilledema may or may not be present
- Headache (most common symptom – up to 84%)
- Visual loss (major morbidity - up to 68%)
- Obesity (consistent risk factor)

CASE PRESENTATION

A 16-year-old morbidly obese African-Brazilian boy:

- Weight: 133.6 kg;
- **BMI: 44.1 kg/m²** (Z: +3.83)
- Tanner 5
- Complaint: **headaches** (bi-parietal, high intensity and pulsatile)
- **Normal Cranial CT**
- **Lumbar puncture:** pressure of **40 cm of H₂O**
- Ophthalmologic evaluation: **bilateral papilledema** with normal visual acuity and absence of abducens nerve palsy (Figure A; arrow).

DIAGNOSE = Primary *Pseudotumor cerebri*

He was started on acetazolamide, which provided partial improvement of his symptoms.

After 3 months of treatment, his symptoms had not completely resolved and bariatric surgery was recommended.

REFERENCES

- Avery RA, Shah SS, Licht DJ, Seiden JA, Huh JW, Boswinkel J, et al. Reference range for cerebrospinal fluid opening pressure in children. *N Engl J Med.* 2010;363(9):891-893.
- Manfield JH, Yu KK, Efthimiou E, Darzi A, Athanasiou T, Ashrafi H. Bariatric Surgery or Non-surgical Weight Loss for Idiopathic Intracranial Hypertension? A Systematic Review and Comparison of Meta-analyses. *Obes Surg.* 2017;27(2):513-521.
- Styne DM, Arslanian SA, Connor EL, Farooqi IS, Murad MH, Silverstein JH, et al. Pediatric Obesity-Assessment, Treatment, and Prevention: An Endocrine Society Clinical Practice Guideline. *J Clin Endocrinol Metab.* 2017;102(3):709-757.

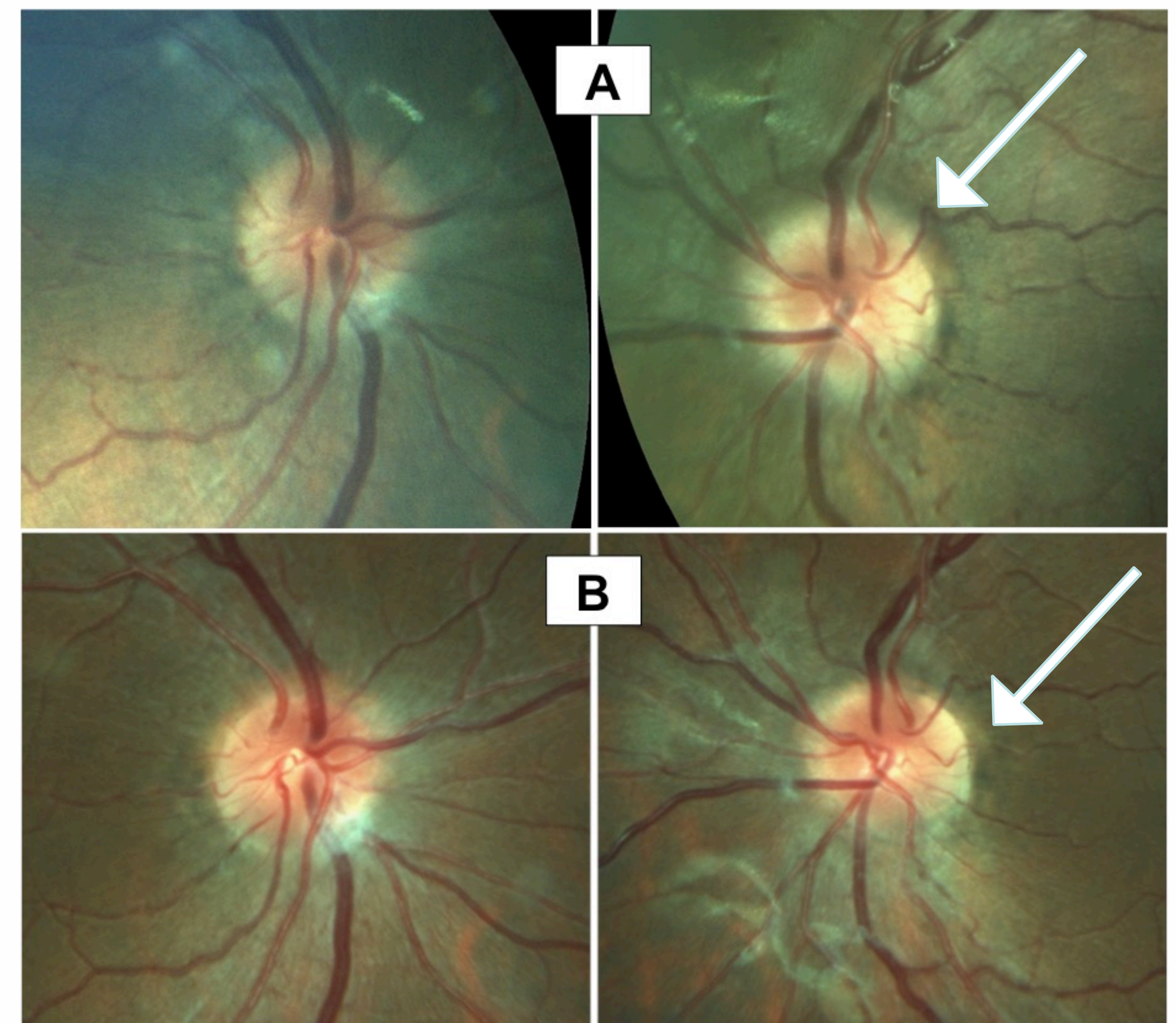


Figure 1: Eye fundus photography (A) before and (B) after laparoscopic sleeve gastrectomy. Note the improvement of bilateral papilledema (arrow).

The patient underwent an **uncomplicated laparoscopic sleeve gastrectomy.**

- **67.5% excessive weight loss** (at 1-year follow-up)
- Weight: 94.5 kg
- **BMI: 31.2 kg/m²** (Z +2.6)
- **Complete resolution of symptoms**
- Ophthalmologic evaluation: normal visual acuity in both eyes and **improvement of bilateral papilledema** (at 3-month follow-up)

CONCLUSIONS

Our case showed complete resolution of Primary *Pseudotumor cerebri* signs and symptoms in a male adolescent who underwent bariatric surgery and experienced 67.5% excessive weight loss after 1 year. The treatment option seemed to be safe and effective.