

# Dumping Syndrome in a neonate with Esophageal Atresia correction

Angélica González Patiño, Clinica integral de Diabetes, Division of Pediatric Endocrinology, Medellín, Colombia  
Carolina Jaramillo Arango, Division of Pediatric Endocrinology, Hospital Pablo Tobón Uribe, Medellín, Colombia  
Jennyfer Monroy Espejo, Division of Pediatric Endocrinology, Hospital Pablo Tobón Uribe, Medellín, Colombia

**Introduction:** Dumping Syndrome (DS) has been recognized as a major complication of Nissen fundoplication in young children. Although other causes have been described.

We report an infant with esophageal atresia who presented with late DS caused by a surgical complication, Dumping and Horner syndrome were diagnosed after esophageal reconstruction.

**Case description:** A male newborn with prenatal diagnosis of right Aortic Arch was born by vaginal delivery, APGAR test 7-8-10/10, with clinical signs suspicious of esophageal atresia during neonatal adaptation, confirmed by radiological findings showing distal esophageal atresia and distal tracheoesophageal fistula (Gross type C, Vogt type 3B). At 2 days of life he underwent correction and primary esophageal anastomosis with closure of fistula.

After procedure, palpebral ptosis and diaphragm paralysis were noted (ipsilateral to surgical incision).

Parenteral nutrition was initiated before surgery, no hypoglycemia was reported. He was fed with progressive tolerance, but he presented postprandial hypoglycemia associated with diaphoresis, tachycardia, pallor and hypotonia, always 2 hours after oral feeding and related with faster administration of feeding bottle, at physical examination asymmetrical diaphoresis (left side face), miosis and ipsilateral palpebral ptosis were found, followed by abdominal distension alleviated by abundant diarrhea and vomit. Such episodes continued during the hospitalization, and got worse until his referral to our unit.

Dumping syndrome was suspected and confirmed by an abnormal glucose tolerance test, with high serum glucose level (155 mg/dl after ingestion) and late hypoglycemia (58 mg/dl 180 min after ingestion). Simultaneous measurements of insulin were within the reference range (1.9 IU/L at ingestion, 13.7 IU/L 60 minutes after ingestion, and 1.6 UI/L 180 minutes after ingestion of glucose (Figure 1).

Gastric emptying, evaluated by technetium scintigraphy, was within the reference range.

The patient was treated with frequent and reduced feeding with improvement of glycemic values and autonomic symptoms, receiving anti-reflux formula with no hypoglycemic episodes and adequate weight gain.

**Discussion:** DS has been a reported complication in children with esophageal intervention, current data is limited to case reports and clinical trials are currently in recruitment phase in order to determine the frequency of DS after operation of esophageal atresia type III. Such manipulation can cause alteration of gastric emptying mechanisms, related to its anatomy or its intrinsic innervation.

DS must be suspected in neonates with congenital gastrointestinal malformations who had undergone surgical manipulations and exhibit postprandial hypoglycemia related to autonomic symptoms. It can be divided in early dumping (30 minutes after a meal) which is related to increased delivery of hyperosmolar nutrients into the bowel, and late dumping (120 a 180 minutes after a meal) as result of a reactive hypoglycemia induced by incretin response to carbohydrate ingestion, the last one was proved in our patient as shown in figure 1.

When DS is suspected, a glucose tolerance test usually reveals the presence of hyperglycemia within the first hours and also late hypoglycemia. This is a simple and reliable diagnostic procedure useful to confirm or rule out the suspected diagnosis.

DS can resolve spontaneously in most patients, or may need dietary modification or medications such as cornstarch, pectin and octreotide. Surgical treatment is reserved for non-responsive cases.

## References

- Berg P, McCallum R. Dumping syndrome: A review of the current concepts of pathophysiology, Diagnosis, and treatment. *Digestive Diseases and Sciences* 2016; 61: 11-18.
- Duvoisin G, Krishnan U. Gastric function in children with oesophageal atresia and tracheoesophageal fistula. *Front Pediatr* 2017; 5: 76.
- Dumping Syndrome After Operation of Esophageal Atresia Type II (DUMPING) ClinicalTrials.gov, Identifier: NCT02525705
- Kim Y, Moon SB. Pyloric reconstruction for refractory dumping syndrome after Nissen fundoplication and pyloroplasty in an infant: A case report. *J Ped Surg Case Reports* 2015: 505-507
- Michaud L, Sfeir R, Couttenier F, Turck D, Gottrand F. Dumping syndrome after esophageal atresia repair without antireflux surgery. *Journal of Pediatric Surgery* 2010; 45, E13-E15
- Rivkees SA, Crawford JD. Hypoglycemia Pathogenesis in Children with Dumping Syndrome. *Pediatrics* 1987; 80: 937 - 942
- Rossy M, Annibaldi R, Tonelli L, Palpacelli A, Albano V, Gatti S et al. A case of Dumping Syndrome in a patient undergoing esophageal atresia surgery. *Digestive and liver disease* 2014; 46: e85-e127.
- Dastamani A, Malhorta N, Güemes M, Morgan K, Rees C.M, Datanni M et al. Post-prandial hyperinsulinaemic hypoglycaemia after oesophageal surgery in children. *Horm Res Paediatric* 2018; 9: 1-5
- Vukovic R, Milenkovic T, Djordjevic M, Mitrovic K, Todorovic S, Sarajlija A et Al. Postprandial hyperinsulinemic hypoglycemia in a child as a late complication of esophageal reconstruction. *J Pediatr Endocrinol Metab* 2017; 30: 791-795.

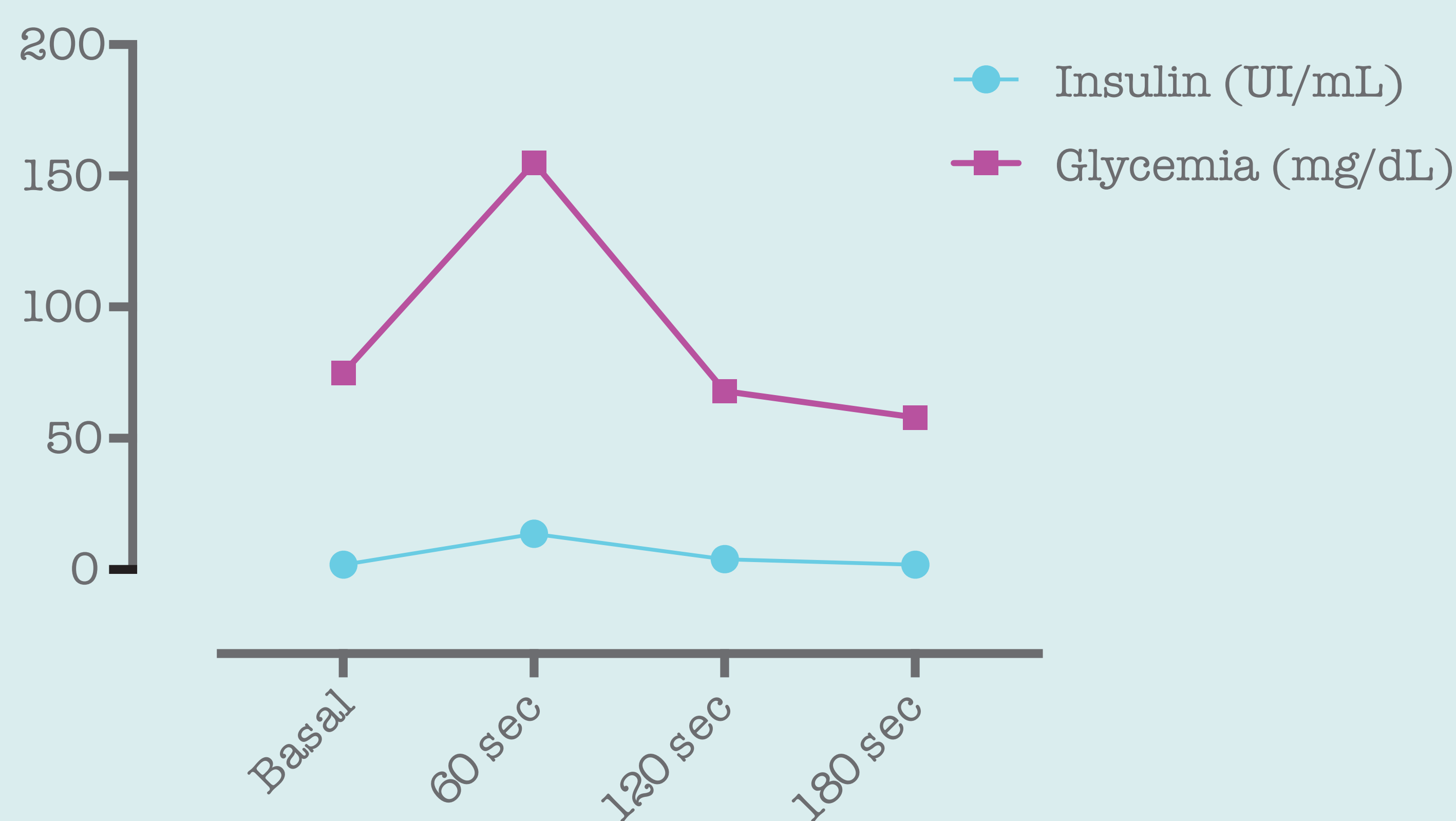


Figure 1

