



HEART AND AORTA ANOMALIES IN TURNER SYNDROME AND RELATION WITH KARYOTYPE

Aslı Derya Kardelen¹, Feyza Darendeliler¹, Ali Genco Gençay², Zuhul Bayramoğlu³, Behruz Aliyev⁴, Esin Karakılıç Özturan¹, Zehra Yavaş Abalı¹, Şükran Poyrazoğlu¹, Kemal Nişli⁴, Firdevs Baş¹

¹ IU, Istanbul Faculty of Medicine, Pediatric Endocrinology Department

² IU, Istanbul Faculty of Medicine, Department of Pediatrics

³ IU, Istanbul Faculty of Medicine, Pediatric Radiology Department

⁴ IU, Istanbul Faculty of Medicine, Pediatric Cardiology Department



Introduction: Turner Syndrome (TS) is associated with a high risk of cardiac anomalies and cardiovascular disease. Detailed cardiac evaluation at diagnosis and follow-up for the development of aortic dissection is indicated. Presence of coarctation of the aorta (CoA) and aortic dilatation is an important predictor of the risk and prognosis of aortic dissection.

Aim: Evaluation of our patients with TS for cardiac and aortic pathology using magnetic resonance imaging (MRI).

Materials and Methods: Clinical findings, karyotypes, echocardiogram (ECHO) findings and cardiac MRI results of 33 patients with TS were evaluated. Aortic dimensions were measured at various sites and recorded. Sites of measurement are shown in Figure 1. Standard Z scores of aortic diameters were calculated according to the method defined by Kaiser et al. Aortic size index (ASI) was calculated in cm/m² by dividing the diameter of the aorta by the body surface area (BSA).

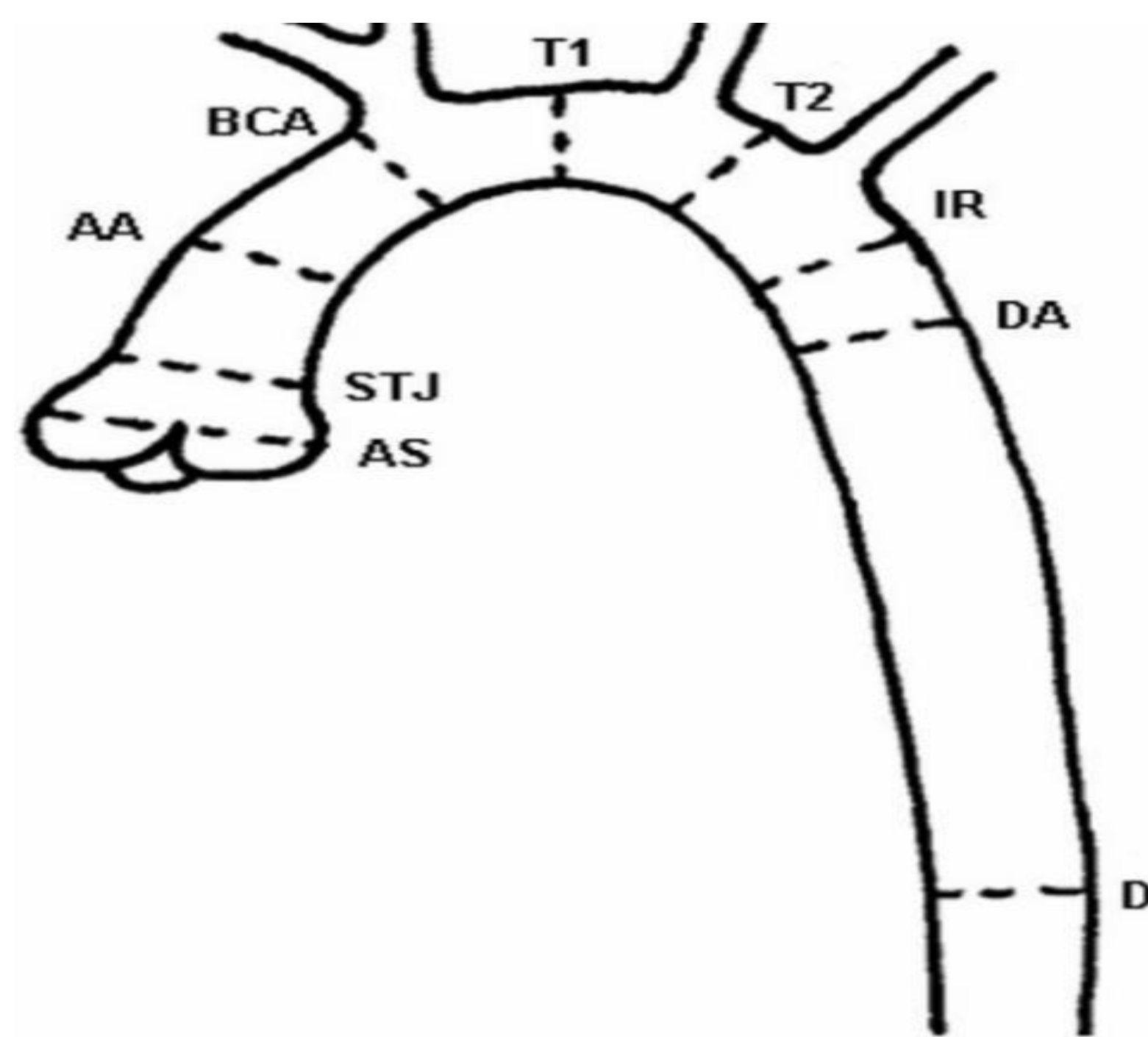


Figure 1. Sites of measurement of diameters of the aorta

Aortic sinus (AS), Sinotubular junction (ST), Ascending Aorta (AA), Proximal brachiocephalic artery (BCA), 1st transverse segment (T1), 2nd transverse segment (T2), isthmus (IR), Descending aorta (DA), Aortic diameter at the level of the diaphragm (D)

Results: Age at presentation (mean \pm SD) was 9.0 \pm 3.0 years. 15 patients were (%46) 45,X, 14 (%42) had mosaicism and 4 (%12) had the 46,XX;X chromosomal anomaly. MRI studies were obtained at 13.9 \pm 3.3 years, at which time the body mass index (BMI) SDS was 0.8 \pm 1.4. Clinical features of the patients are shown in Table 1. ECHO revealed bicuspid aortic valve (BAV) in 5 patients (15%) and CoA in 2 patients (6%). Four patients (12%) were hypertensive. No patients had aortic dissection. MRI revealed cardiac pathology in 10 patients (30%). Coarctation of the aorta (n=4), aberrant right subclavian artery (ARSA) (n=3), prominence of the ascending aorta (n=1), tortuosity of the descending aorta (n=1) and fusiform dilatation of the left subclavian artery (n=1) were found. Two of the 4 cases of CoA found on MRI were also detected with ECHO. One case of CoA was missed on ECHO because of its very distal location. One case was missed on ECHO due to its mild nature and the consequent the lack of a gradient on Doppler imaging.

References

- Yigit H, Önder A, Özgür S, Ayca Z, Karademir S, Doğan V. Cardiac MRI and 3D contrast-enhanced MR angiography in pediatric and young adult patients with Turner syndrome. *Turk J Med Sci*. 2017; 127-133
- Carlson M Airhart N, Lopez L, Silberbach M. Moderate Aortic Enlargement and Bicuspid Aortic Valve Are Associated With Aortic Dissection in Turner Syndrome. *Circulation*. 2012;126:2220-2226.
- Kaiser T, Kellenberger CJ, Albisetti M, Bergsträsser E, Valsangiacomo Buechel ER. Normal values for aortic diameters in children and adolescents-assessment in vivo contrast-enhanced CMR-angiography. *J Cardiovasc Magn Reson*. 2008 Dec 5;10:56.

Diameter of the sinotubular junction, which is measured to determine the risk of aortic dilatation, was found to be elevated and the mean Z score was above 2.0 [2.4 \pm 1.5; min - max: 0.3 – 5.7]. Median Z score for the diameter of the isthmus was (min - max) 0.9 (-2.0 – 4.0). Median Z score for the diameter of the ascending aorta was (min - max) 0.4 (-1.7 – 2.8). Median Z score for the diameter of the descending aorta was (min - max) -0.4 (-1.9 – 2.6). 45,X and non-45,X patients were compared with respect to aortic diameters and ASI. 45,X patients were found to have significantly higher ASI values (1.7 \pm 0.3 and 1.5 \pm 0.3, respectively p=0.036).

Table 1. Clinical features of the patients during this study

	Mean \pm SD	Median	Min-max
Age at MRI study (yr)	13.9 \pm 3.3	14.1	7.0-18.0
Weight SDS	-0.7 \pm 1.8	-0.3	-5.6-2.3
Height SDS	-2.5 \pm 1.3	-2.3	-5.7- -0.6
BSA	1.3 \pm 0.3	1.3	0.7-1.8
BMI SDS	0.8 \pm 1.4	1.1	-3.1-2.7

Table 2. Distribution of aortic diameters with respect to karyotype

	All Patients Mean \pm SD Median (min - max)	45,X Mean \pm SD Median (min - max)	Non - 45,X Mean \pm SD Median (min - max)	p
Arcus aortae (mm)	16.6 \pm 2.6 17 (10.7-21.4)	16.7 \pm 2.5 17 (12.3-20)	16.6 \pm 2.8 16.5 (10.7-21.4)	0.8
Aortic isthmus Z score	0.8 \pm 1.5 0.9 (-2.0-4.0)	1.2 \pm 1.2 0.9 (-0.4-4.0)	0.5 \pm 1.7 0.7 (-2.0-3.9)	0.24
Ascending aorta Z score	0.28 \pm 1.2 0.4 (-1.7-2.8)	0.6 \pm 1.1 0.6 (-1.7-2.2)	0.01 \pm 1.3 -0.2 (-1.7-2.8)	0.13
Descending aorta Z score	-0.2 \pm 1.2 -0.4 (-1.9-2.6)	0.1 \pm 1.1 -0.3 (-1.6-2.6)	-0.5 \pm 1.1 -0.7 (-1.9-1.9)	0.16
Sinotubular junction Z score	2.4 \pm 1.5 2.6 (0.3-5.7)	2.5 \pm 1.5 2.9 (0.3-4.3)	2.3 \pm 1.7 2.1 (0.5-5.7)	0.78
ASI	1.6 \pm 0.3 1.5 (1.2-2.4)	1.7 \pm 0.3 1.6 (1.2-2.2)	1.5 \pm 0.3 1.4 (1.2-2.4)	0.036

Conclusion:

- Our findings indicate that patients with TS should be evaluated with MRI studies in addition to ECHO to reveal all cardiac and vascular anomalies.
- The increase in ASI observed in 45,X patients may herald the development aortic dissection. Therefore, frequent follow-up is warranted in these patients.

