

Unusual case of combination of Beckwith-Wiedemann Syndrome and SHOX gene deficiency

Gilda Cassano¹, Sara Osimani¹, Roberta Pajno¹, Marco Pitea¹, Cristina Partenope¹, Silvia Russo², Gabriella Pozzobon¹

¹Department of Pediatrics, San Raffaele Scientific Institute, Milan, Italy. ²Laboratory of Endocrine and Metabolic Research, IRCCS Istituto Auxologico Italiano, Milan, Italy

Background

Beckwith Wiedemann Syndrome (BWS) is an overgrowth disorder involving a predisposition to tumor development, etiologically connected with genetic/epigenetic dysregulation.

The main features of BWS include omphalocele, macroglossia and macrosomia; however there is significant clinical heterogeneity.

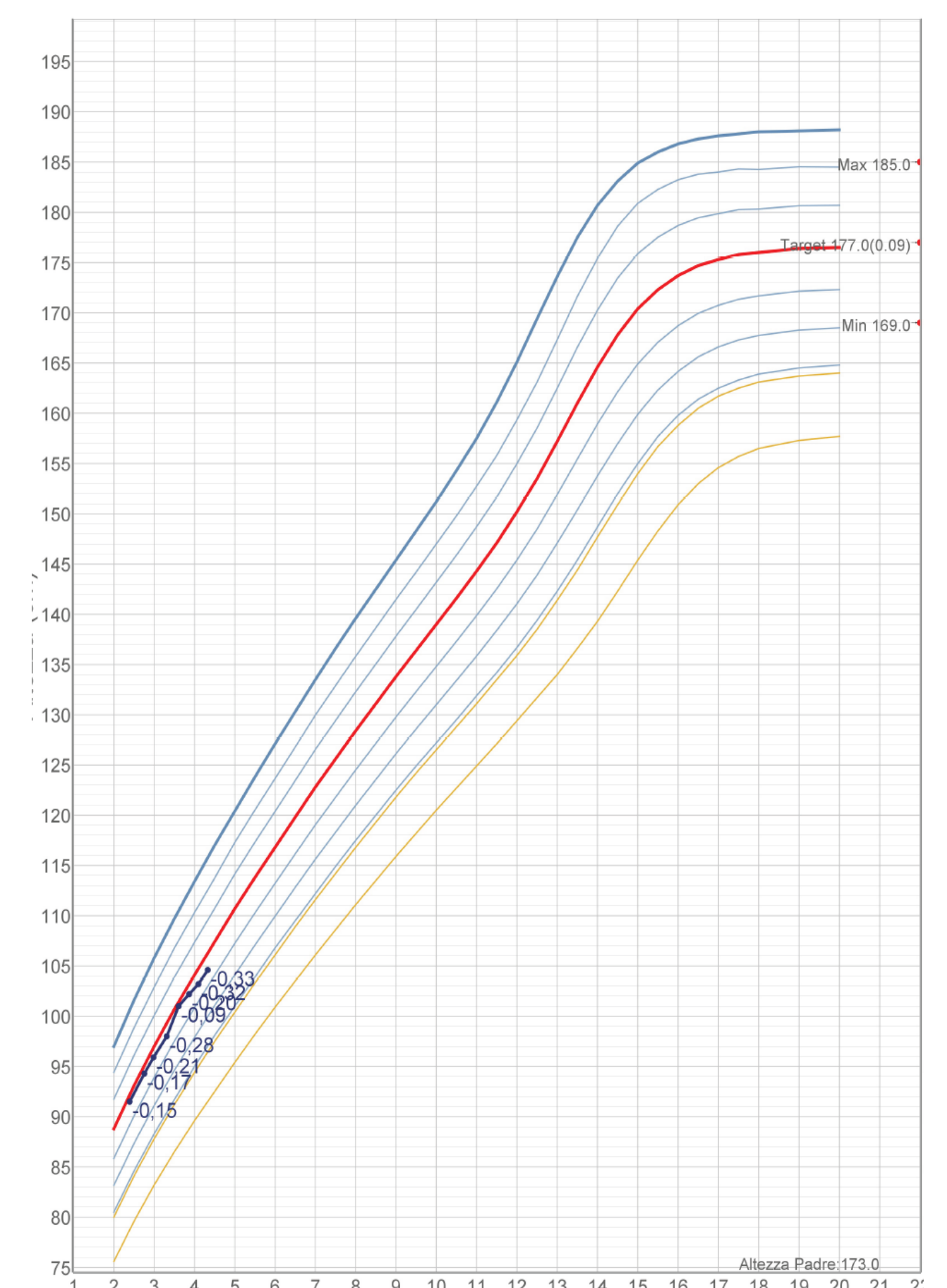
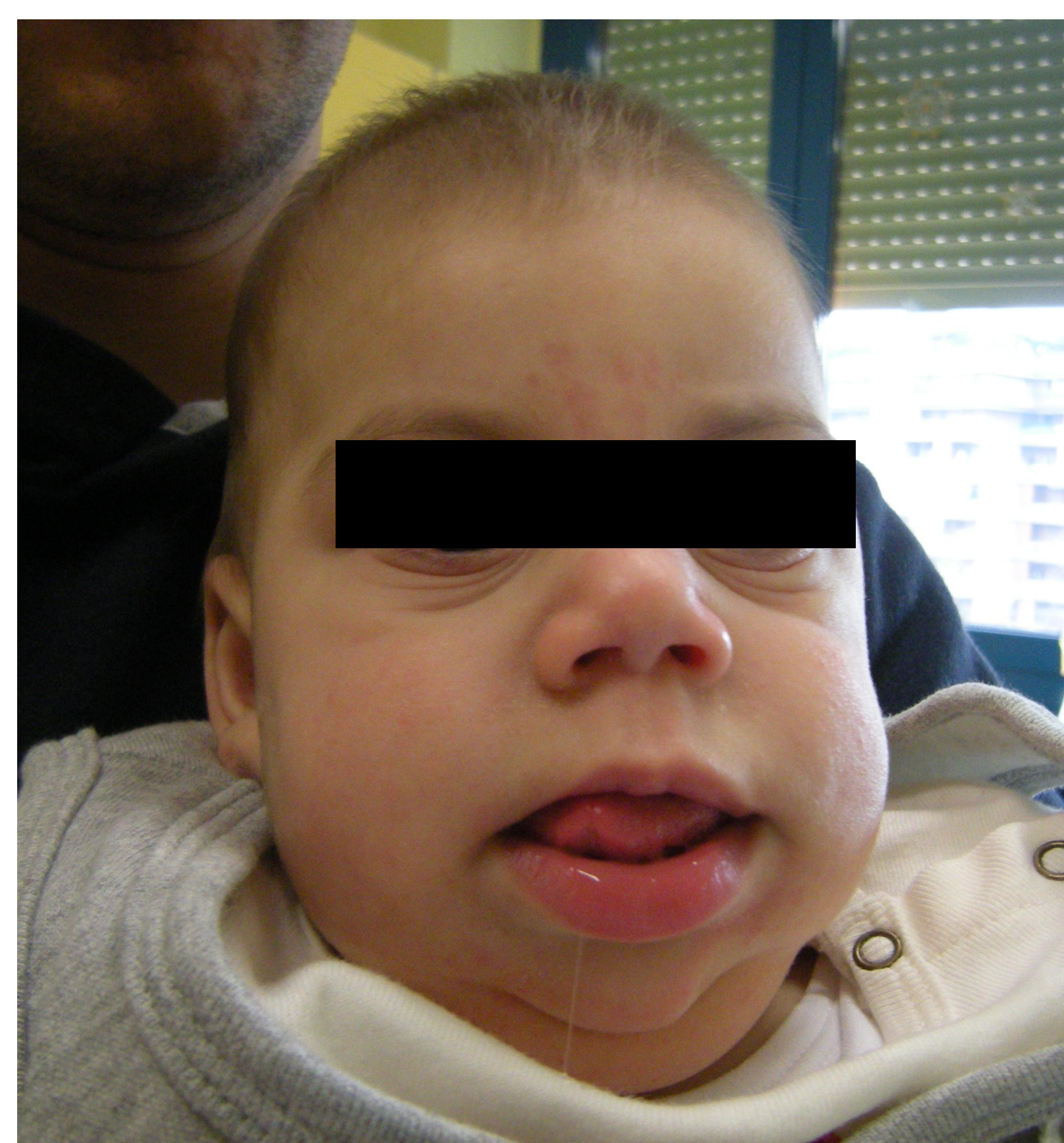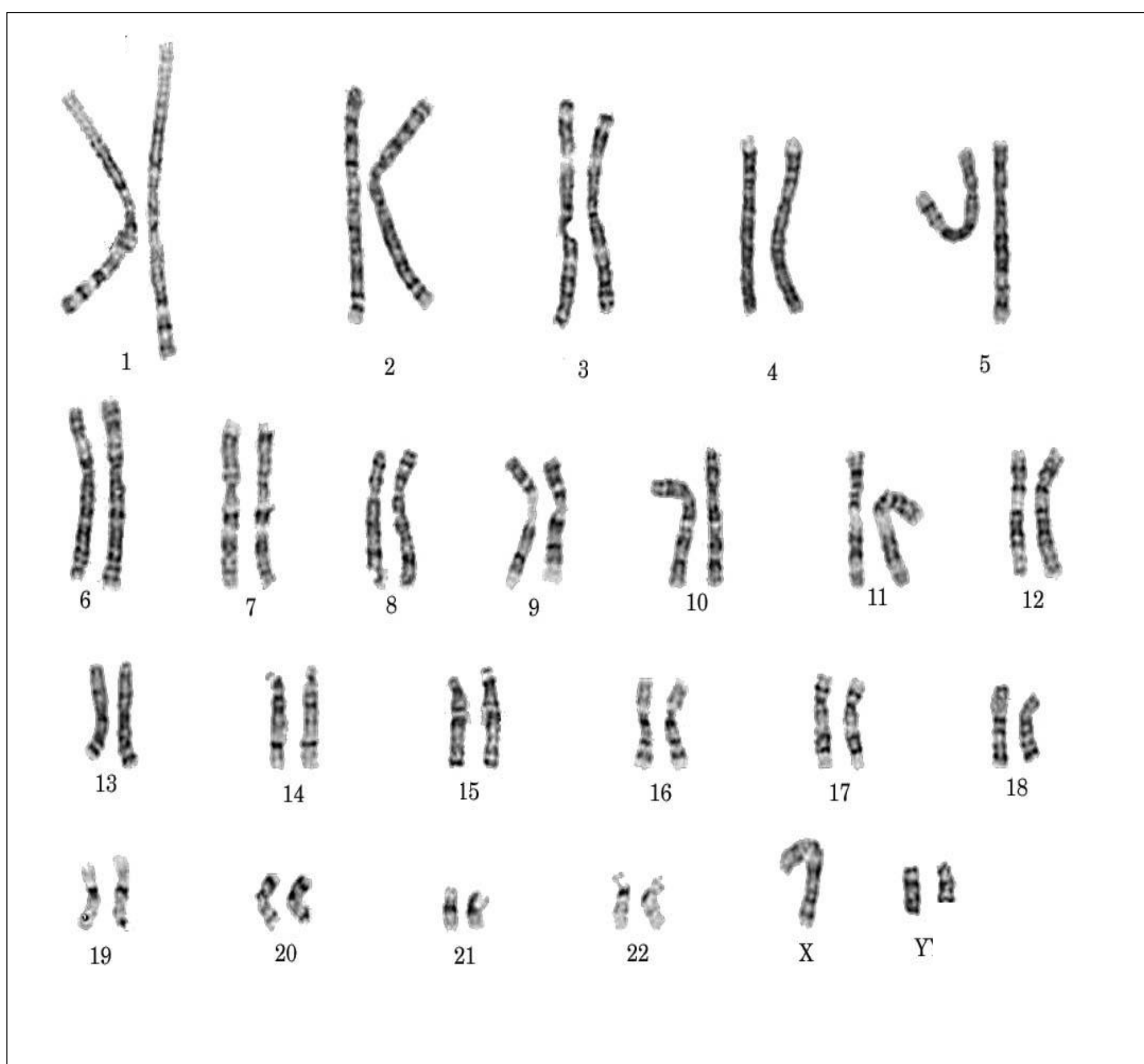
SHOX mutation is a frequent cause of short stature with high penetrance, but extremely variable clinical expression. The mean adult height is -2.2 SDS. The presence of mesomelia, minor auxological abnormalities and radiographic sign are important keys to the diagnosis which has to be confirmed by genetic analysis. GH therapy was approved for individuals with SHOX mutation with benefit on the final stature.

G.D. ♂

Male patient, with history of neonatal macrosomia and hypoglycemia.

Clinical examination revealed macroglossia and ear pits, in the absence of hemipertrophy.

Genetic diagnosis of BWS was performed using MLPA followed by molecular genetic tests. They showed a gain of methylation in IC1 region caused by paternal uniparental disomy of a chromosomal segment including the 11p15.5 region. The double paternal content is due to de novo unbalanced translocation t(Y, 11); so there is a supernumerary 11p15.5 region located on the short arm of the Y instead of the subtelomeric region which is lost. Analysis of Yp deletion has allowed to identify the lack of the whole SHOX gene and the area upstream SHOX. Deletion in this area can be associated to short stature and Leri-Weill Syndrome



CONCLUSIONS

An unusual clinical case: combination of BWS, an overgrowth syndrome, with SHOX deletion, a condition associated to growth failure. At present time the growth is adequate; so, taking into account the high tumor risk related to BWS, there is not indication to GH therapy. It is important to keep in mind that the SHOX deficiency becomes more pronounced with age while the cancer risk related to BWS decreases with the age. So a careful long-time auxological follow up is necessary and the balance of the risks and benefits associated with GH therapy should be evaluated step by step.