

KBG syndrome: our experience and unreported clinical features



Scarano E¹, Tassone M¹, Tamburrino F¹, Graziano C², Perri A¹, Stefanelli F¹, Vestrucci B¹, Mazzanti L¹.

¹Rare Disease Unit, Department of Pediatrics, University of Bologna, St. Orsola-Malpighi Hospital, University of Bologna, Bologna, Italy
²Unit of Medical Genetics, Department of Medical and Surgical Sciences, St. Orsola-Malpighi Hospital, University of Bologna, Bologna, Italy



The authors have no affiliation, financial agreements or other involvement with companies or organizations with financial interest in childhood

Background

KBG syndrome is an AD disorder caused by mutations in the ANKRD11 gene or deletions of 16q24.3, characterized by developmental delay, short stature, dysmorphic facial features and skeletal abnormalities.

Clinically, KBG syndrome has been identified as an under-diagnosed condition because its clinical features can be mild and unspecific

Clinical Report

We report 22 patients, 15 males and 7 females, where a clinical diagnosis of KBG was suspected.

Nine patients showed a point mutation in ANKRD11 and three carried a 16q24.3 deletion. Age at diagnosis: 4-21 yrs. One female patient showed clinical signs of Cornelia de Lange molecularly excluded before ANKRD11 analysis.

ANKRD11 defects resulted de novo in 10 families (three 16q24.3 deletions and seven point mutations) and familial in one female patient (the mutation was transmitted by the mother who presented a milder phenotype).

All KBG patients presented typical facial dysmorphisms and macrodontia. The most specific facial features included the shape of the nose and mouth: a prominent nose with a high nasal bridge, a wide nasal base, and a bulbous tip with thick alae nasi and anteverted nares. (Fig 1).

Skeletal abnormalities were constant and the majority of patients (11/12) showed joint stiffness.

Two patients had hematological abnormalities.




Fig. 1

Three patients required GH treatment with a significant increase of height velocity and 2 of these showed GH-deficit (Fig. 2).

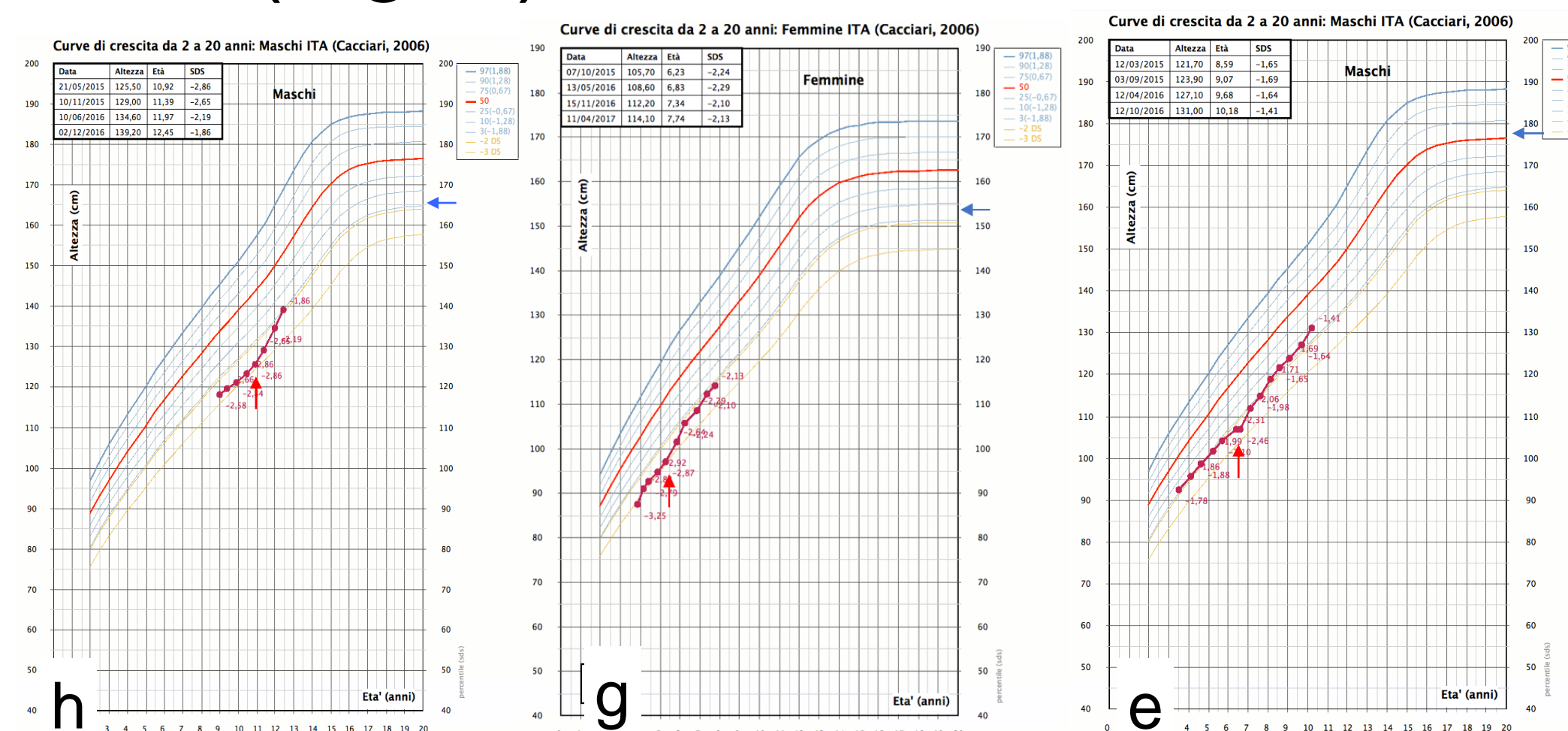


Fig. 2

Cerebral structural abnormalities were seen in height patients (enlarged cisterna magna, arachnoid and, leptomeningeal cysts, Dandy Walker complex and Chiari malformation).

Developmental delay was reported in 83.3% patients and all patients showed behavioral abnormalities.




Fig 3

Molecular analysis for KBG was negative in 10 patients (Fig.3).

Retrospectively, patients with negative genetic results had less typical clinical features.

One patient from the Philippines (p) showed an ANKRD11 missense variant (c.6868C>T; p.Pro2290Ser) which is frequent in the East Asian population).

One patient had a causative RAD21 mutation (the same mutation was later found in the father who presented a milder phenotype) and another one had a large (17.75 Mb) de novo duplication of 12.q21.1-q21.33.

Conclusions

KBG syndrome is an highly recognizable condition.

Genetic analysis of ANKRD11 can easily reach a detection rate higher than 50% thanks to clinical phenotyping.

Joint stiffness was not reported previously but seems to be common and can be helpful for the diagnosis.

Hematological abnormalities could be present and warrant a specific follow-up. Clinical overlap between KBG and cohesinopathies as been present.

An early diagnosis is critical because patients can benefit from interventions for behavioral issues and from consideration of growth hormone therapy for short stature.

Overall, the prognosis is fairly good with appropriate management, ID is often mild, and two adult patients that are in follow-up at our Institution lead an autonomous life.

References

- Herrmann J et al. Birth Defects Orig Art Ser. 11:7-18 (1975)
- Goldenberg A et al. Am J Med Genet 170:2847-2859 (2016).
- Low K et al. Am J Med Genet 170:2835-2846 (2016).

