

# A Novel Variant of Fanconi-Bickel syndrome : A 19 years Old Female with Diabetes Mellitus, A Therapeutic Conundrum

Sanaa Sharari<sup>1</sup>, Sara Al-Khawaga<sup>1</sup>, Reem Hasnah<sup>1</sup>, Saras Saraswathi<sup>1</sup>, Basma Haris<sup>1</sup>, Amira Saeed<sup>1</sup>, Faiyaz Ahmad<sup>1</sup>, Idris Mohammed<sup>1</sup>, Shihab Mundeckadan<sup>1</sup>, Khalid Hussain<sup>1</sup>

<sup>1</sup>Department of Pediatric Medicine, Division of Endocrinology, Sidra Medicine, Doha, Qatar.  
E-mail: Khussain@sidra.org

Disclosure-None of the authors have any potential conflict of interest

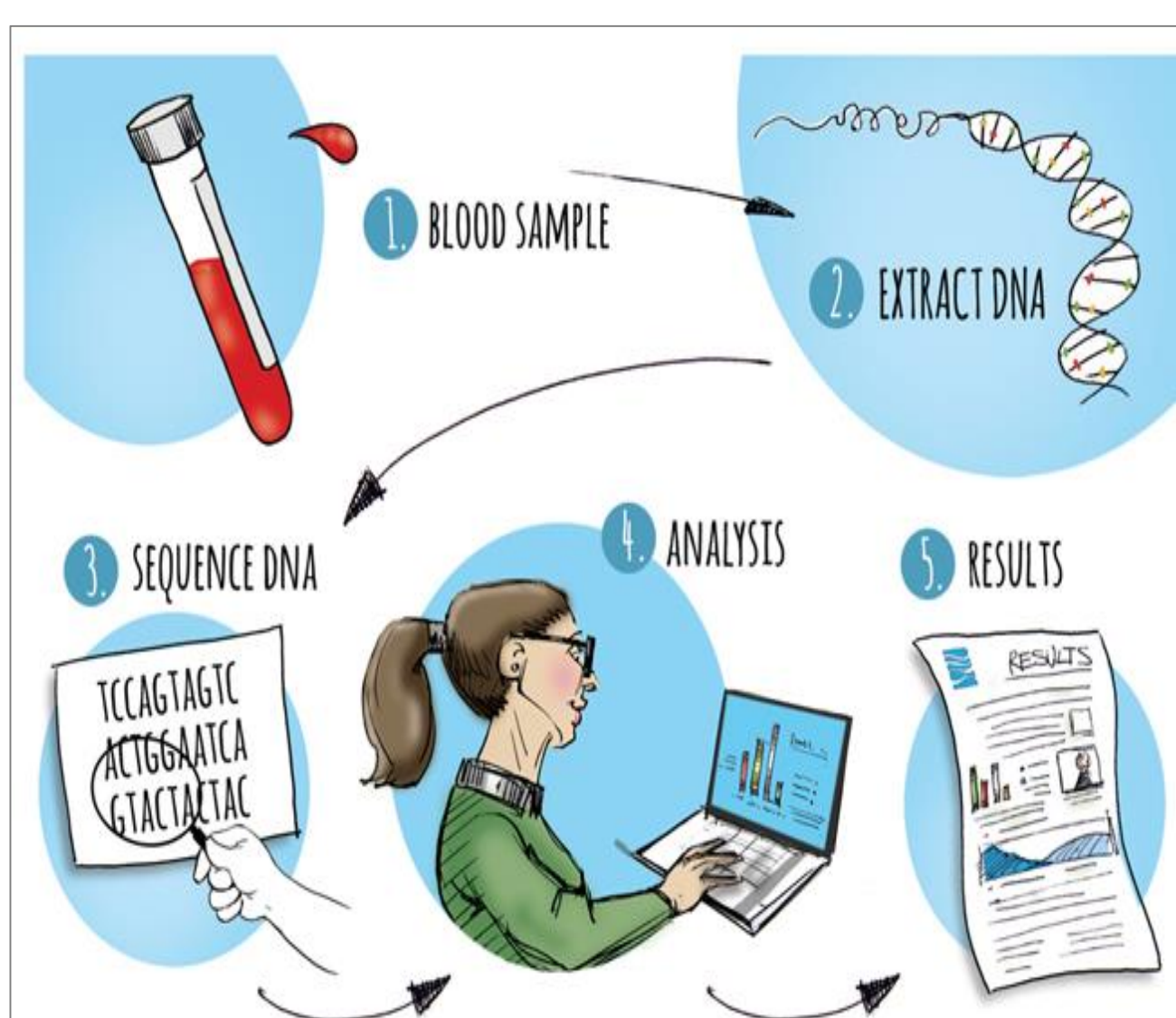
## Introduction

Fanconi Bickel syndrome (FBS) is a rare form of glycogen storage disease (GSD) inherited in an autosomal recessive manner. FBS is caused by mutations in the glucose and galactose transporter gene *SLC2A2*. The *SLC2A2* gene encodes for *GLUT2*, low affinity facilitative glucose transporter expressed in critical tissues involved in glucose homeostasis. This gene is expressed in hepatocytes, pancreatic  $\beta$ -cells, enterocytes, and renal tubular cells. Clinical and chemical features include fasting hypoglycemia, postprandial hyperglycemia, hepatomegaly, glucose and galactose intolerance, partial resistance to adrenaline and glucagon, rickets, and poor growth. Missense, nonsense, frameshift, and splice site pathogenic variants have all been identified throughout the *SLC2A2* gene in association with FBS, with homozygosity present in a large number of cases. Herein, we report a novel variant in the *SLC2A2* gene in a female patient with classical features of FBS associated with diabetes mellitus at Qatar.

## Methods

Whole Exome Sequencing (WES): Using genomic DNA from the patient, the exonic region and flanking splice junctions of the genome were captured and sequenced by NetGen sequencing on an Illumina system. Sequence and copy number alterations were reported according to the Human Genome Variation Society (HGVS) and International System for Human Cytogenetic Nomenclature (ISCN) guideline, respectively.

Sanger sequencing analysis was also performed for this patient. Target DNA was amplified by using Veriti 96-well Fast Thermal Cycler, making fragments of different lengths and were cleaned using enzymatic cleanup, ExoSAP. Fluorescent "chain terminator" nucleotides mark the ends of the fragments and permit the sequence to be detected during running in Veriti 96-Well Fast Thermal Cycler. Precipitation method is used to remove unincorporated Dye terminators from BigDye Terminator cycle sequencing reactions. Finally, the data were analyzed by two software; Applied Biosystems Sequencing Analysis Software v6.0 and Applied Biosystems SeqScape Software v3.



## Case Report

We report a case of 19 years old FBS female patient associated with diabetes mellitus in Qatar, the second child of a first degree-cousin parents, who has presented with classical features of Fanconi-Bickel Syndrome (Figure 1). The patient presented with renal tubular acidosis, recurrent spontaneous pathological fractures and short stature. The patient suffers from thoracolumbar scoliosis and has multiple deformities in the upper and lower limbs (Figure 2), leading to non ambulation. Fasting hypoglycemia and postprandial hyperglycemia were detected. Urine analysis was significant for phosphaturia and evidence of proximal renal tubular acidosis (RTA) was noted (generalized aminoaciduria- Table 1). She was diagnosed with diabetes mellitus at the age of 17 years and is currently on insulin Aspart, Glargine, and Sitagliptin, maintaining a HbA1C of 6.8-7%. Basal insulin level was within normal range, whereas C-Peptide of insulin was reduced (0.68 ng/ml, normal range 0.78-5.19).

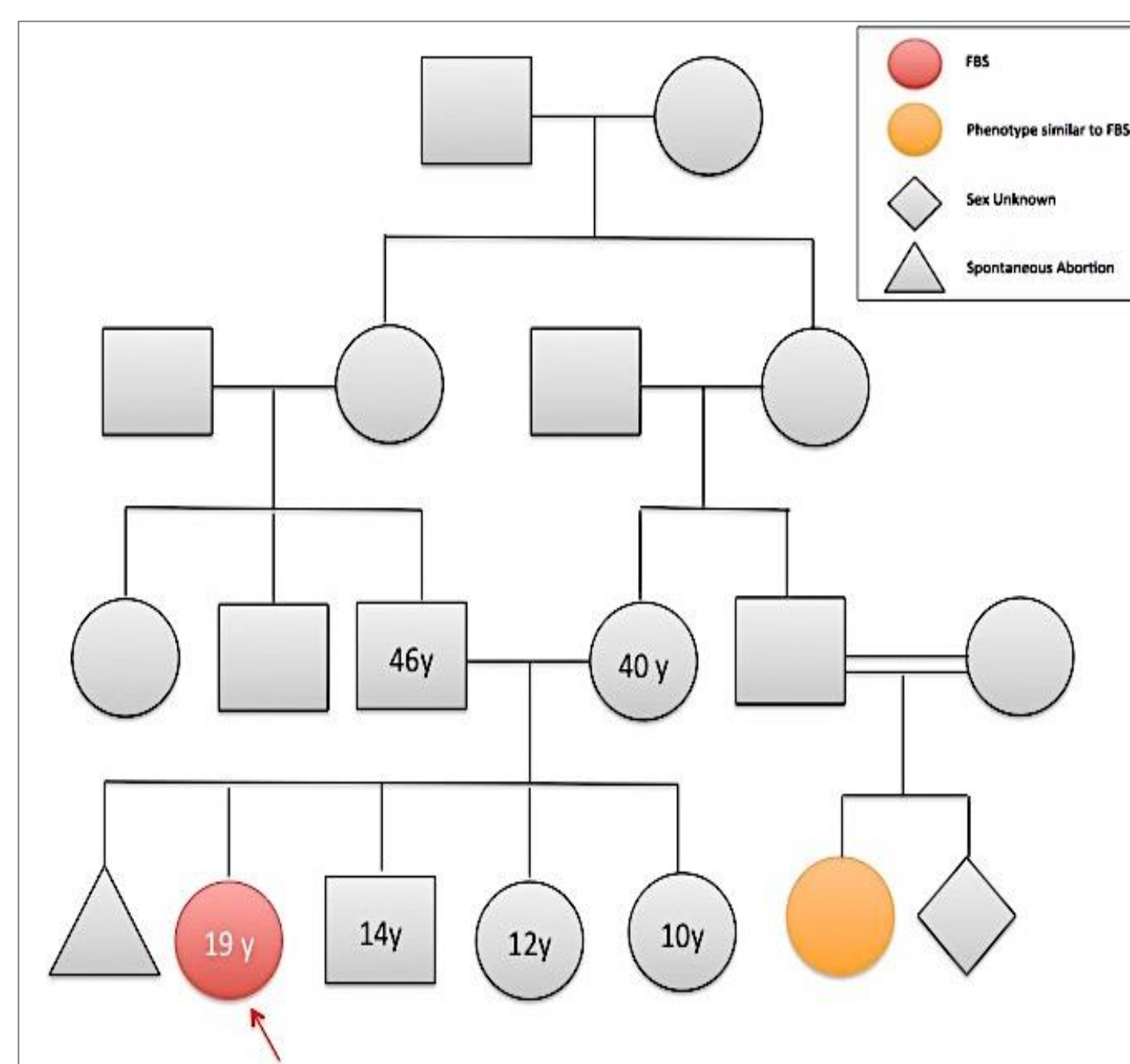


Figure 1. The patient's family pedigree is significant for consanguinity and a similar phenotype was observed in a first degree female cousin.

Table 1. Summary of lab investigations at time of diagnosis

Investigation	Patient with FBS	Reference range
Serum phosphorus (mmol/L)	0.43	0.93-1.64
Serum calcium (mmol/L)	2.15	2.27-2.62
Alkaline phosphatase (U/L)	1108	48-95
Alanine amino transferase (ALT) (U/L)	56	8-22
Aspartate transaminase (AST) (U/L)	74	0-30
Oral Glucose Tolerance Test (GTT 2 Hours)		
Fasting glucose (mmol/l)	4.5	6.1-6.9
2 hours glucose tolerance (mmol/l)	28.2	7.8-11.1
Acid Base Status Blood Gas Profile		
PH	7.3	7.35-7.45
HCO <sub>3</sub> (mmol/l)	12.2	21-28
BE (mmol/l)	-12.2	-2-3
Anion Gap (mmol/L)	7.3 (Non-anion gap Acidosis)	<18
Urinalysis		
Amino Acids	Generalized Aminoaciduria ++	-
Lipid Profile		
Cholesterol (mmol/l)	6.53	Borderline-High (5.17-6.18)
Triglycerides (mmol/l)	1.02	Normal <1.7
High Density Lipoprotein (HDL-C) (mmol/l)	1.35	<1.0 Low
LDL (mmol/l)	4.72	Borderline (3.36-4.11)

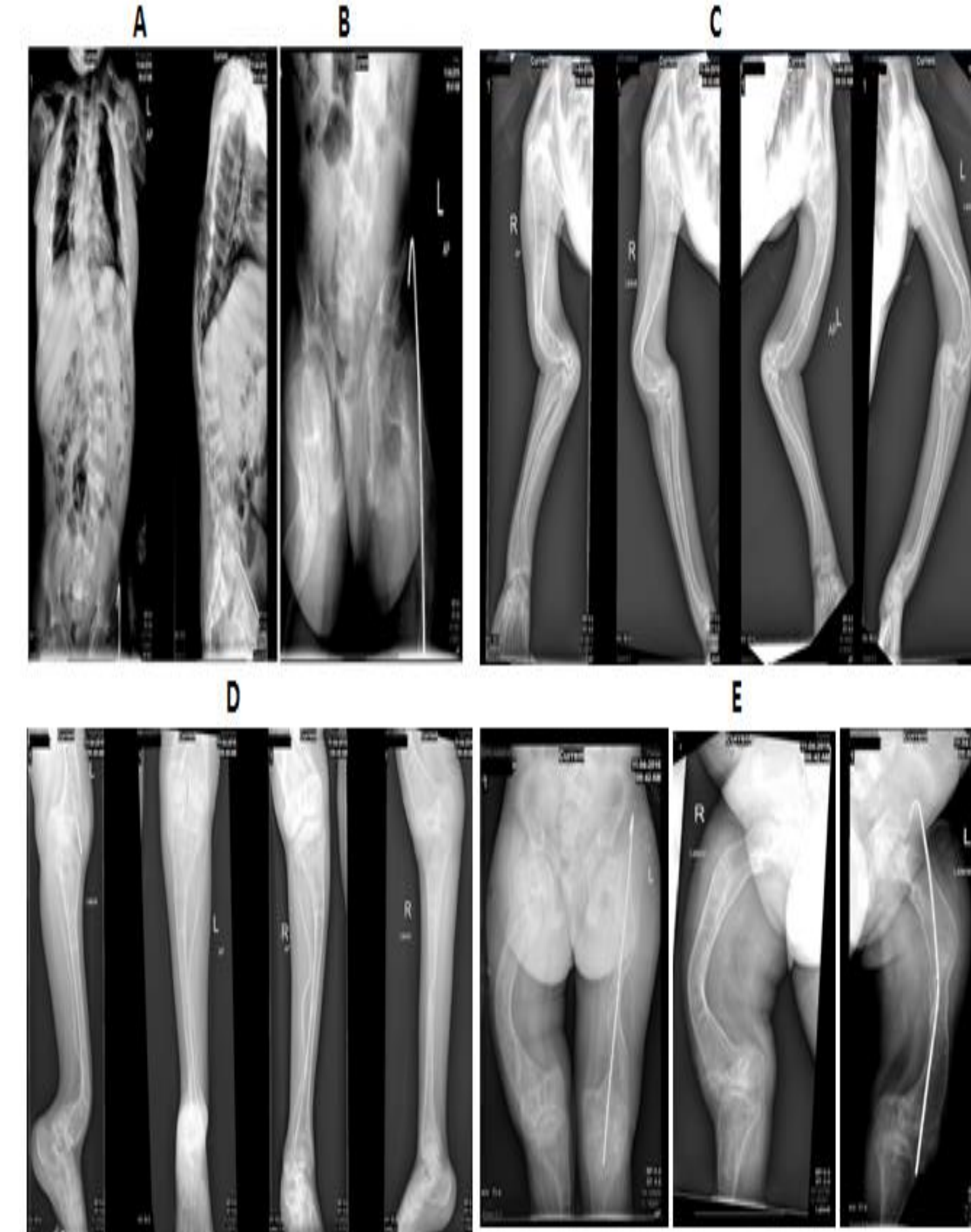


Figure 2. Marked reduction in bone density showing accentuated trabeculation and cortical thinning A) Moderate thoracolumbar scoliosis with convexity towards the right at the mid thoracic region and to the left at the lumbar region associated with rotation of the thoracic and lumbar vertebrae. B) pelvis. C) left Humerus shows multiple fractures with deformity noted near the elbow joint with distal forearm bone deformity noted. D) Tibia/Fibula reduced bone density and softening of the bones with marked deformity and bowing bilaterally. E) Right femoral bone deformity with bowing, status post left internal fixation with intramedullary nail.

## Results

Whole Exome Sequencing showed c.613-7T>G: IVS5-7T>G in intron 5 in the *SLC2A2* gene. The variant reported in the patient has not been reported previously as a pathogenic nor a benign variant. This variant reduces the quality of the splice acceptor site in intron 5 and creates a new cryptic splice acceptor site upstream of the natural splice site (Table 2).

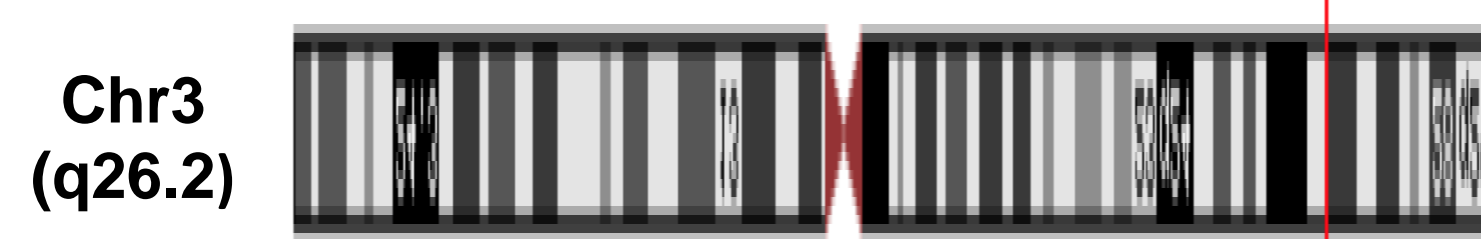


Table 2. Summary of identified splice site mutations within *SLC2A2* gene

Variation	Gene(s)	Condition(s)	Clinical significance
c.613-7T>G	<i>SLC2A2</i>	Fanconi- Bickel Syndrome	Novel variant of uncertain significance
c.963+1G>A	<i>SLC2A2</i>	Diabetes Mellitus Type 2	Pathogenic

This is a newly reported homozygous mutation (c.613-7T>G: IVS5-7T>G in intron 5 of the *SLC2A2* gene), confirmed by Sanger sequencing using the amplified DNA samples from the patient (Figure 3).

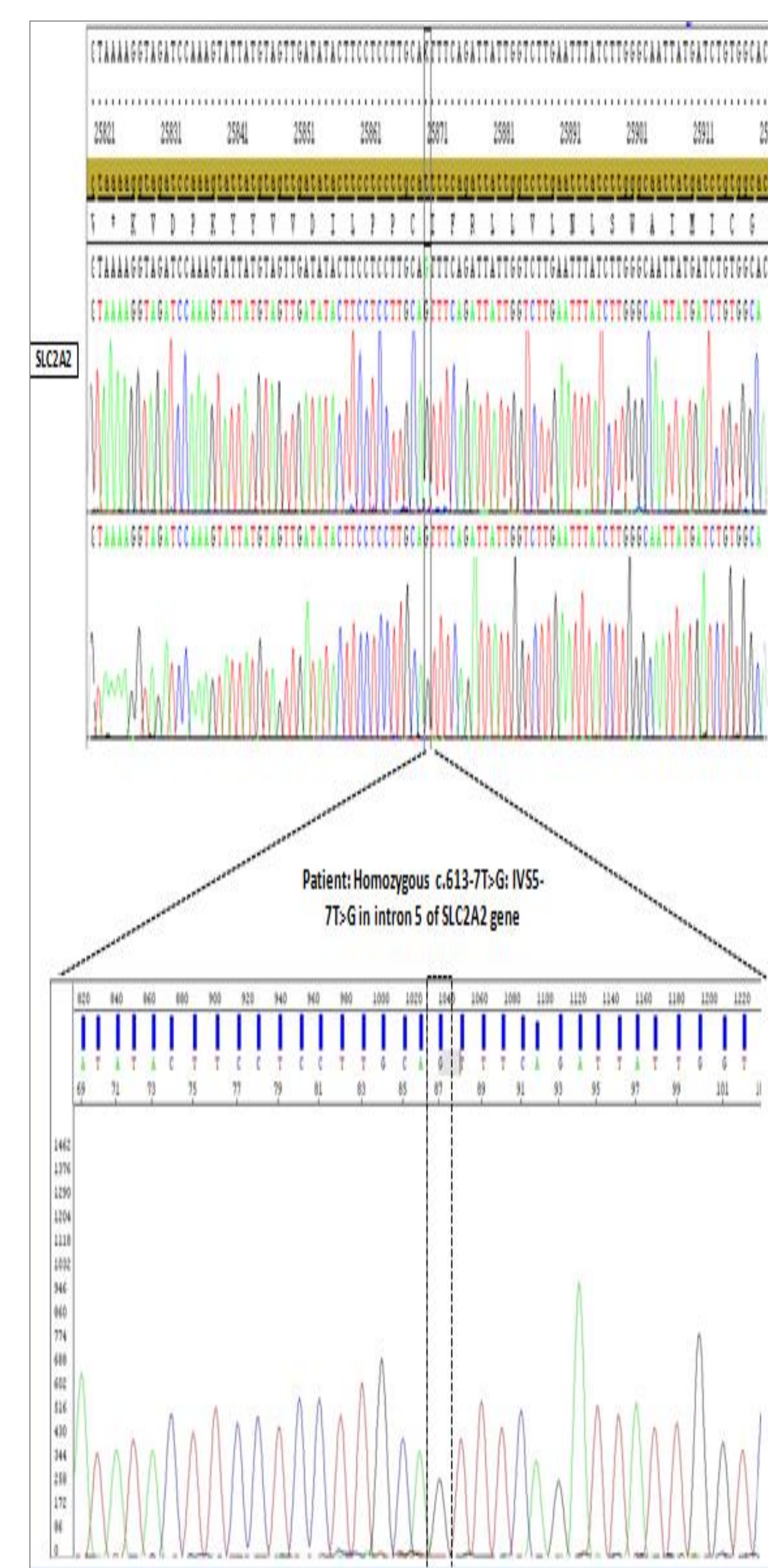


Figure 3: Sanger sequencing of the patient DNA sample showing mutation at c.613-7T>G: IVS5-7T>G in intron 5 site.

## Conclusion

The c.613-7T>G variant was not observed in approximately 6,500 individuals of European and African American ancestry in the NHLBI Exome Sequencing Project, indicating it is not a common benign variant in these populations. Therefore, we report c.613-7T>G as a novel variant. The presence of this variant in the apparently homozygous state may be related to the reported features in this patient. The c.613-7T>G variant is expected to cause abnormal gene splicing; however, in the absence of RNA/functional studies, the actual effect of this sequence change in this patient is unknown. There is currently no targeted therapy for the underlying identified genetic defect; the mainstay of therapy for FBS patients is conservative management. The patient is on insulin, alfacalcidol, phosphate, sitagliptin, sodium bicarbonate and vitamin D. Future directions include validation of the patient RNA sequence and functional studies.

## References

- Michau, A., et al., Mutations in *SLC2A2* gene reveal hGLUT2 function in pancreatic beta cell development. *J Biol Chem*, 2013. 288(43): p. 31080-92.
- Hughes, S.D., et al., Transfection of AtT-20ins cells with GLUT-2 but not GLUT-1 confers glucose-stimulated insulin secretion. Relationship to glucose metabolism. *J Biol Chem*, 1993. 268(20): p. 15205-12.
- OMIM #138160