

# A 14-year-old boy with Simpson- Golabi- Behmel syndrome- case report

**P3-P224**

The authors have nothing to disclose.



<sup>1</sup>B.Sawicka, <sup>2</sup> A. Jakubiuk-Tomaszuk, <sup>1</sup>H. Borysewicz- Sańczyk, <sup>1</sup>J. Michalak, <sup>1</sup>K. Stożek, <sup>1</sup>A. Bossowski

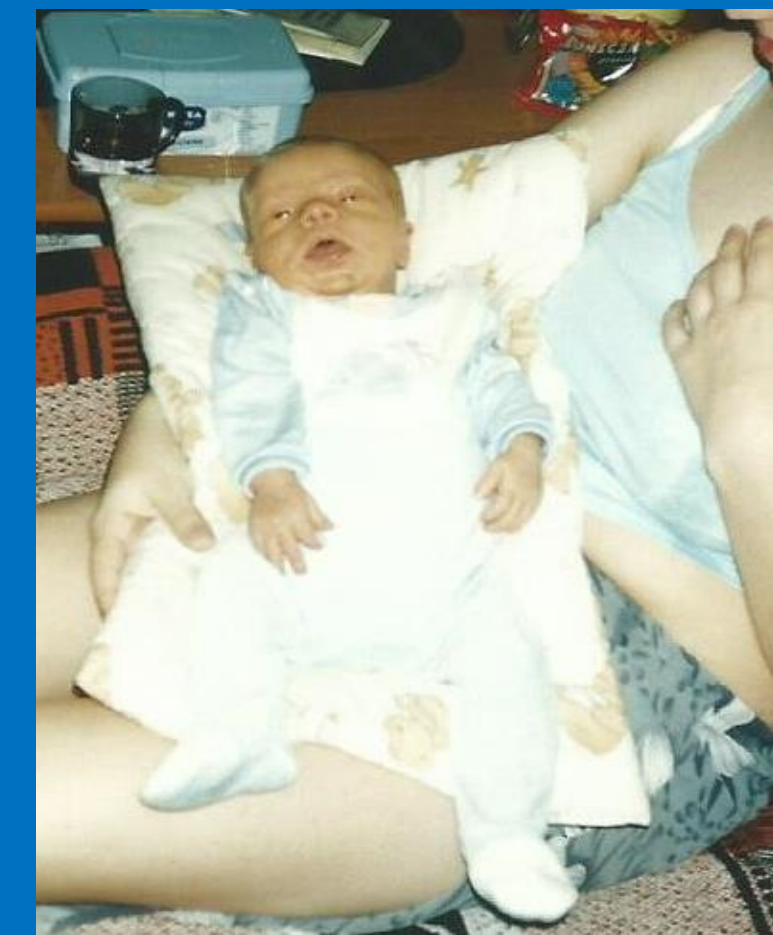<sup>1</sup>Department of Pediatrics, Endocrinology, Diabetology with Cardiology Division, Medical University in Białystok, Poland

<sup>2</sup> Department of Paediatric Neurology and Rehabilitation. Medical University in Białystok. Poland.



## Background

Simpson-Golabi-Behmel syndrome is a condition which classified as an overgrowth syndrome and affects many parts of the body and occurs primarily in males. Infants have macrosomia at birth and continue to grow and gain weight at an unusual rate. The incidence of Simpson-Golabi-Behmel syndrome is unknown. Mutations in the GPC3 gene are the most common cause of Simpson-Golabi-Behmel syndrome. About 250 people worldwide have been diagnosed with this disorder. About 10 percent of people with Simpson-Golabi-Behmel syndrome develop tumors in early childhood, especially Wilms tumor and neuroblastoma

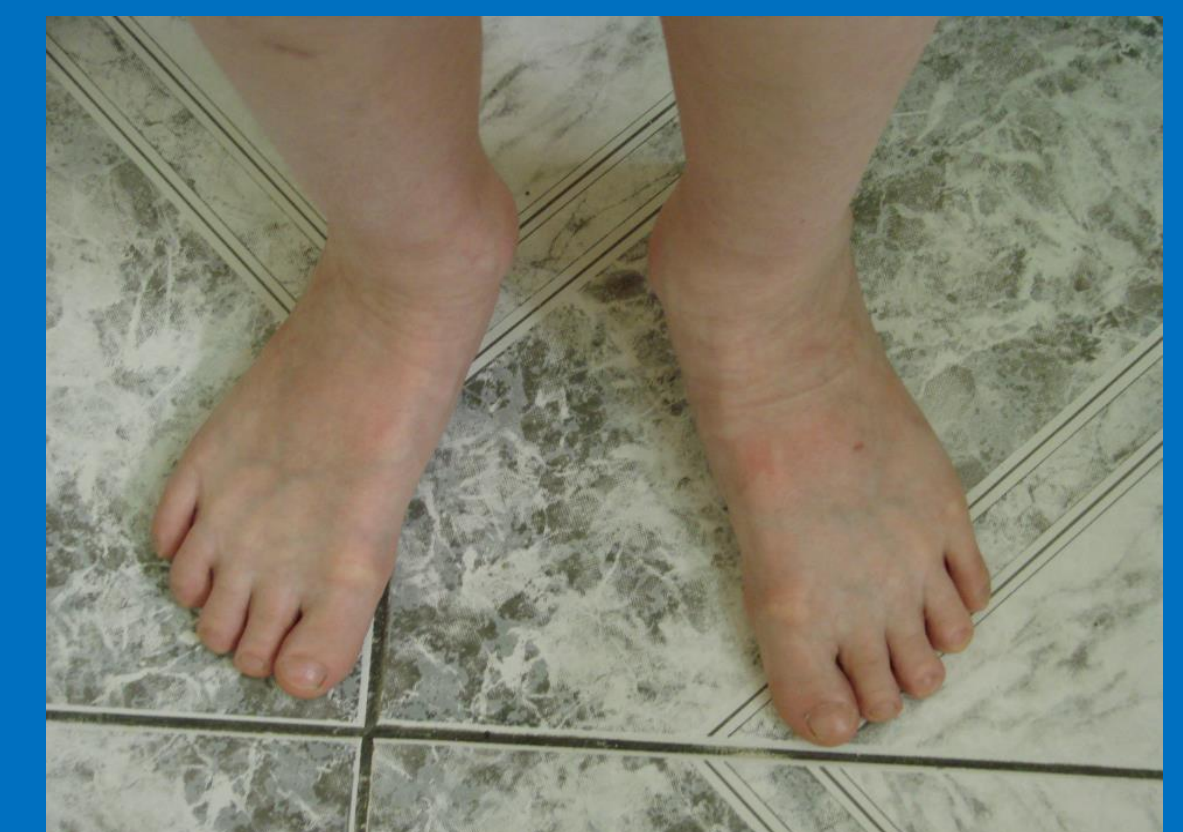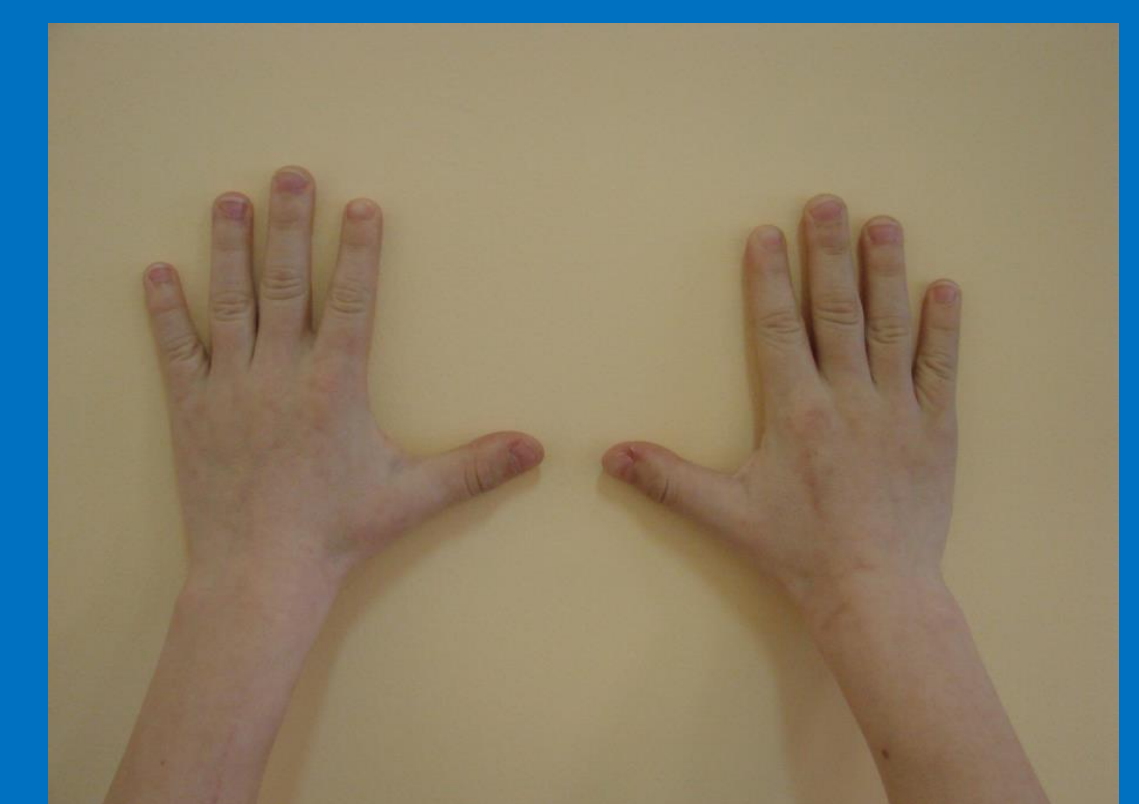

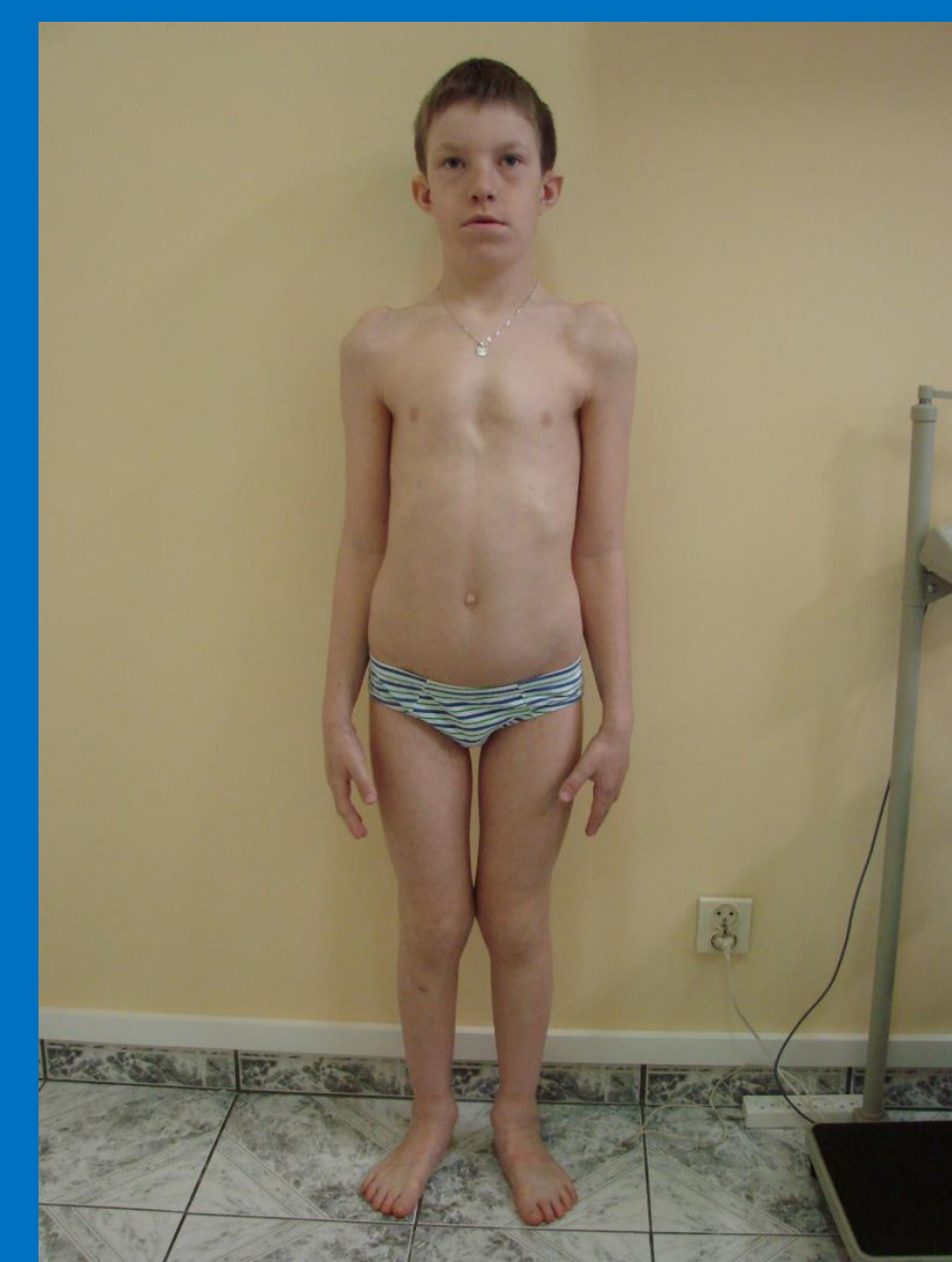
Male neonate with Simpson-Golabi-Behmel syndrome

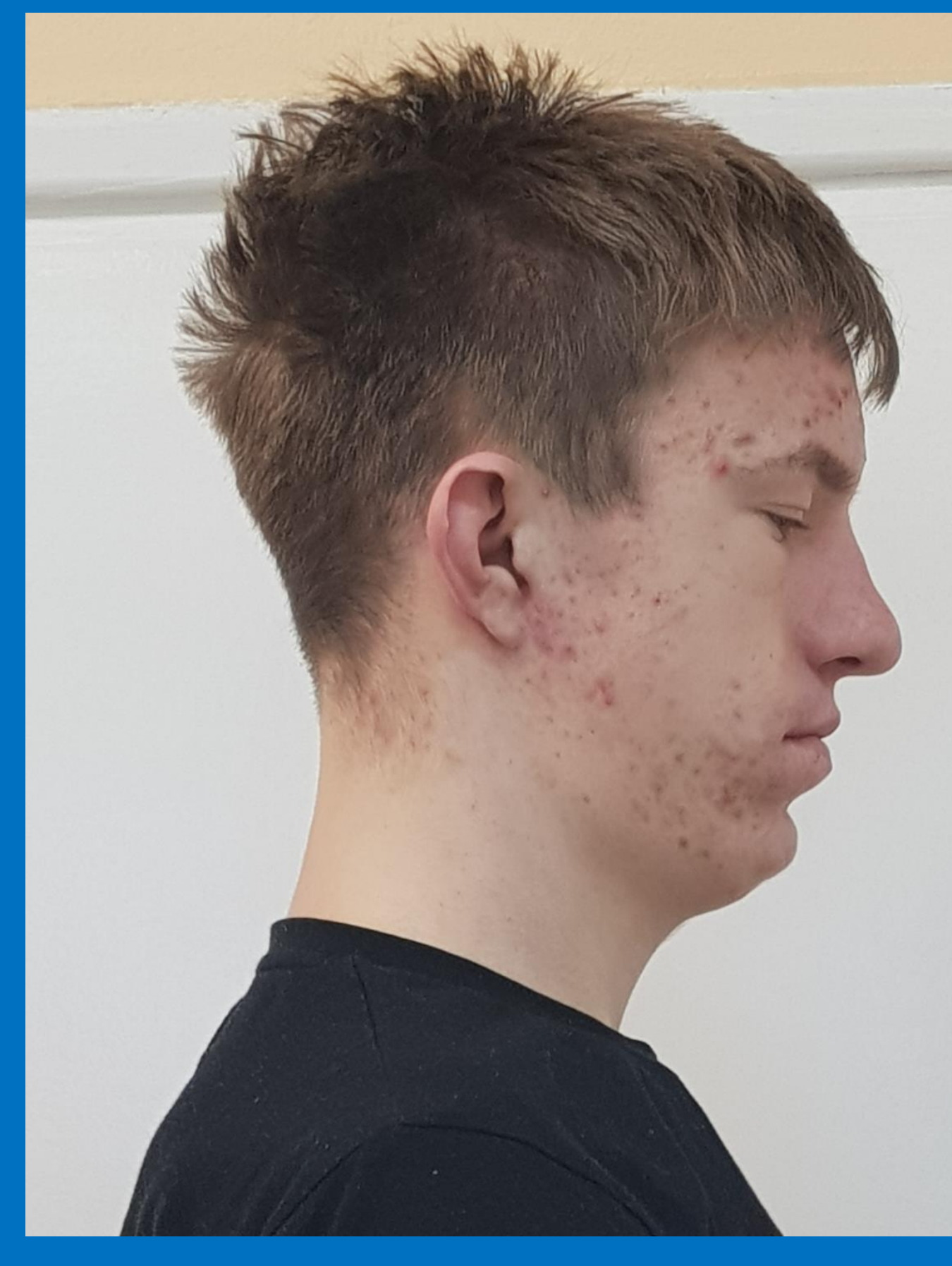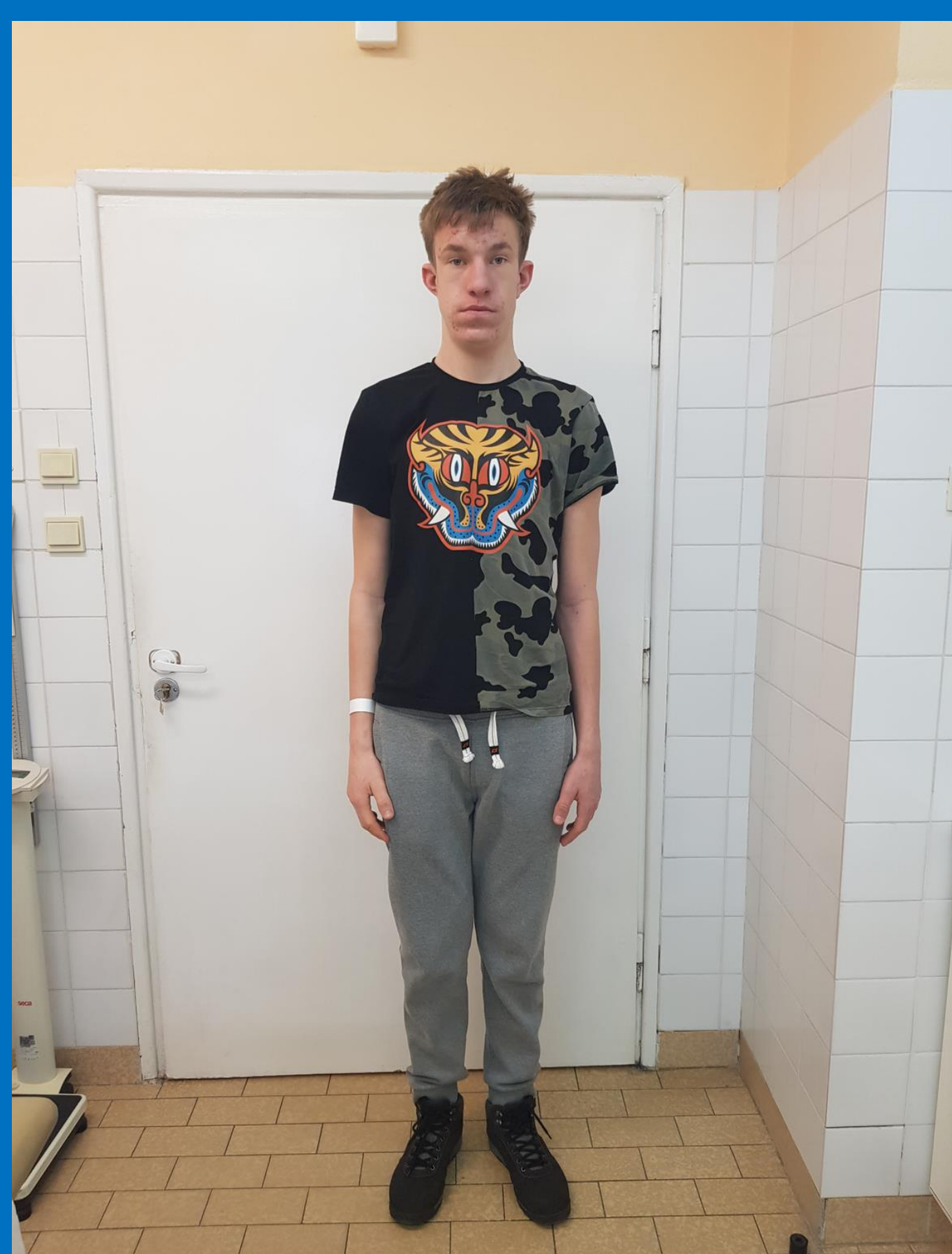## Case report

We present a 14-year boy, who was diagnosed in our Department because of overgrowth, and we observed clinical signs and symptoms of Simpson-Golabi-Behmel syndrome.

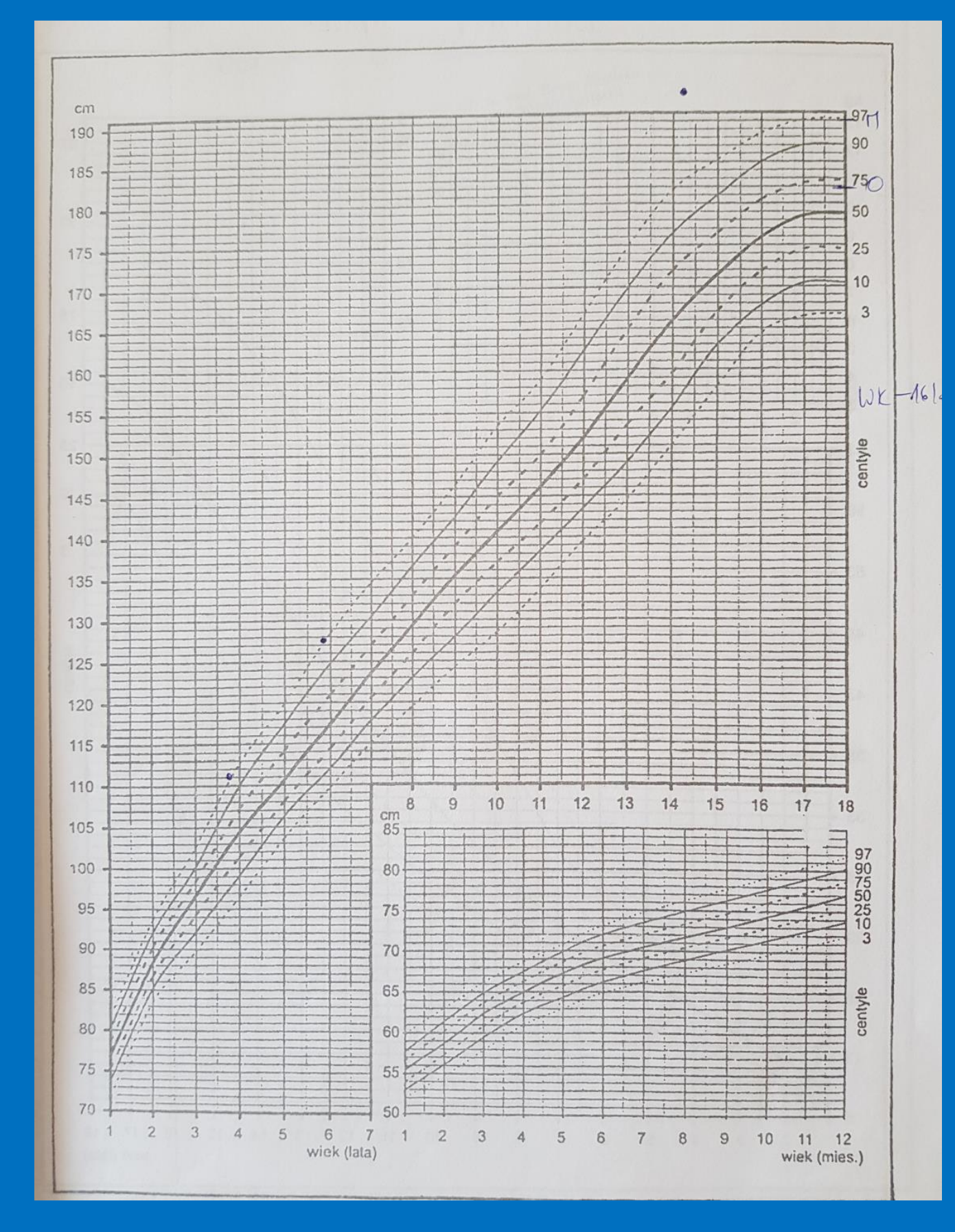
A 4380-gram male neonate in a good condition was born at term to a mother without diabetes. From birth his weight and height were greater than 90th percentile, but during development he had mental retardation. The boy had distinctive coarse facial features, widely spaced eyes (ocular hypertelorism), a large tongue (macroglossia), abnormal ears and abnormalities affecting the roof of the mouth (the palate). Furthermore he had a chest deformation with two extra nipples. Puberty was normal. The bone age was about 16yrs. We excluded pediatric and endocrinological causes connected with overgrowth. The maximum level of growth hormone during OGTT was 0,52ng/ml. IGF-1 level was normal. The karyotype was 46,XY with mutation in the GPC3 gene. During ultrasonography we excluded possible tumors in abdominal cavity.



Boy at 6 years old



Boy at 14 years old



Height chart

## Summary

In conclusion, Simpson-Golabi-Behmel syndrome is a very rare condition connected with overgrowth. We should think about this syndrome when we have the patient with some congenital defects, and it is necessary to distinguish from Beckwith-Widemann syndrome. Tumor follow-up should be performed.

