

Beata Wikiera, Julita Nocoń-Bohusz, Anna Noczyńska

¹Department of Endocrinology and Diabetology for Children and Adolescents, Wrocław Medical University, Chalubińskiego 2, 50-368 Wrocław, Poland

email: beata.wikiera@umed.wroc.pl

Introduction

Silver-Russell syndrome (SRS) is a rare, clinically and genetically heterogeneous condition, and affects one in 100,000 born children. The most well-known genetic mutations in this syndrome are: 11p15 mutation (20–60% patients), and maternal uniparental chromosome 7 disomy (7%–15%). Children with SRS have severely impaired physical growth - intrauterine and after birth. They can be treated with growth hormone (GH).

The aim

To present a very rare case report of a patient with Silver-Russell syndrome and precocious puberty.

Case report

8 years old girl with SRS which manifested symptoms of premature puberty during treatment with growth hormone.

The patient was born at term by caesarean section because of intrauterine growth retardation (IUGR) with fetal distress. Birth weight was 2670 g, length 51 cm, head circumference 30 cm. The pregnancy was not complicated. It was the first child of young healthy parents. (MPH 165 cm, 50 percentile).

At the age of 3.5 short stature was diagnosed: her height was 89 cm (–3 SD) and weight 11.4 kg (–2.5 SD). Physical examination revealed SRS-like somatic features such as: triangular face, relative macrocephaly, micrognathia, subtle body asymmetry with right side hemihypertrophy.

The examination of the thyroid gland, the adrenals and the pituitary gland excluded hormonal dysfunction.

Molecular study for hypomethylation of the H19 region of 11p15.5 chromosome was positive, and confirmed the diagnosis of SRS.

At the age of 4.5 the girl started treatment with GH at the dosis 0.036 mg/kg. The growth velocity accelerated to 9.8 cm/year.

At the age of 7 (height 119 cm, 25 pc, weight 19 kg, 10 pc), breast enlargement (Tanner 2) and estrogenisation of mucous membrane of the external genitalia was noticed.

The laboratory results were as follows: E2 23.9 pg/ml, basal LH 0.232 mIU/ml, basal FSH 2.47 mIU/ml, after GnRHa stimulation: LH 18.3 mIU/ml, FSH 17.7 mIU/ml, TSH 2.89 uIU/ml, FT4 12.9 pmol/l, FT3 8.28 pmol/l.

Bone age was 8 years.

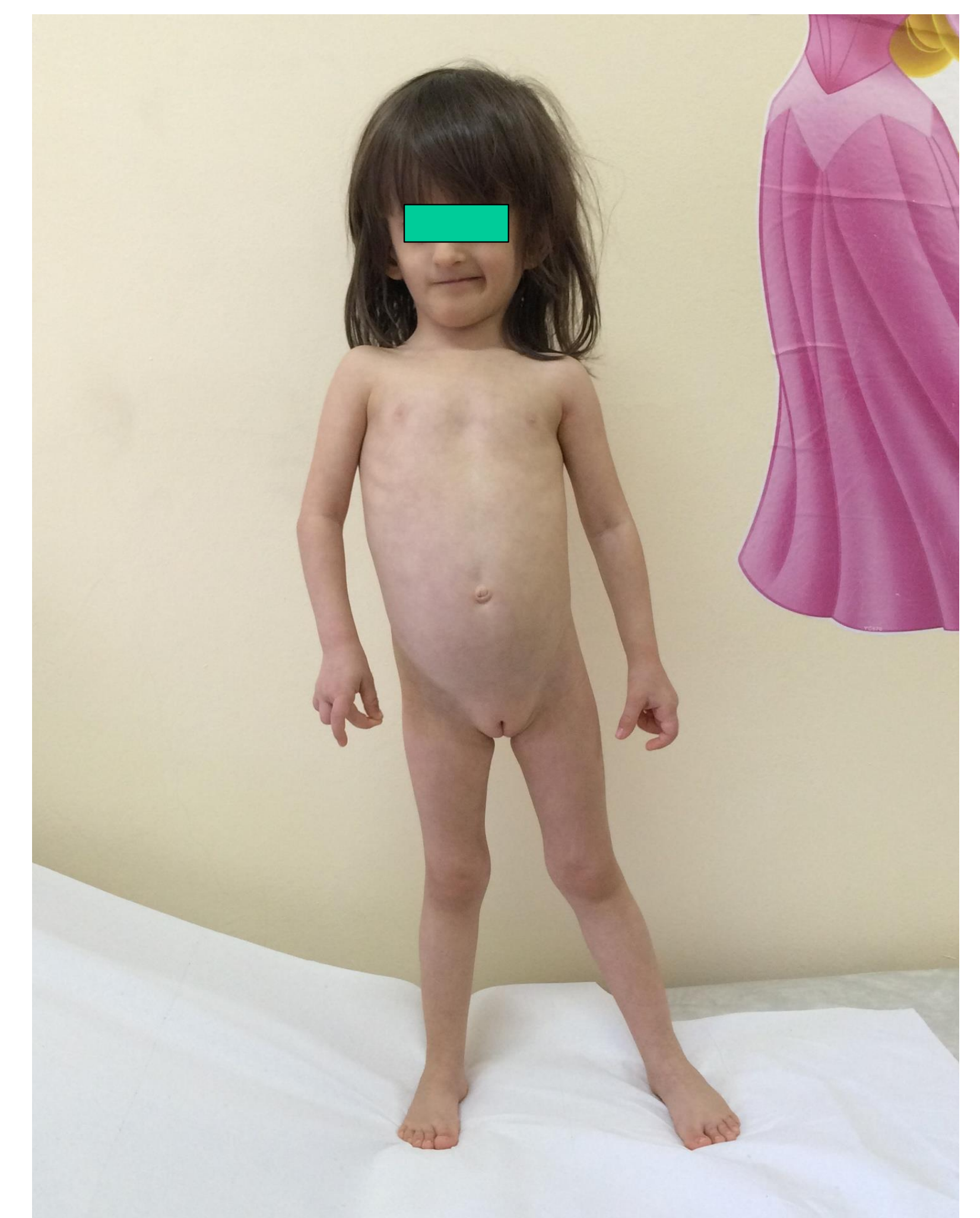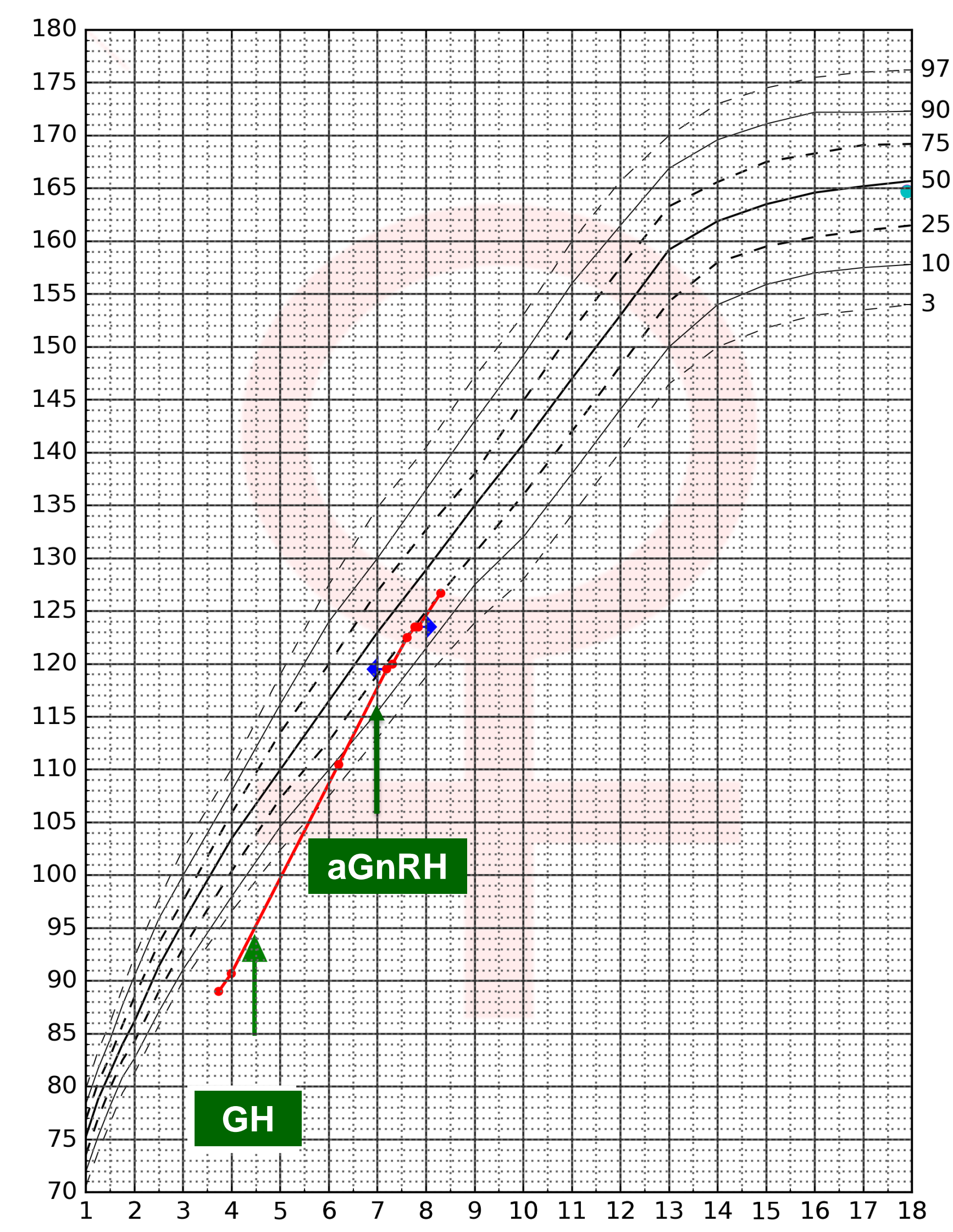
MRI of the pituitary gland was normal.

The girl started combined therapy with GH and GnRHa (3.75 mg every 4 weeks). As the result pubertal signs disappeared, and growth velocity stabilized at the level of 6 cm/year.

Glucagone 0.03 mg/kg	0'	90'	120'	150'	180'
GH (ng/ml)	0.221	18.4	10.8	4.75	1.94

GnRHa	0'	30'	60'	120'
LH (mIU/ml)	0.62	12.4	15.1	18.3
FSH (mIU/ml)	6.67	9.91	11.9	17.7

Growth chart



Conclusion

Acceleration of growth velocity during growth hormone treatment can be augmented by premature puberty in patients with SRS.