

GH treatment in Kabuki syndrome: a case report

Elisa Guidoni, Federica Lotti, Ursula Geronzi, Laura Arianna Sorrentino, Salvatore Grosso, Giovanna Municchi

Department of Molecular Medicine and Development, Section of Pediatrics

University of Siena, Italy



Introduction

Kabuki syndrome (KS) is a rare genetic disorder (1 in 32,000 newborns) caused by mutations in the KMT2D gene (autosomal dominant pattern) or the KDM6A gene (X-linked dominant inheritance). KS is characterized by distinctive facial features including arched eyebrows, long eyelashes, long palpebral fissures with everted lower lids at the outside edges, flat, broadened tip of the nose and large protruding earlobes. The name of this disorder comes from the resemblance of its characteristic facial appearance to stage makeup used in traditional Japanese Kabuki theater. KS patients show also mild to severe developmental delay and intellectual disability. Other characteristic features of KS include seizures, microcephaly short stature, early puberty, skeletal abnormalities such as scoliosis and cleft palate, heart abnormalities, hearing loss and strabismus.



Kabuki Syndrome Network

Case report

A patient affected by KS, diagnosed at the chronological age (CA) of 6 years was referred to our department for short stature at the CA of 11 years. She presented typical facial features including arched eyebrows, long eyelashes, long openings of the eyelids and large protruding earlobes; she also showed mild intellectual disability, microcephaly, bilateral renal ectopia, bowel malrotation, strabismus, fetal pads and cleft palate surgically corrected at the CA of 1 year.

At the CA of 11.5 years patient was still prepubertal, height was 137.5 cm (-1.6 SDS), target height was 166 cm (0.58 SDS), bone age was 6.9 years, growth velocity was -4.6 SDS.

After excluding other causes of growth retardation, we evaluated her growth hormone (GH) secretion, by performing 2 pharmacologic stimulation tests (arginine and L-Dopa) that showed GH deficiency. Brain MRI for evaluation of hypothalamus and hypophysis was negative.

Idiopathic GH deficiency was diagnosed and GH replacement treatment was started at the usual dosage employed in idiopathic GH deficiency. During the first 6 months of treatment growth velocity markedly increased from -4.6 SDS to -1.5 SDS and no adverse events occurred. (Figure 1-2)

References

Growth Hormone Therapy in Children with Kabuki Syndrome: 1-year Treatment Results. Schott DA, Gerver WJM, Stumpel CTRM. *Horm Res Paediatr.* 2017;88(3-4):258-264

Growth Hormone Stimulation Tests in Children with Kabuki Syndrome. Schott DA, Gerver WJ, Stumpel CT. *Horm Res Paediatr.* 2016;86(5):319-324.

Figure 1

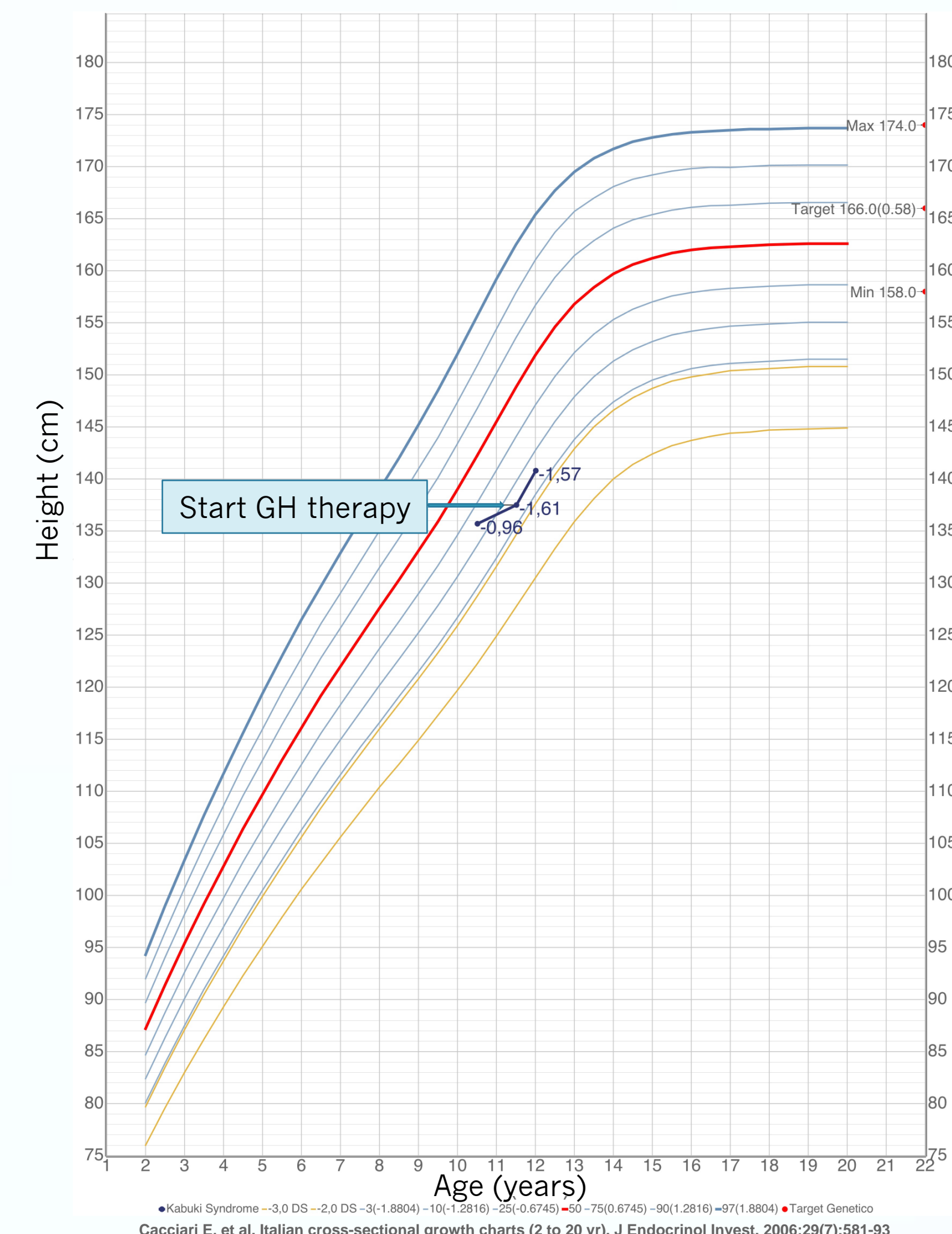
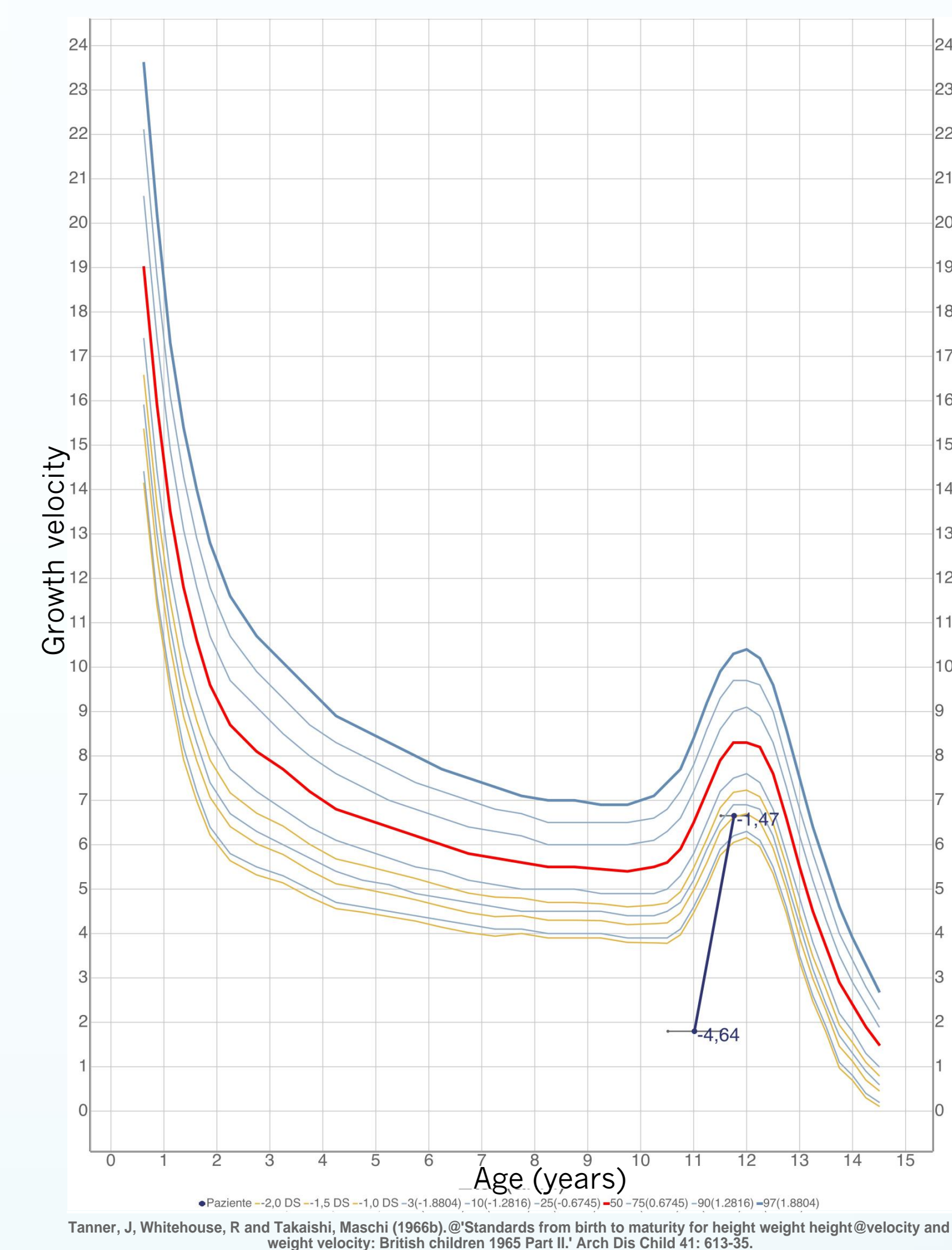


Figure 2



Conclusion

The presence of GH deficiency has been reported in some KS patients. In a study conducted on 18 KS children, 28% of these patients resulted biochemically GH deficient and those treated with GH showed a marked catch-up growth during the first year of rhGH treatment. Our patient started replacement therapy few months ago, therefore we do not have a sufficient follow-up to evaluate the persistent beneficial GH effect, after the dramatic increase in growth velocity observed during the first 6 months.

