



# Prader-Willi Patient with Rectal Bleeding – Experience in Center for Rare Endocrine Diseases in Varna, Bulgaria

Nikolinka Yordanova, a, Violeta Iotova a,b, Sonya Galcheva a,b, Yuliya Bazdarska,a, Vilhelm Mladenov a,b & Veselin Boyadzhieva, a,b

a UMHAT 'Sv. Marina', Varna, First pediatric clinic, Bulgaria; b Medical University, Varna, Bulgaria

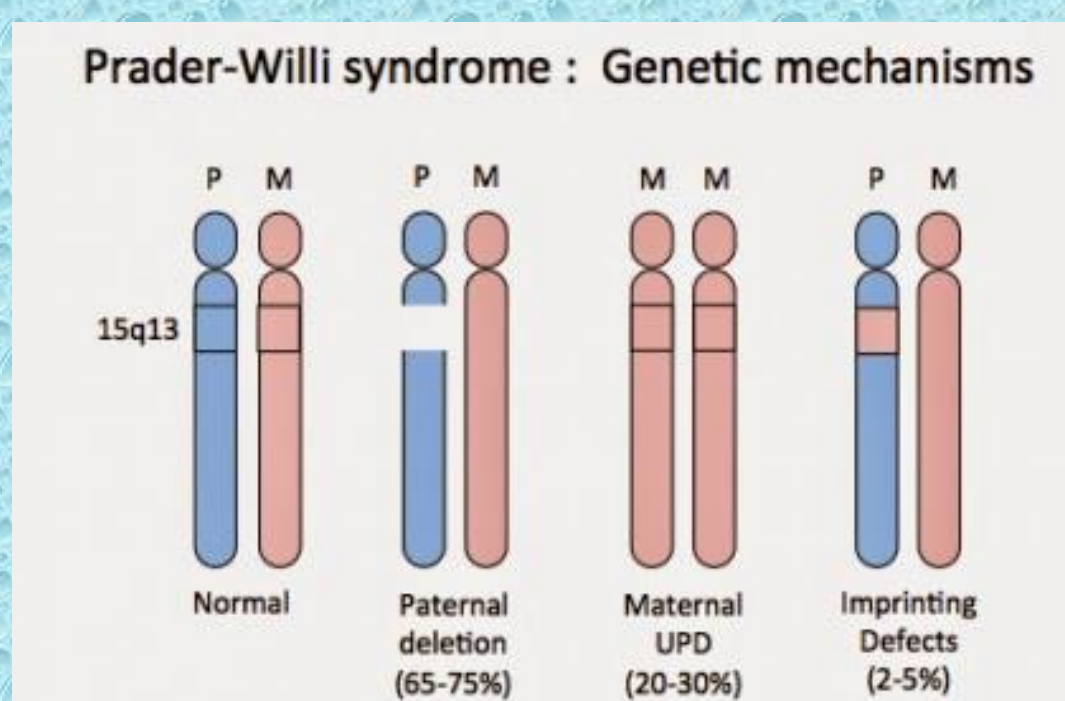
## CASE REPORT

We present a 16 year old girl with Prader-Willi syndrome. The girl has late diagnosis, genetically confirmed at 11 years of age. She was started with GH therapy immediately and she has satisfactory control of weight for the syndrome. The girl was doing well until a year ago her parents noticed that there is a **large amount of blood and mucus in girl's faeces**. She was admitted at another clinic, where **a lot of tests were performed** (blood and faeces samples, abdominal ultrasonography, contrast colon radiography and colonoscopy with biopsy under anesthesia). She was **misdiagnosed** with **mild form of chronic nonspecific colitis and rectal ulcer**. A high-dose anti-inflammatory treatment (Mesalazine) was prescribed together with probiotics and high-carbohydrate dietary regimen was recommended. Three months later the girl was admitted for routine endocrine tests. The nature and possible etiology of the bleeding problem were discussed and recommendations for detailed observation of the child were given, after which the mother was able to observe **self-scratching of the rectal area**. All unnecessary medications were stopped.

Every patient with PWS has his/her own specific needs that change with age and individualized approach is mandatory for providing them with **better quality of life**.

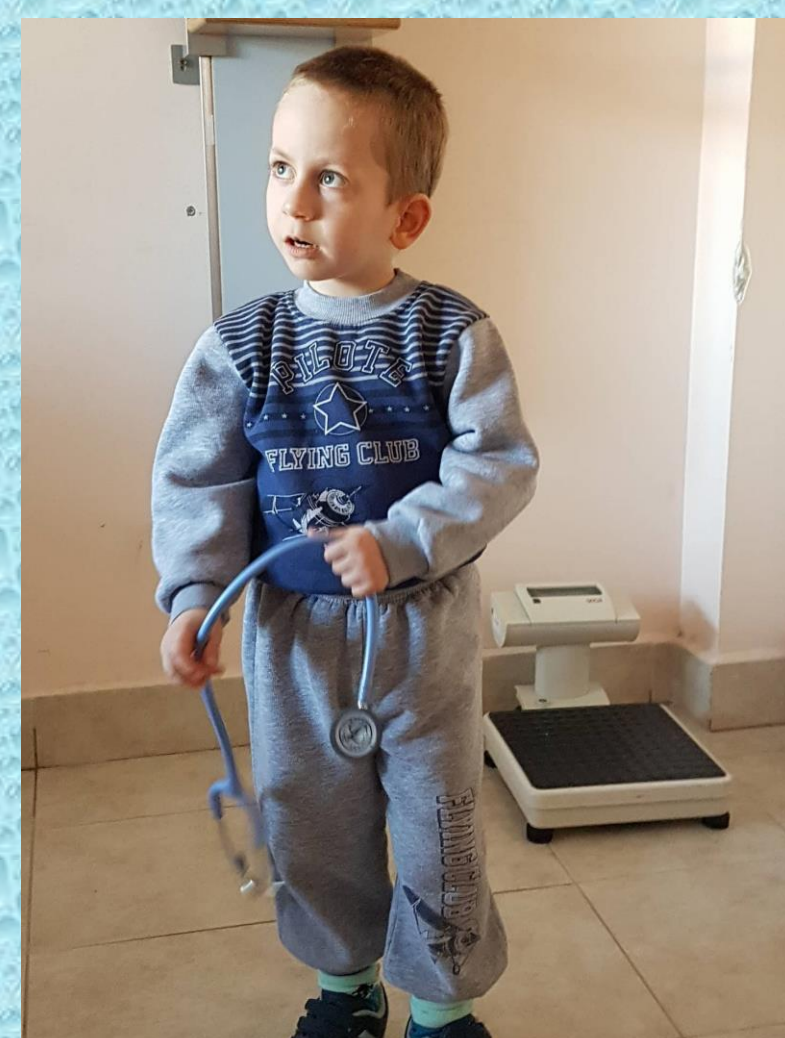**INTRODUCTION:** Prader-Willi syndrome (PWS) is rare genetic condition, which is associated with chromosome 15. It is characterized by muscle hypotonia in the early postnatal period, excessive weight gain after 2 years of age, lack of satiety, short stature and compulsive-like behavior. The self-excoriating skin picking behavior observed in individuals with PWS is quite common and can lead to persistent sores and infections, even requiring hospitalization. (2). In addition, self-injurious behavior such as rectal picking may be present and severe enough to lead to rectal ulceration and bleeding. (1)

What is Prader-Willi Syndrome?

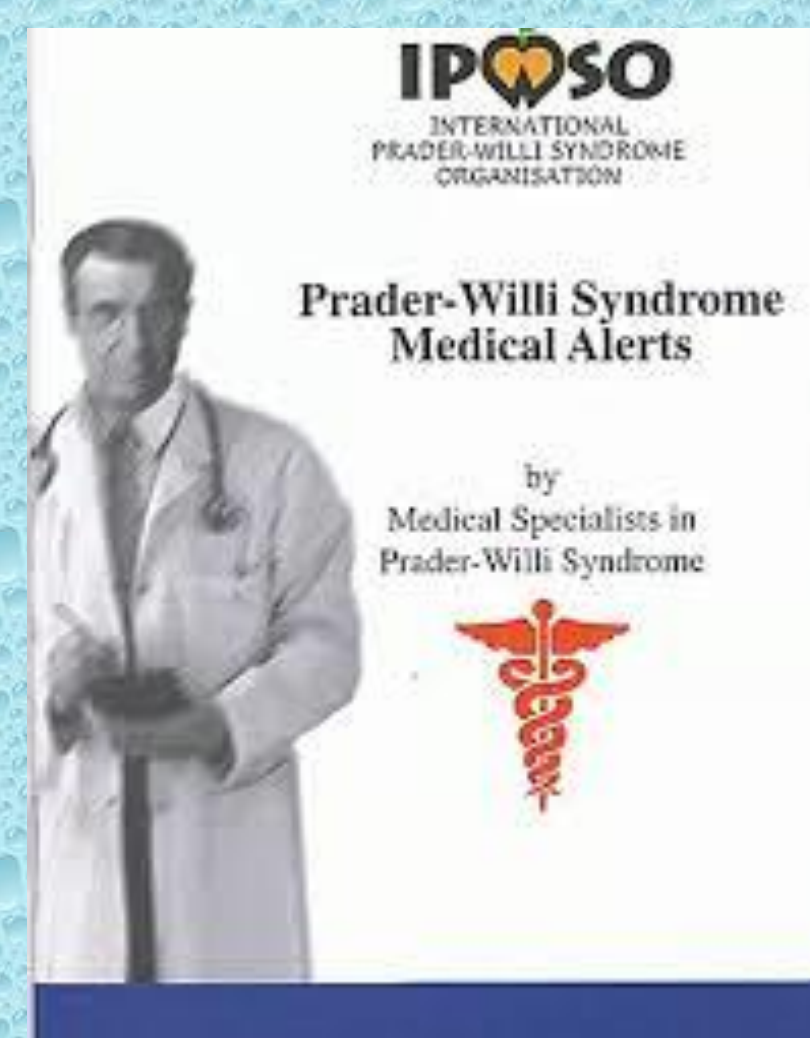


**OBJECTIVE:** To prove that PWS patients sometimes present with peculiar signs and complaints, and it is extremely important that experienced multidisciplinary team must care for them. Otherwise it is possible a patient to be misdiagnosed and a lot of unnecessary invasive investigations and treatment to be done and prescribed.

What is Prader-Willi Syndrome?



What is Prader-Willi Syndrome?



## References:

1. Salehi P1, Lee D2, Ambartsumyan L2, Sikka N3, Scheimann AO4,5, Rectal Picking Masquerading as Inflammatory Bowel Disease in Prader-Willi Syndrome.
2. Warnock JK1, Kestenbaum T, Pharmacologic treatment of severe skin-picking behaviors in Prader-Willi syndrome. Two case reports.
3. Campeotto F1, Naudin C, Viot G, Dupont C, Rectal self-mutilation, rectal bleeding and Prader-Willi syndrome.
4. Bhargava SA, Putnam PE, Kocoshis SA, Rowe M, Hanchett JM, Rectal bleeding in Prader-Willi syndrome.
5. Misumi A, Sera Y, Matsuda M, Inamori Y, Kawano H, Takano S, Murakami A, Akagi M., Solitary ulcer of the rectum: report of a case and review of the literature.
6. Patrice Carroll<sup>1</sup>, Janice Forster<sup>2</sup>, Linda Gourash<sup>2</sup> 1Advocates Inc, Framingham, MA, USA; 2 Pittsburgh Partnership, Pittsburgh, PA, USA, TREATMENT OF RECTAL PICKING BEHAVIOR IN PWS WITH SENSORY STIMULATION

## CONCLUSION

Self-scratching of rectum is common in PWS patients due to constipation, itching and high pain threshold. In the literature (1,3,4,5) 9 more similar cases and one unpublished case (6) are described. **Revealing the nature of connected bleedings could spare a lot of unnecessary tests and treatments to patients, and counseling of parents could prevent further episodes.**