

INTRODUCTION

- Turner Syndrome (TS), 45X0, is the most common chromosomal pathology affecting females, occurring in 1:2500 to 1:5000 female infants.
- The typical phenotype includes short stature, gonadal dysgenesis leading to sexual infantilism, low-set ears, low rear hairline, mammary hypertelorism, neck webbing, gothic palate, irregular rotation of the elbows, shield chest, shortening of the 4th metacarpal, low hairline, shortening of lower extremities, renal disorders and heart defects (cardiovascular malformations such as bicuspid aortic valve, aortic coarctation, aortic aneurysm, and mitral valve prolapse are found in approximately 20% of TS females).

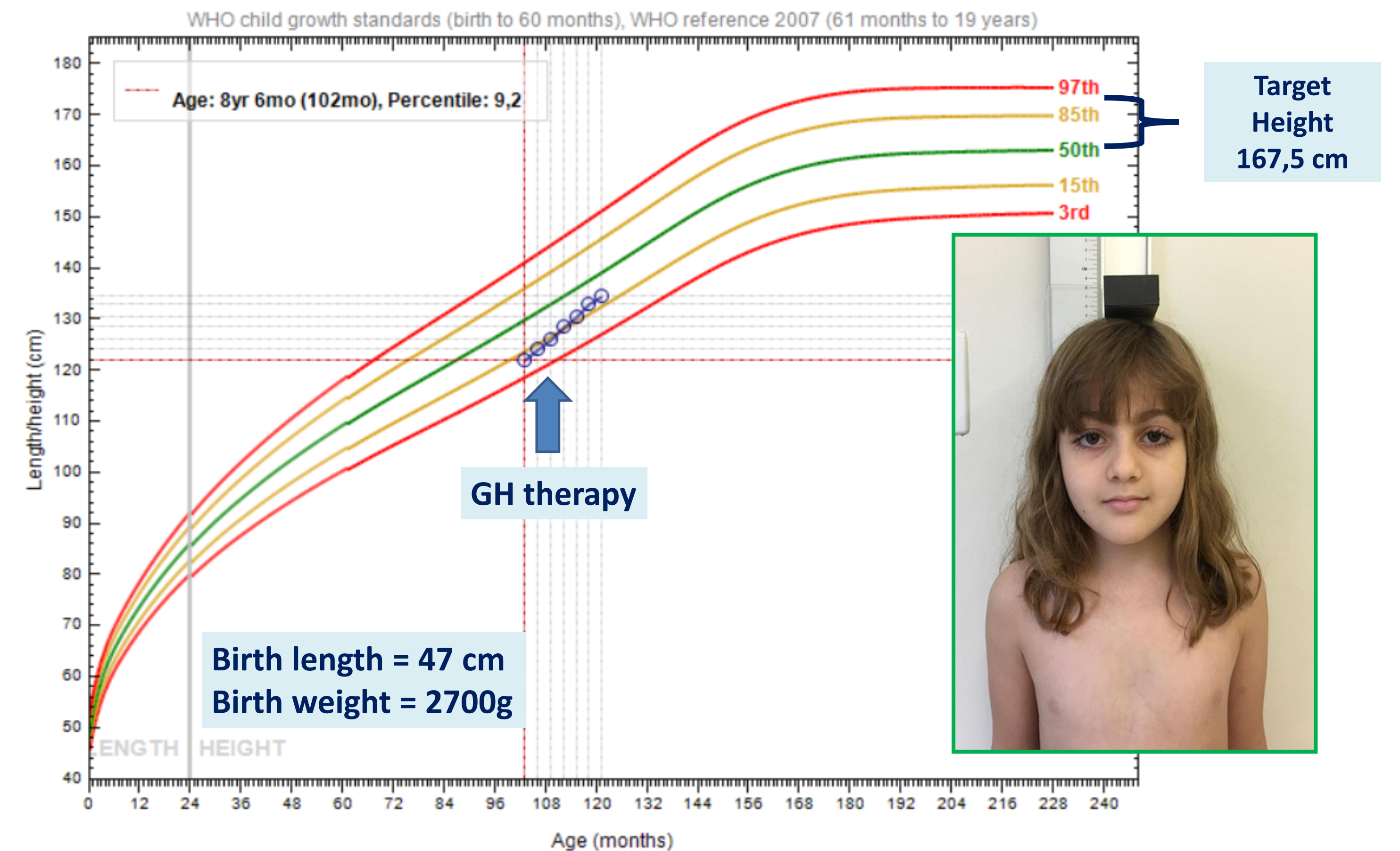
- 47XXX syndrome may be asymptomatic or present with tall stature, microcephaly, epicanthal folds, language learning disabilities and muscular dystonia.
- Mosaicism is observed in approximately 30% of all TS cases, 1% representing the 45X/47XXX karyotype. Such rare cases can present with different phenotypes. The presence of the 47XXX cell-line makes them more prone to spontaneous menarche and more fertile, as compared to 45X.

CASE REPORT

- ALM, third daughter of a non-consanguineous couple, was referred to the pediatric endocrinology service due to a decrease in growth velocity. Child without chronic diseases, proper nutrition and normal neuro-psychomotor development.

- Laboratory investigation ruled out hypothyroidism, renal or cardiac defects.

RESULTS



- Estimated target height was 167,5cm (75th Percentile). Birth length was 47 cm, height at 8,7 years was 122cm (5th Percentile). Physical examination showed epicanthal folds and mammary hypertelorism.
- Conventional cytogenetic examination showed a mosaic karyotype with 66% of cells with X trisomy (47XXX) and 34% with X monosomy (45X0).

CONCLUSIONS

- 45X/47XXX females have no typical phenotype, and may present with various degrees of ovarian function, starting from normal to absent of hormonal secretion, with mono or bilateral streak gonads.
- Prognostic counseling in Turner Syndrome is in growing demand, especially in the case of mosaics, uncommon karyotypes, and in prenatal detection of the sex chromosome aneuploidy. There is special interest, because of the possibility of ovarian tissue preservation in such patients.

REFERENCES

- Bouchlariotou S. et al. Turner's syndrome and pregnancy: has the 45,X/47,XXX mosaicism a different prognosis? Own clinical experience and literature review. The Journal of Maternal-Fetal and Neonatal Medicine, May 2011; 24(5): 668-672
- Maciejewska-Jeske M et al. The Turner syndrome in patient with 45X/47XXX mosaic karyotype - case report. Gynecol Endocrinol, 2015 DOI: 10.3109/09513590.2015.1018164
- Otter M et al. Triple X syndrome: a review of the literature. European Journal of Human Genetics (2010) 18, 265-271.
- Tauchmanová L. et al. Turner's syndrome mosaicism 45X/47XXX: An interesting natural history. J. Endocrinol. Invest. 24: 811-815, 2001