

Bone marrow failure in Mc Cune Albright Syndrome

K. Wechsung, E. Lankes, P. Kühnen, A. von Stackelberg, D. Schnabel

Center for Chronic Sick Children, Pediatric Endocrinology, Pediatric Hematology/Oncology
Charité University Medicine Berlin, Germany

Introduction and objectives

Mc Cune Albright Syndrome (MAS) is caused by a somatic activating mutation at the GNAS locus. Clinical manifestations range from the classic triad including café au lait macules, fibrous dysplasia and precocious puberty to a severe multisystem disease.

Methods

We present a patient with bone marrow failure as a rare non-endocrine complication of MAS.




Figure 2 Patient with massive abdominal distension

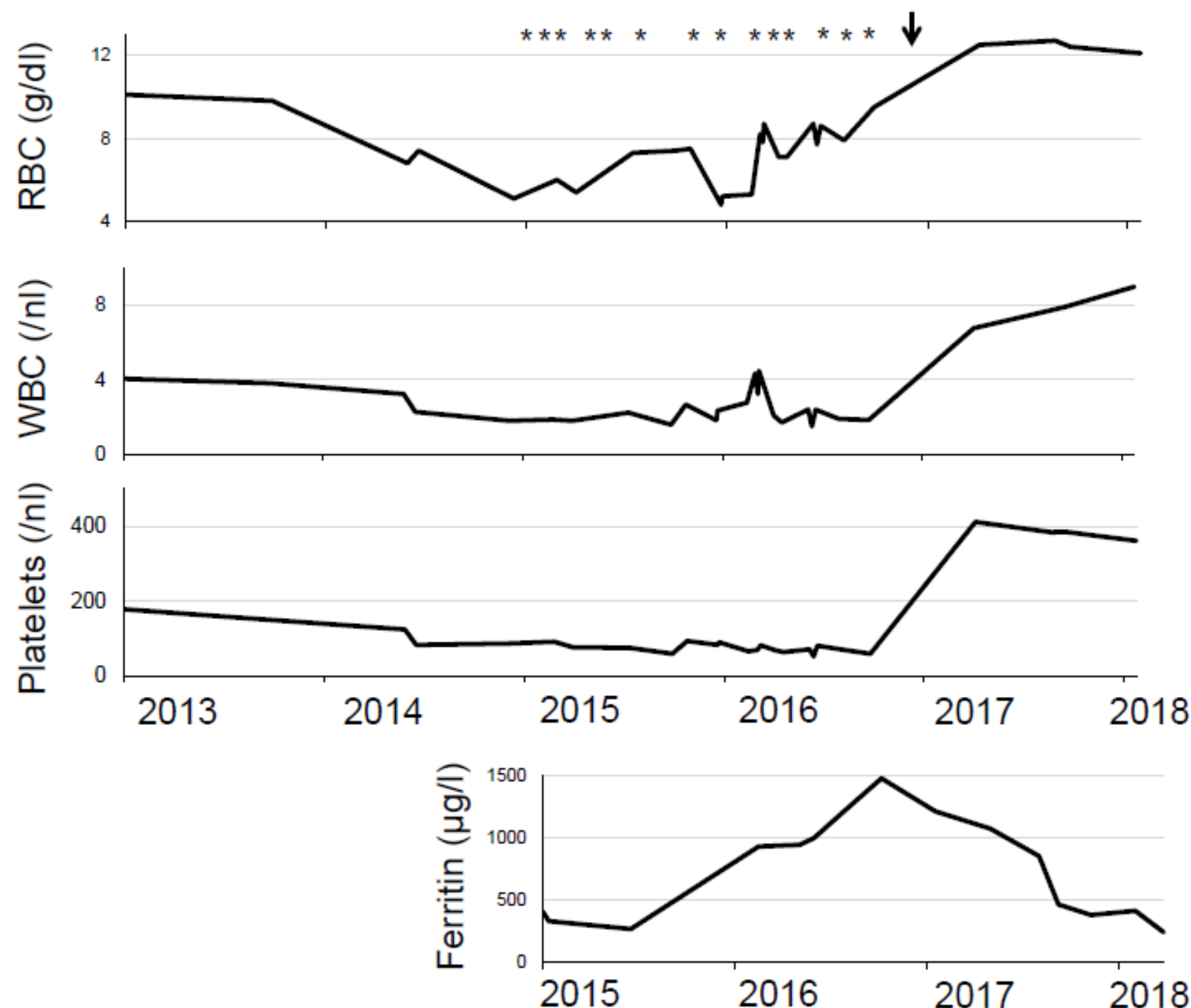


Figure 3 Blood count and ferritin before and after splenectomy, * transfusion, ↓ Splenectomy

Clinical case

A 14 year old girl with a multisystem manifestation of MAS (Table 1, Figure 1) felt weak and exhausted. Her blood count showed pancytopenia (WBC 2.23 [$10^3/\mu\text{L}$], RBC 3.16 [$10^6/\mu\text{L}$], PLT 92 [$10^3/\mu\text{L}$]).

- Cell morphology: anisopoikilocytosis, dacrocytes and a left shift
- Clinical chemistry: unremarkable
- Screening for infection: no signs for Hepatitis A,B,C, EBV, HIV, CMV
- Bone marrow biopsy: osteo-fibrous lesions with markedly reduced cell count, FISH: no signs for myelodysplastic syndrome, PCR: mutation in GNAS Locus: (c.601C>T,p.R201C)
- Abdominal CT: massive splenomegaly (max. 166mm), no sign of intraabdominal tumour, deformed axial skeleton with inhomogeneous, fibrous bone structure in all visible bones (Figure 1c).

The splenomegaly progressed and regular transfusions had to be started (Figure 2, 3). The patient developed dyspnoea and abdominal pain. Therefore at the age of 17 a splenectomy was performed. Histology confirmed extramedullary haematopoiesis in the spleen. The blood count recovered completely after splenectomy. No further transfusions were necessary (now 1 ½ years after operation).

Conclusions

In fibrous dysplasia undifferentiated bone marrow stromal cells replace the hematopoietic marrow. Nevertheless bone marrow failure rarely occurs in patients with MAS.

Whether the extent of fibrous dysplasia / bone reconstruction surgery, the presence of endocrinopathies or a different mechanism triggered the onset of bone marrow failure in our patient remains open.

Four case reports of patients with MAS and extramedullary splenic haematopoiesis which improved after splenectomy exist (1-4). Hyperthyroidism is described in all of these patients. The endocrinopathies in our patient were well controlled at the onset of pancytopenia. But a breast duct papilloma was resected shortly before, which might have caused haematopoietic stress.

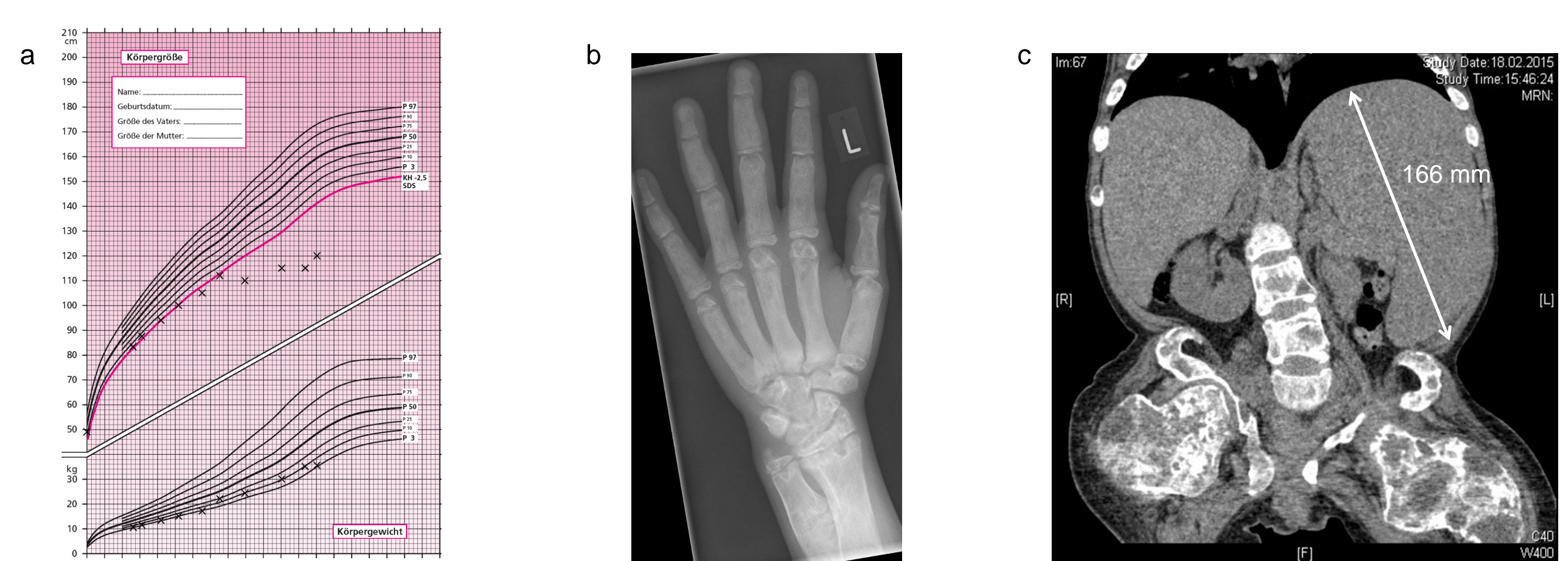


Figure 1 a) growth curve of the patient b) X ray of the left hand at the patient age of 9 years with accelerated bone age of 13 years and lytic changes of the bone structure c) abdominal CT reveals massive splenomegaly at age 15

Table 1 Manifestations of MAS in the patient with age at onset und treatment

Manifestations of MAS	Onset	Therapy & Course
Café au lait spot	birth	-
Neonatal giant cell hepatitis	6 weeks	Resolved after antibiotic treatment
Precocious puberty	2 years	Anastrozole age 4-9, Supressed vaginal bleeding until age 6
Fibrous dysplasia	1 ½ years	18 Operations, iv Bisphosphonate therapy 12 Fractures, severe short stature, scoliosis, wheel chair dependency
Hyperthyroidism	4 years	Methimazole age 8-11 and 15-17
FGF-23 mediated phosphate wasting	8 years	Oral phosphate, 1,25-(OH) ₂ -Vit D
Breast duct papilloma	14 years	Complete resection

1. Mahdi, A.J., P. Connor, and I. Thakur, McCune-Albright syndrome-associated bone marrow failure and extramedullary haematopoiesis secondary to fibrous dysplasia. Br J Haematol, 2017. 178(2): p. 179.
2. Peitersen, B., et al., Myelofibrosis and T3-thyreotoxicosis in a girl with McCune-Albright Syndrome. Pediatric Research, 1981. 15: p. 86.
3. Robinson, C., et al., Bone marrow failure and extramedullary hematopoiesis in McCune-Albright syndrome. Osteoporos Int, 2018. 29(1): p. 237-241.
4. Samuel, S., et al., Hyperthyroidism in an infant with McCune-Albright syndrome: report of a case with myeloid metaplasia. J Pediatr, 1972. 80(2): p. 275-8.

