

Rapid onset and progression of chronic kidney disease in a child with Autoimmune Polyglandular Syndrome Type 1.

Vasiliki Rengina Tsinopoulou¹, Eleni Kotanidou¹, Maria Grammatiki¹, Styliani Giza¹, Eleni Litou¹, Tasos Tzirtzipis¹, Olga Nikolaidou¹, Theodoros Liargokovinos¹, Despina Tramma¹, Panagiotis Pateinakis², Dorothea Papadopoulou², Assimina Galli-Tsinopoulou¹

¹ 4th Department of Paediatrics, School of Medicine, Faculty of Health Sciences, Aristotle University of Thessaloniki, Papageorgiou General Hospital, Thessaloniki, Greece

² Nephrology Department, Papageorgiou General Hospital, Thessaloniki, Greece

Disclosure Statement: Authors declare that they have no conflict of interest

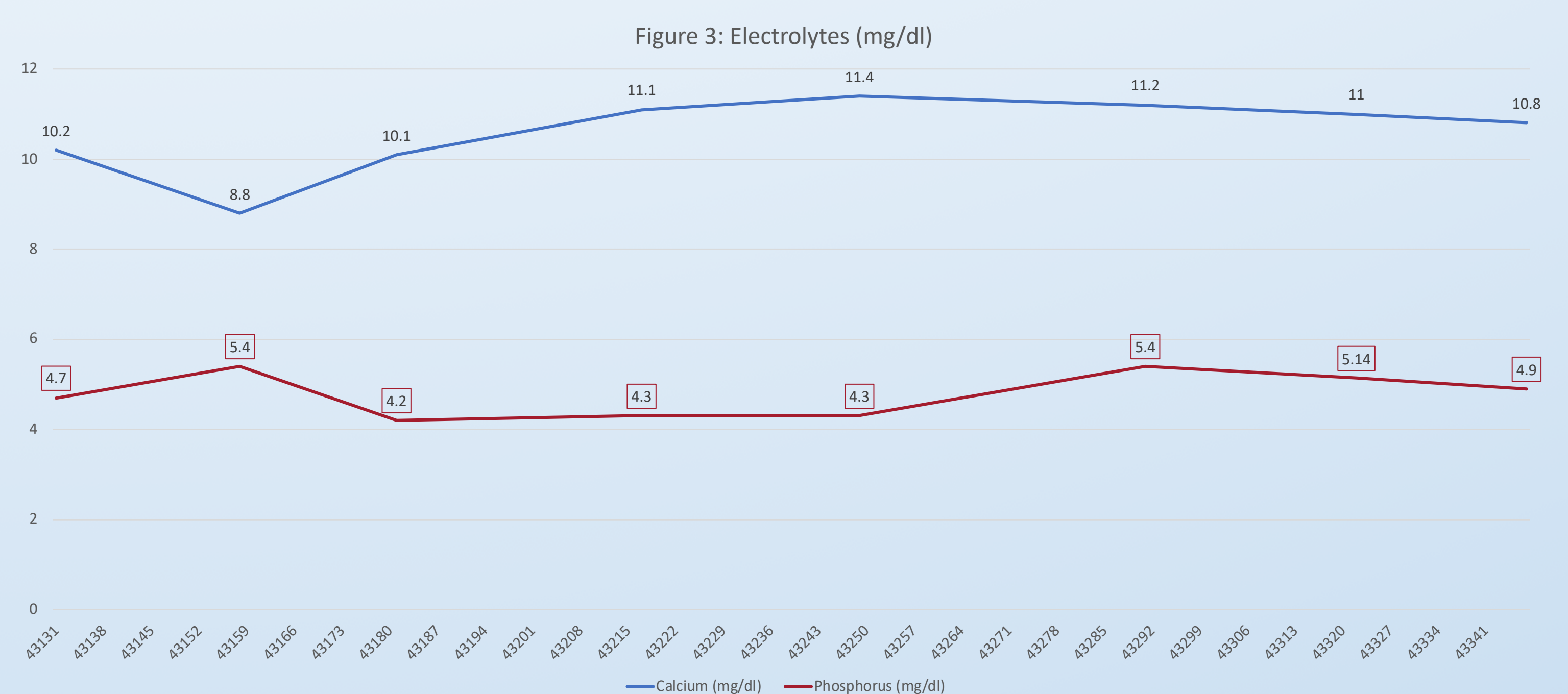
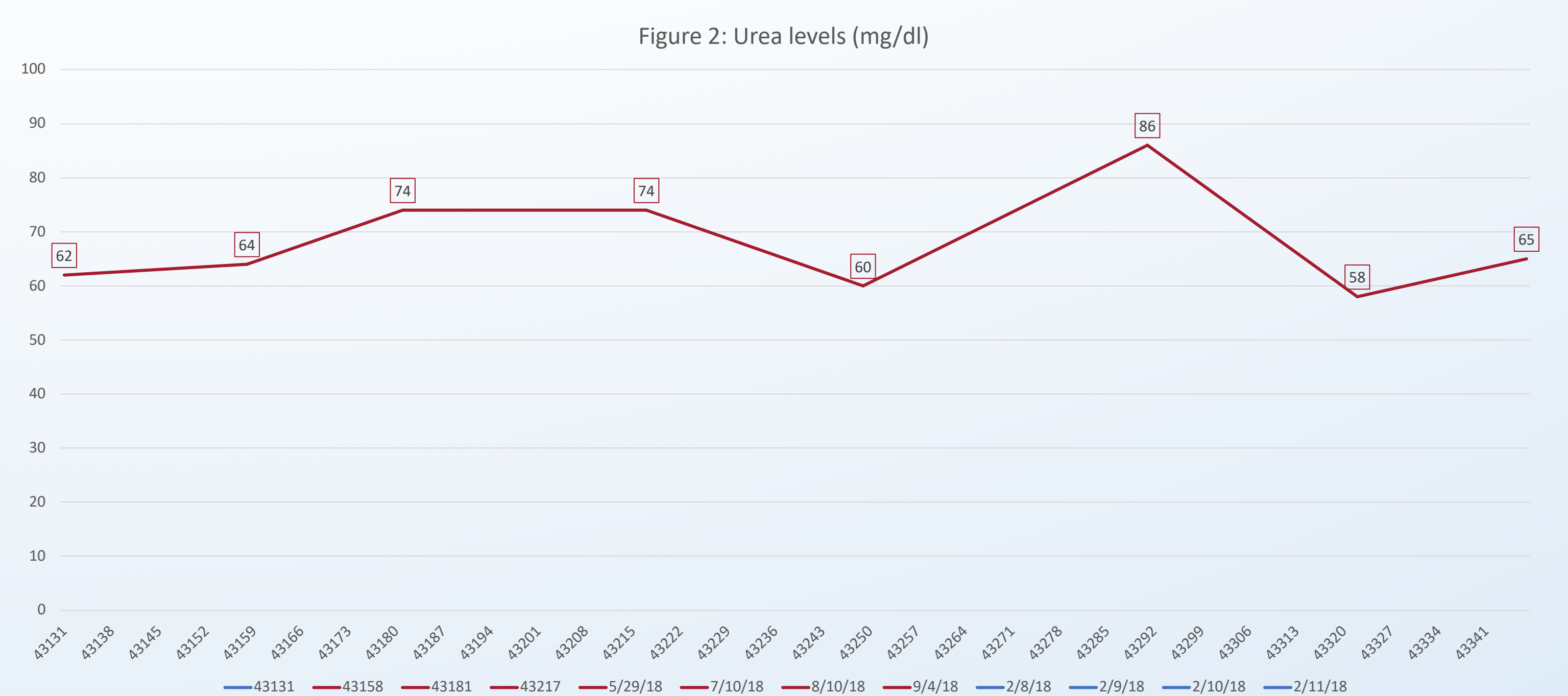
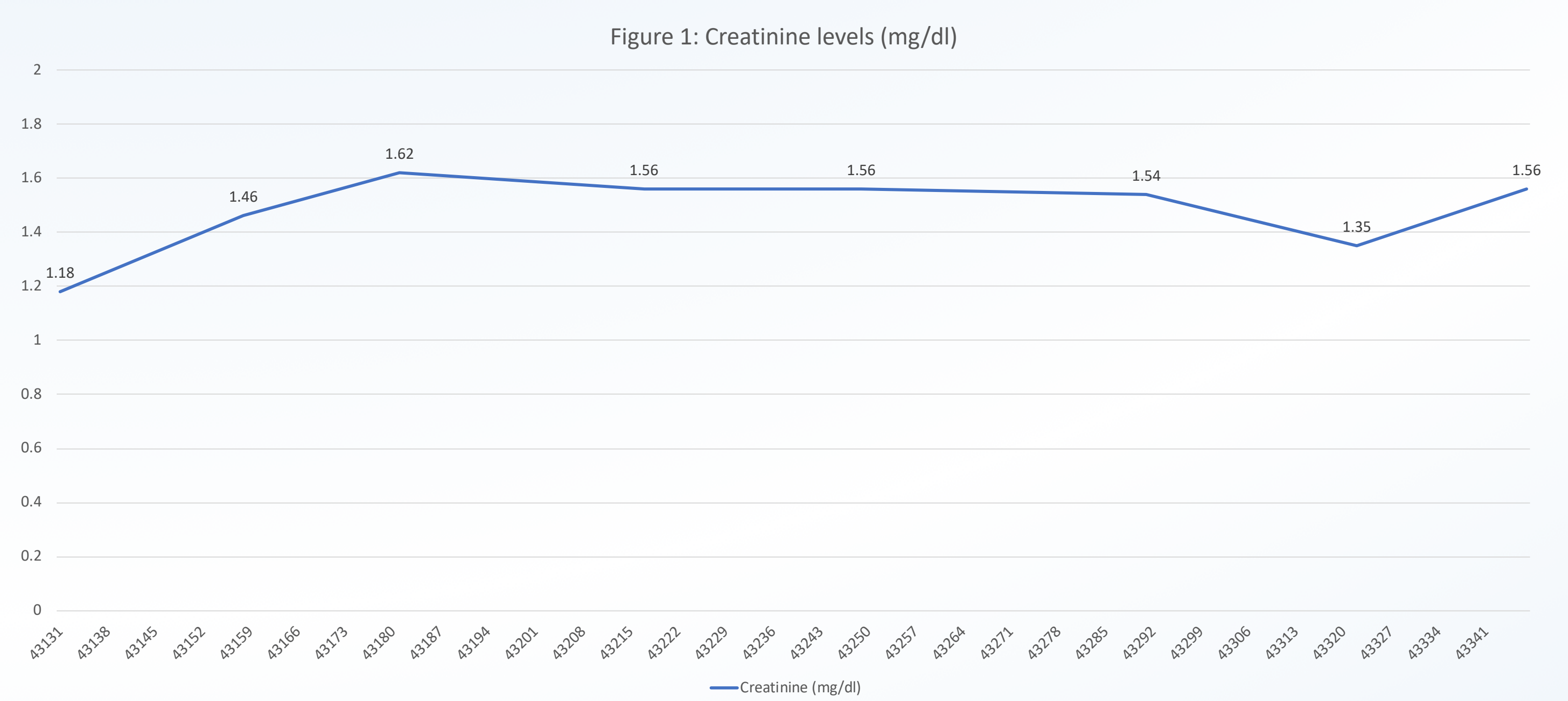
Introduction and Purpose

Autoimmune Polyglandular Syndrome Type 1 (APS-1) is a rare autosomal recessive hereditary disorder resulting from a mutation in the AIRE gene. APS-1 is characterized by three classic clinical features: hypoparathyroidism, Addison's disease and chronic mucocutaneous candidiasis. Additionally to the classic triad, the phenotype of APS-1 includes several endocrine and nonendocrine autoimmune manifestations.

Our purpose is to present a rapid onset and progression of chronic kidney disease (CKD) in a 10-year-old boy with APS-1

Case Presentation

A 10-year-old Greek boy was diagnosed with APS-1 at the age of 2^{6/12} years. At the age of 6 years he was diagnosed with hypothyroidism due to Hashimoto's thyroiditis. Despite the good control he presented with **short stature** while growth hormone deficiency and coeliac disease were excluded. He was under substitution therapy with hydrocortisone, fludrocortisone, levothyroxine, alfacalcidol as well as calcium, magnesium, miconazole oral gel and nystatin mouthwash. He was under regular outpatient clinical follow up and annual full laboratory testing. At the age of 10 years old he presented on his annual routine laboratory follow up with high levels of creatinine, urea and anemia; however, serum sodium, potassium, calcium and phosphorus levels were found within normal range. Clinical examination revealed no pathological findings except short stature and decreased height velocity. Further nephrological investigation including 24hour urine collection and 51Cr- EDTA glomerular filtration rate (GFR) assessment confirmed the renal impairment. Over the next few weeks and while creatinine levels had worsened a renal biopsy were conducted. **GFR was measured at 33 ml/min/1,73m² and renal biopsy revealed findings of transmembrane nephritis, few tubular calcifications and chronic vascular lesions** not expected for the patient's age, resulting together in the diagnosis of stage 3b CKD. Immunological assessment was negative. Pending the whole exome sequencing results, the patient remains under very strict serum creatinine, pH, electrolyte status and GFR follow up while future renal replacement therapy seems unavoidable. Based on international guidelines regarding CKD, patient is under recombinant growth hormone replacement therapy. Creatinine, urea and electrolyte levels (Figures 1,2,3, respectively) as well as height velocity were significantly improved.



Conclusion

Renal failure is a rare clinical manifestation in APS-1 and its prevalence varies from 2-17% in both children and adults; however, the pathogenetic mechanism remains unknown. A very few cases of end stage renal disease in children with APS-1 are presented in the literature, while no adjuvant therapy (i.e. high doses of corticosteroids, monoclonal antibodies) managed to delay the progression of the disease. Prognosis remains poor and renal replacement therapy or transplantation seems the only existing therapeutic approaches.

References

1. Kluger N, Kataja J, Aho H, Ronn A, Krohn K, Ranki A. Kidney involvement in autoimmune polyendocrinopathy- candidiasis-ectodermal dystrophy in a Finish cohort. Nephrol Dial Transplant. 2014;29(9):1750-1757.
2. Ulinski T, Perrin L, Morris M, Houang M, Cabrol S, Grapin C et al. Autoimmune Polyendocrinopathy-Candidiasis-Ectodermal Dystrophy Syndrome with Renal Failure: Impact of Posttransplant Immunosuppression on Disease Activity. J Clin Endocrinol Metab. 2006;91(1):192-195.