

Ultrasound-based measurements of testicular volume

Observer agreement and comparison with Prader orchidometry

Ninnie B. Oehme ^{1,2}, Mathieu Roelants ³, Ingvild S. Bruserud ^{1,2}, Geir Egil Eide ^{1,4}, Robert Bjerknes ^{1,2}, Karen Rosendahl ^{1,5}, Pétur B. Júlíusson ^{1,2}
¹University of Bergen, Bergen, Norway; ²Department of Pediatrics, Haukeland University Hospital, Bergen, Norway;
³Environment and Health, Department of Public Health and Primary Care, KU Leuven – University of Leuven, Belgium;
⁴Centre for Clinical Research, Haukeland University Hospital, Bergen, Norway; ⁵Department of Radiology, Haukeland University Hospital, Bergen, Norway

Poster Number: P2-P304
 Puberty

Contact information:
 Ninnie B. Oehme
 University of Bergen
 ninnie.oehme@uib.no

Background

Testicular size is commonly assessed with Prader orchidometry. As this technique is subjective and tends to overestimate the testicular volume, ultrasound has been proposed as more reliable.

Objectives

To evaluate the intra- and inter-observer agreement of ultrasound measurements of testicular volume and to compare ultrasound with the orchidometry.

Methods

Dimensions of the right testicle were measured using ultrasound (fig.1) in 57 boys aged 6.5 to 16.4 (mean 12.0) years. The measurements were performed twice by a pediatric radiographer (obs.1) and once by a pediatric radiologist (obs.2). A pediatric endocrinologist estimated testicular volume using a Prader orchidometer. Agreement was investigated with Bland-Altman plots, and summarized as the mean and standard deviation of differences, 95% limits of agreement, and technical error of measurement.

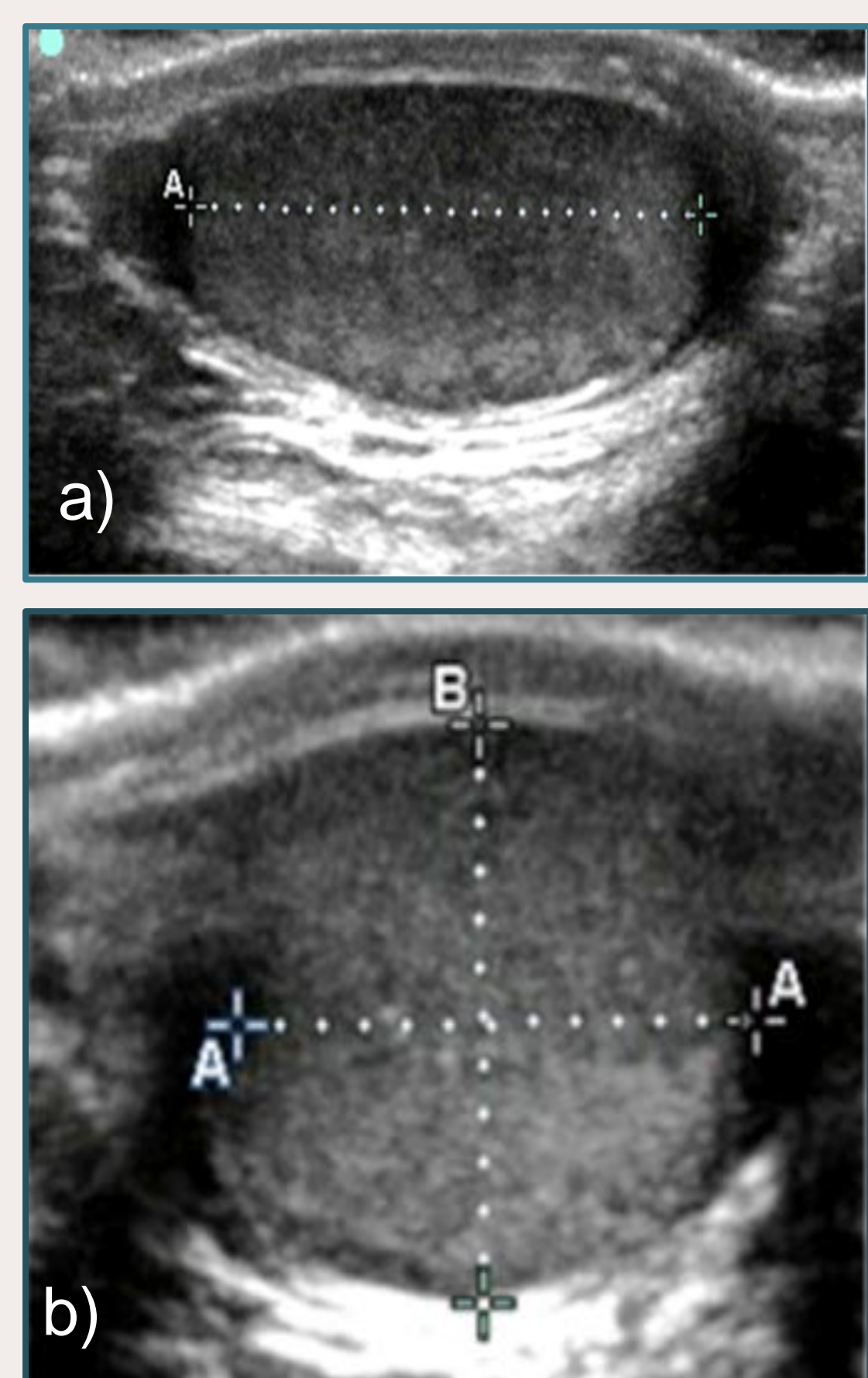


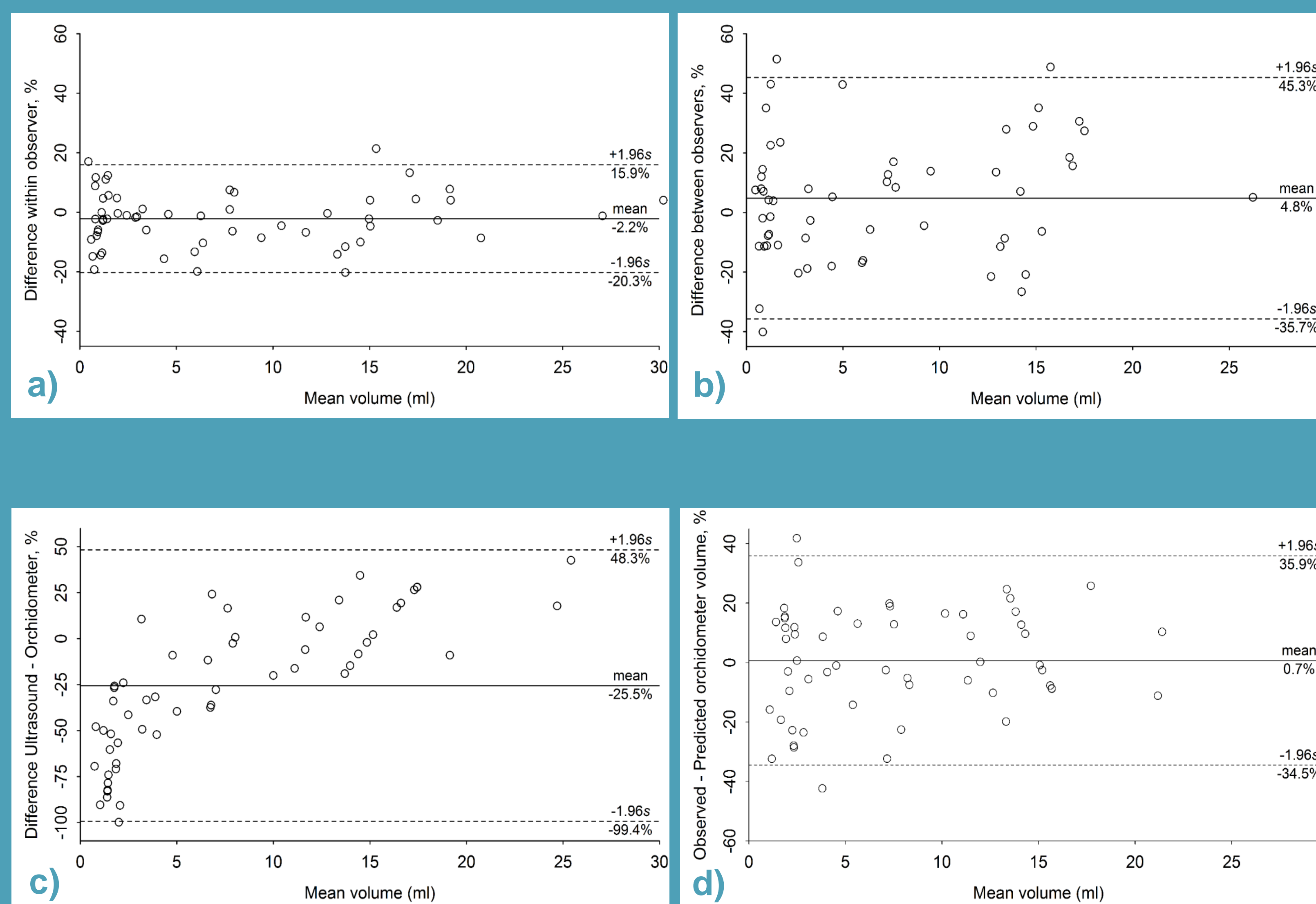
Figure 1
 Ultrasound of the testes in a 12-year old boy, using 15-6 Mhz linear probe;
 a) length measured on sagittal view;
 b) width and depth from the transverse view

Results: Ultrasound measurements

Table 1 Results from US measurements of the testes in 57 healthy Norwegian boys aged 6.5 to 16.4 years (mean: 12 years) in Bergen 2017. Abbreviations: US = ultrasound; SD = standard deviation; LOA = limits of agreement; TEM = technical error of measurement. a) One outlier removed

Comparison	Length (cm)	Width (cm)	Depth (cm)	Volume (ml)
Intra-observer				
1st reading, mean (SD)	2.7 (1.0)	1.8 (0.7) ^{a)}	1.5 (0.7)	7.6 (7.5) ^{a)}
2nd reading, mean (SD)	2.7 (1.0)	1.8 (0.7)	1.5 (0.7)	7.7 (7.5)
% difference, mean (SD)	-1.6 (6.1)	-0.6 (8.2)	-0.5 (7.9)	-2.2 (9.2)
95% LOA (%)	(-13.6, 10.4)	(-16.7, 15.4)	(-16.0, 15.0)	(-20.3, 15.9)
TEM (%)	4.3	5.8	5.6	6.5
Inter-observer				
1st observer, mean (SD)	2.7 (1.0)	1.8 (0.7) ^{a)}	1.5 (0.7)	7.6 (7.5) ^{a)}
2nd observer, mean (SD)	2.9 (1.1)	1.7 (0.6)	1.4 (0.6) ^{a)}	6.6 (6.1) ^{a)}
% difference, mean (SD)	-6.7 (9.7)	3.1 (9.9)	7.9 (16.2)	4.8 (20.7)
95% LOA (%)	(-25.8; 12.3)	(-16.2; 22.5)	(-23.8; 39.6)	(-35.7; 45.3)
TEM (%)	6.9	7.0	11.5	14.6
US vs orchidometer				
Orchidometer, mean (SD)				7.7 (5.9)
% difference, mean (SD)				-25.5 (37.7)
95% LOA (%)				(-99.4; 48.3)
TEM (%)				26.7

Results: Bland-Altman mean difference plots



(a) Intra-observer and (b) inter-observer variation of ultrasound measured testicular volume. Differences between the measurements are expressed as a percentage of the mean ($100 \times (\text{Vol.1} - \text{Vol.2}) / \text{Mean Volume}$) because the variance increases with the volume. Horizontal lines indicate the mean difference and 95% limits of agreement (LOA: mean \pm 1.96s).

Method variation of testicular volume measured with (c) ultrasound (US) ($L \times W \times D \times 0.71$) and the Prader orchidometer (OM) shows a clear upward trend and very wide limits of agreement, but further analysis show that agreement improves considerably when OM volume is predicted from US volume as $\text{Vol}_{\text{OM}} = 1.96 \times \text{Vol}_{\text{US}}^{0.71}$ (d). Differences are expressed as a percentage of the mean ($100 \times (\text{US} - \text{OM}) / \text{Mean Volume}$).

Conclusion

Small mean intra- and inter-observer difference indicates the potential of ultrasound for measurement of testicular volume on a group level. The intra-observer error was limited which justifies its use in longitudinal follow up of testicular development in an individual child, but the larger inter-observer variability indicates the need for good standardization of methods. Agreement between the two methods requires a power transformation.

Disclosure statement
 There are no conflicts of interest

REFERENCES
 Oehme, N. B. et al. (2018). Ultrasound-based measurements of testicular volume in 6- to 16-year-old boys - intra- and interobserver agreement and comparison with Prader orchidometry. Springer, *Pediatr Radiol*. Copyright 2018

