

# Pituitary adenoma in children and adolescents: a retrospective single-centre analysis

Thomas Breil<sup>1</sup>, Catherine Lorz<sup>1</sup>, Daniela Choukair<sup>1</sup>, Janna Mittnacht<sup>1</sup>, Ioana Inta<sup>1</sup>, Daniela Klose<sup>1</sup>, Jessica Jesser<sup>2</sup>, Egbert Schulze<sup>3</sup>, Markus Bettendorf<sup>1</sup>  
<sup>1</sup>Division of Paediatric Endocrinology and Diabetes, Department of Paediatrics, University Hospital Heidelberg, Heidelberg, Germany  
<sup>2</sup>Neuroradiology, University Hospital Heidelberg, Heidelberg, Germany  
<sup>3</sup>Molecular Laboratory, Prof. F. Raue, Heidelberg, Germany

## Conclusion:

Pituitary adenomas (PA) are more frequent in girls than in boys. Prolactinomas (PROLA) are commonest PA even in children. Clinical signs are unspecific in PROLA and incidentalomas (INCA) and secreted hormone specific in adrenocorticotrophic-hormone (ACTHA) and growth-hormone (GHA) secreting adenomas. Headaches occur in all forms of PA. Cabergoline is well tolerated in PROLA and reduces clinical symptoms, prolactin serum concentrations and tumour size. Complete tumour resection in ACTHA reverses clinical signs, but may be complicated by secondary adrenal insufficiency and hypopituitarism. Somatostatin analogues improve clinical symptoms in GHA, but barely reduce tumour size. INCA may only require symptomatic treatment. A comprehensive registry for PA is desirable to understand its aetiology and to improve care in paediatrics.

## Background:

PA in children and adolescents are rare and of unknown aetiology. Treatment guidelines are lacking.

## Methods:

Data of paediatric patients with PA diagnosed between 2000 and 2016 in our institution were extracted from their electronic chart and analysed.

## Results:

22 patients with PA were identified (fig. 1). INCA and ACTHA were all microadenomas and GHA were giant adenomas with infiltrative growth (diameter 1.9-6.2 cm, fig 2.). PROLA consisted of 7 macro- (diameter 1.4-3.6 cm) and 5 microadenomas (diameter 0.3-0.9 cm). At diagnosis of PROLA median serum prolactin concentration was 3202 mU/L (1005-94541 mU/L), median lowest GH serum concentration in oral glucose tolerance test was 3.1 ng/ml (2.9-17.9 ng/ml) in GHA. All ACTHA had elevated serum ACTH and cortisol concentrations with loss of normal circadian rhythm, median serum ACTH concentration at midnight was 28 pg/ml (26-29 pg/ml) and median serum cortisol concentration at midnight was 19 pg/dl (14-22 pg/dl).

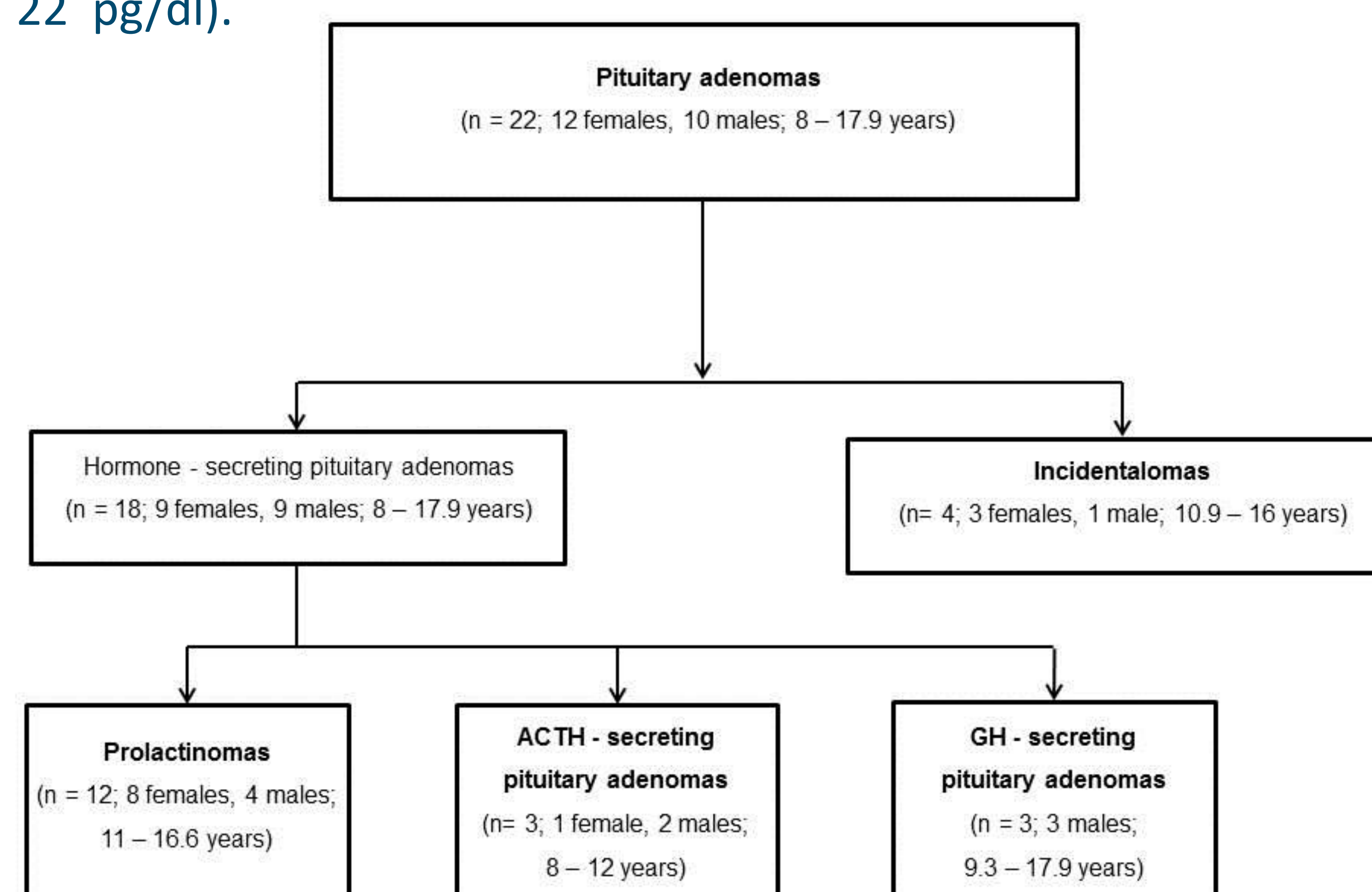


Figure 1: Trial profile

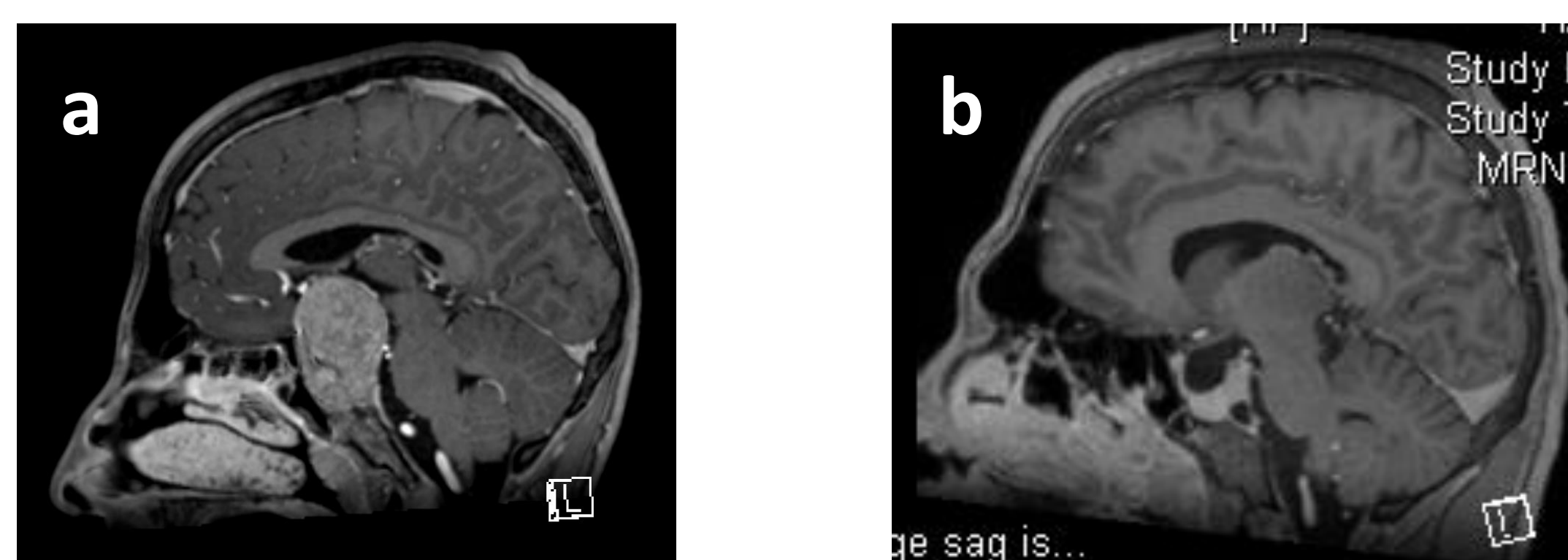


Figure 2: cMRI (T1): 17.9-year old boy with GHA (a) at diagnosis, (b) after 4 years treatment with surgical debulking and lanreotide 90 mg every 4 weeks

## Symptoms:

- PROLA: headaches (67%), pubertal delay (67%), hypopituitarism (50%)
- ACTHA: cushingoid features (100%), headaches (100%)
- GHA: tall stature (100%), headaches (100%), hypopituitarism (67%)
- INCA: nausea (25%), headaches (75%), precocious puberty (25%), mental retardation (25%), epilepsy (25%)

## Therapy:

- PROLA: Cabergoline reduced serum prolactin concentrations (105-3297 mU/L), tumour volume by 80% and symptoms in 11 patients (Fig. 3 and 4). 1 PA was surgically removed. Median follow-up was 39 months (12-110 months).
- ACTHA: Complete tumour resection was performed in all patients which was complicated by hypopituitarism including adrenal insufficiency in all 3 patients. Median follow-up was 84 months (72-96 months).
- GHA: Surgical debulking followed by treatment with lanreotide (max. 90 mg every 4 weeks) or pasireotide (max. 60 mg every 4 weeks) (n=2) and lanreotide alone (max. 120 mg every 4 weeks) (n=1) resulted in resolution of clinical symptoms, reduction of GH secretion (56%) and stabilisation of tumour volume. Median follow-up was 54 months (22-75 months).
- INCA: Lost to follow-up without treatment.

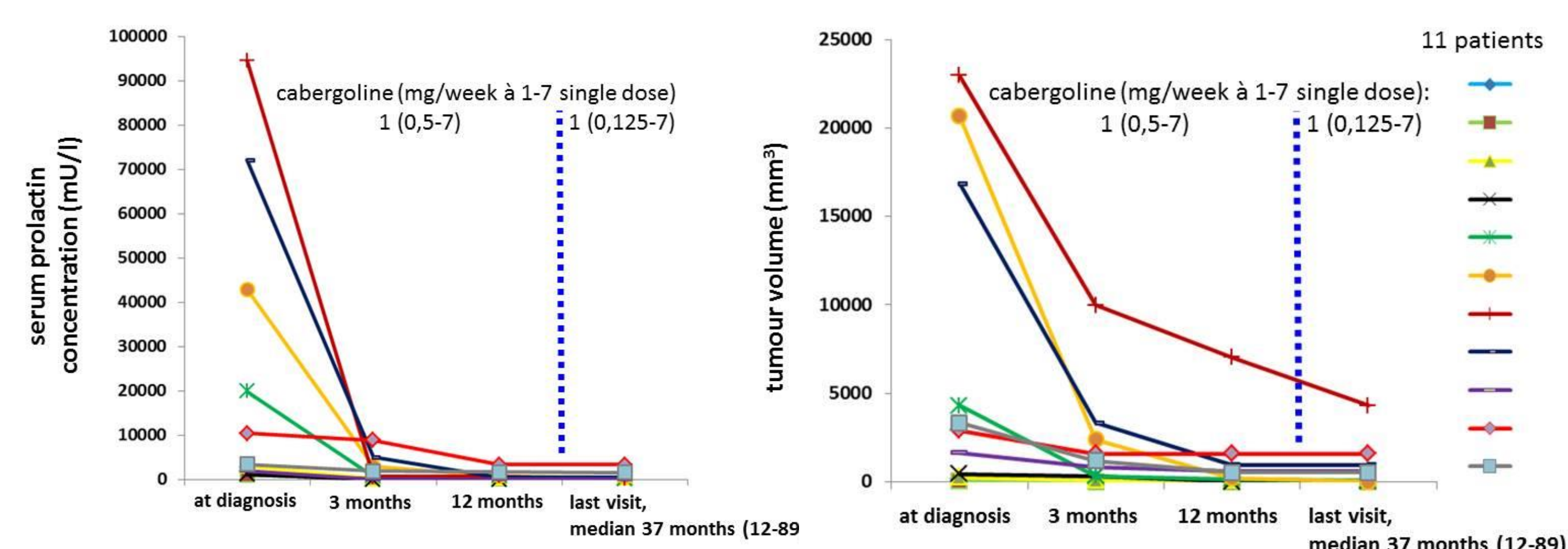


Figure 3: Serum prolactin concentrations (a) and tumour volume (b) at time of diagnosis and at 3 months, 12 months and at the latest visit after treatment start with cabergoline (PROLA, n=11)

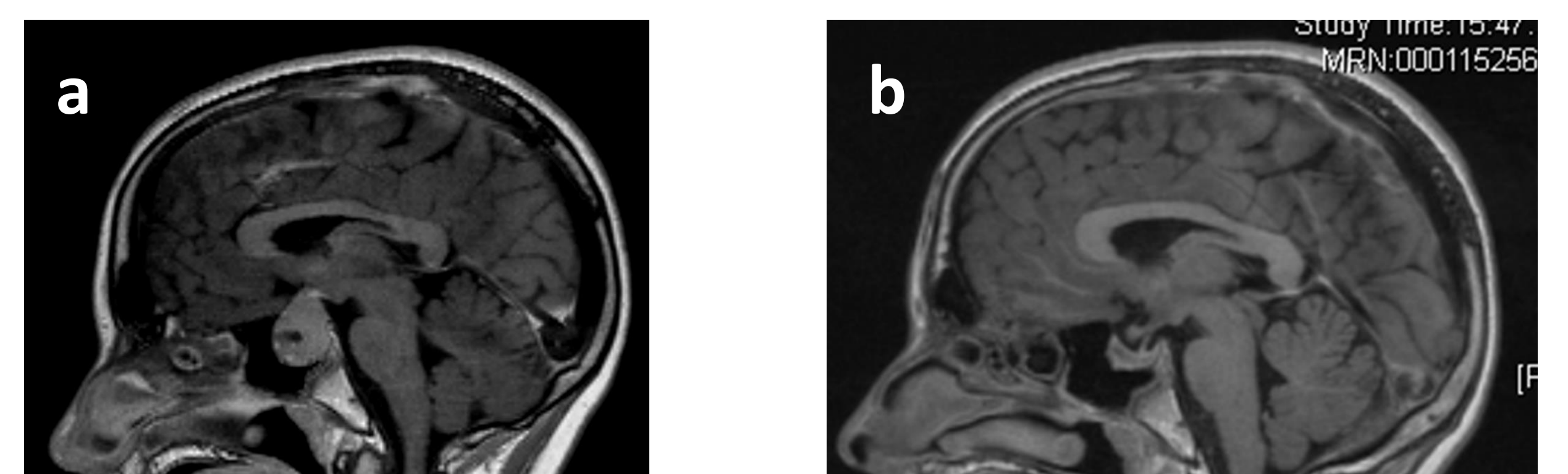


Fig. 4: cMRI (T1): 15.7-year old boy with macroprolactinoma (a) at diagnosis, (b) after 12 months treatment with cabergoline 4mg/week in 3 single doses