

Antonia Dastamani¹, Ashraf Ederies², Kristian Aquilina³, Neil Dorward⁴, Márta Korbonits⁵, Helen A. Spoudeas¹


1. Department of Paediatric Neuroendocrinology Great Ormond Street Hospital for Children NHS Trust

2. Department of Neuroradiology Great Ormond Street Hospital for Children NHS Trust

3. Department of Neurosurgery Great Ormond Street Hospital for Children NHS Trust

4. Department of Neurology and Neurosurgery University College London Hospital

5. Department of Endocrinology, William Harvey Research Institute, Barts and the London School of Medicine, Queen Mary University of London



Introduction

- Nonsurgical development of nasal cerebrospinal fluid (CSF) leaks may occur in the setting of pituitary adenomas, especially following a favorable response of invasive prolactinomas to initiation of Dopamine Agonist (DA) therapy.
- Cerebrospinal fluid leakage is well described in adults following dopamine agonist treatment.
- A literature search identified 38 case reports of adults aged 24 to 60 years with DA-induced CSF rhinorrhoea (1,2).

Aim

- To report the first case of cabergoline induced CSF rhinorrhoea in a peri-pubertal girl with an invasive macroprolactinoma and negative screening for *MEN1/AIP* mutation.

Case description

- A girl aged 13.8 years presented with headaches and secondary amenorrhea.
- Pituitary MRI revealed a large pituitary macroadenoma, invading the sphenoid sinus and elevating the optic chiasm (Figure 1A,B).
- Thyroid and adrenal reserve was normal while she had growth hormone deficiency (Table1,2).
- There was no family history of pituitary-related disease and *MEN1* and *AIP* genetic testing was normal.
- She was commenced on cabergoline at 0.5mg twice a week with prolactin drop to less than 3% of original value and significant tumour size drop (Diagram 1).
- She developed a CSF leak, which was managed surgically.
- Tumour biopsy confirmed a prolactinoma and was low Ki-67 staining.
- Postoperatively her prolactin levels normalized. Surgery

Table 1,2. Endocrine investigation at presentation, 2 months post cabergoline treatment, post-surgery and update now

	Presenting 14/4/16	Interim 23/6/16	Post-operative 1/7/16	Latest 22/9/17
IGF-1 ng/ml [220-972]	187	185		304
IGF-BP3 mg/L [3.3-10]	3.75	3.29		4.91
Cortisol nmol/L [171-536]	243	254	585	138
ACTH ng/L [10-50]	37.3	31.9	43.1	24
LH IU/L [0.8-1.3]	0.3	0.2	0.3	5.0
FSH IU/L [0.6-2.4]	0.9	0.2	0.9	4.2
Oestradiol pmol/l	92		44	142
TSH mU/L [<6.0]	1.0	0.9	1.9	1.1
FT4 pmol/L [10.8 - 19.0]	16.1	15.2	34.1	11.0
Prolactin mU/L [58-602]	106,064	2,841	969	358
	Decreased with DA overnight 33,793			
Na mmol/L [133-146]	142		139	
Plasma Osmo. MOsmo/Kg [282-300]	285	297	294	
Urine Osmo. MOsmo/Kg	1025	1025	580	
Urine Na mmol/L	204		174	
CAB, Dose per week	NO	1mg	1mg	1mg

Diagram 1. Response of the serum prolactin level to cabergoline treatment over time

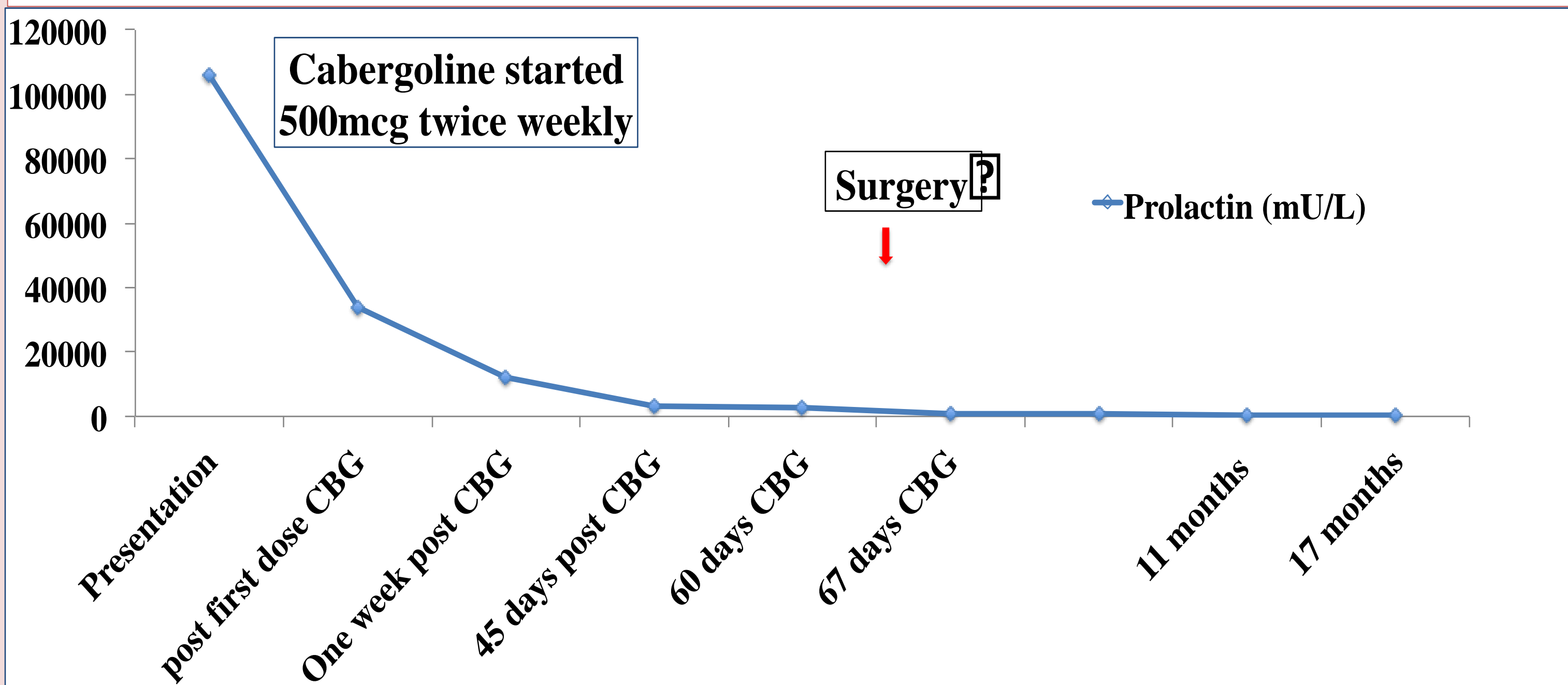


Table 2. Dynamic Endocrine tests: Glucagon test, LHRH test

Time, minutes	-30	0	30	60	90	120	150	180
Glucose, mmol/L	4.2	4.6	6.6	4.6	4.6	4.3	4.1	3.9
GH, ng/ml	<0.1	<0.1	<0.1	<0.1	<0.1	<0.1	1.1	0.8
Cortisol, nmol/L	237	203				187	149	204
LH, IU/L		0.3	27.3	19.2				
FSH, IU/L		0.9	6.2	6.7				

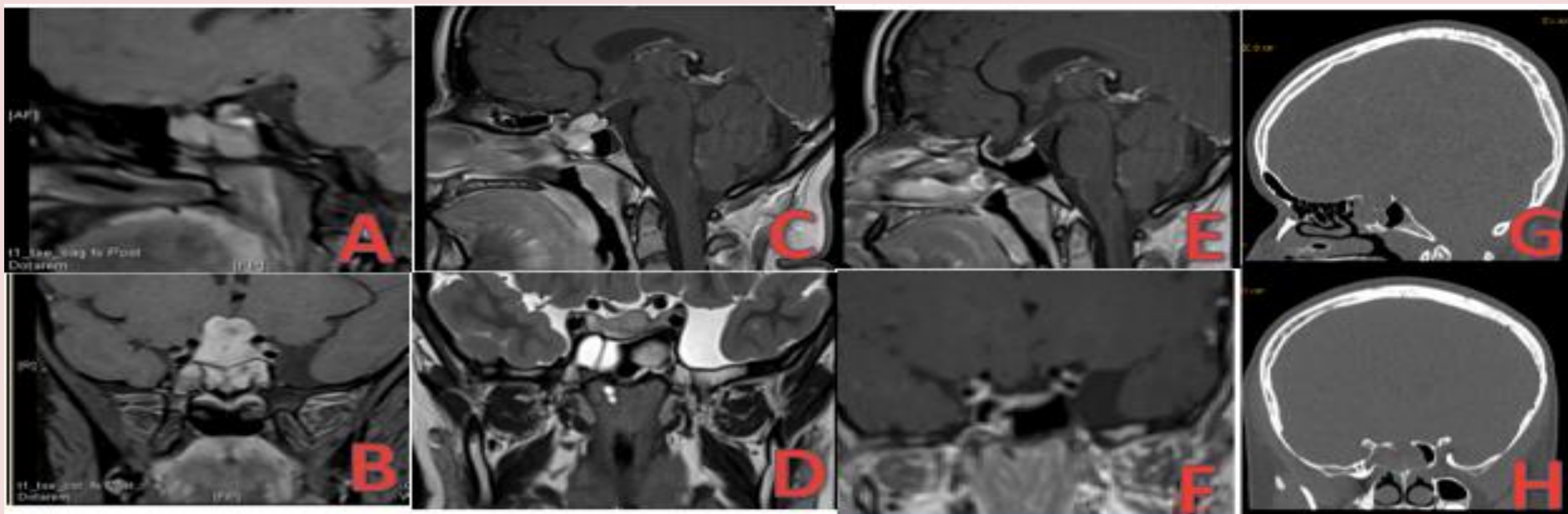
Figure 1. MRI coronal / sagittal contrast enhanced T1w of the pituitary region Surgery

A, B at presentation: A large 21mm x 17mm x 25mm pituitary macroadenoma was identified at the initial pituitary MRI extending upwards and outwards to stretch the optic chiasm and pituitary stalk and downwards towards the base of skull without obvious bony invasion. The posterior pituitary bright spot was present.

C, D 2 months after treatment with cabergoline: the pituitary macroadenoma was significantly smaller (dimensions 20.68mm x 16.95mm). It no longer compressed the anterior visual pathways and the residual tumour barely rose out of the enlarged pituitary fossa. The extent of disease in the sphenoid bone was also reduced. There was no cavernous sinus invasion.

E, F 9 months after treatment with cabergoline: the volume of residual tumour has decreased significantly once again. On this occasion, there is a normal amount of pituitary tissue in an enlarged pituitary fossa. It is therefore not possible to determine how much if any identifiable residual adenoma remains present.

G, H Head CT scan showed a large bone defect in the floor of the sella.



Conclusions

- ✓ We report the first case of cabergoline induced CSF rhinorrhoea in a peri-pubertal child with an invasive macroprolactinoma and negative for *MEN1* and *AIP* mutation screening.
- ✓ Careful observation, high resolution head CT for assessing base of skull erosion, and patient advice to be alert for nasal discharge is needed in patients with invasive and highly cabergoline-sensitive macroprolactinomas with inferior extension, in order to promptly diagnose and surgically treat a nonsurgical CSF leak resulting from tumour shrinkage.

References

1. Prague JK, Ward CL, Mustafa OG, Whitelaw BC, King A, Thomas NW, Gilbert J Delayed presentation of late-onset cerebrospinal fluid rhinorrhoea following dopamine agonist therapy for giant prolactinoma. *Endocrinol Diabetes Metab Case Rep.* 2014; 2014:140020.
2. Grace Lam, Vivek Mehta, Gabriel Zada, Spontaneous and medically induced cerebrospinal fluid leakage in the setting of pituitary adenomas: review of the literature *Neurosurgical Focus* 2012; Vol. 32: No. 6 -Page E2

