



# A 46,XX FEMALE WITH WT1 MUTATION, CONGENITAL NEPHROTIC SYNDROME AND A COMPLEX DSD

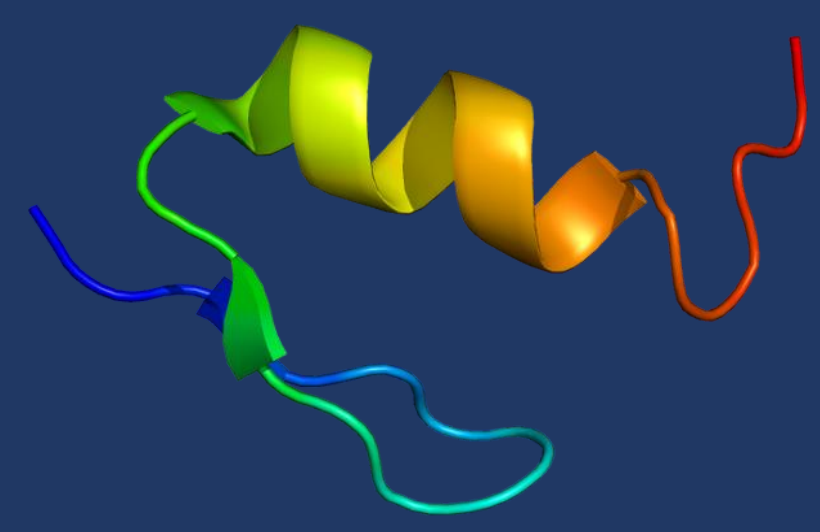
Sara Ciccone<sup>1,2</sup>, Carla Bizzarri<sup>1</sup>, Stefano Picca<sup>3</sup>, Cinzia Orazi<sup>4</sup>, Chiara Lucchetti<sup>5</sup>, Marzo Cappa<sup>1</sup>

<sup>1</sup>Endocrinology and diabetes unit, Bambino Gesù Pediatric Hospital, Rome, Italy <sup>2</sup>Pediatric Unit, Bufalini Hospital, Cesena, Italy

<sup>3</sup>Nephrology Unit, Bambino Gesù Pediatric Hospital, Rome, Italy <sup>4</sup>Radiology Unit, Bambino Gesù Pediatric Hospital, Rome, Italy

<sup>5</sup>Gynecology Unit, Bambino Gesù Pediatric Hospital, Rome, Italy

**WT1** (Wilms tumor suppressor gene 1) is essential for **kidney and gonadal development**. WT1 gene mutations are associated with two syndromes called Denys-Drash (DDS) and Frasier (FS) that clinically overlap and differ in the type of mutation and in the age at nephropathy onset. In **46,XY** subjects, WT1 mutations are associated with steroid-resistant nephrotic syndrome (NS), Wilms tumor, disorder of sex development (DSD) with dysgenetic gonads and gonadoblastoma risk. On the contrary, the impact of WT1 gene on the genital development of **46,XX** subjects is not clear.



|                                     | Denys-Drash Syndrome        | Frasier Syndrome            |
|-------------------------------------|-----------------------------|-----------------------------|
| Genitalia                           | 46,XY DSD                   | 46,XY partial DSD           |
| Glomerular damage on biopsy         | Diffuse mesangial sclerosis | Focal segmental sclerosis   |
| End-stage renal failure progression | 0-3 years                   | 10-20 years                 |
| Neoplastic Risk                     |                             |                             |
| • Wilms Tumor                       | ++ age at onset 18 months   | +                           |
| • Gonadoblastoma                    | +                           | ++ age at onset 15-20 years |

## Case report

### NEPHROPATHY

Kidney failure due to congenital nephrotic syndrome  
first months: peritoneal dialysis  
3 years: kidney transplantation  
5 years: acute rejection  
12 years: regular hemodialysis

### DSD

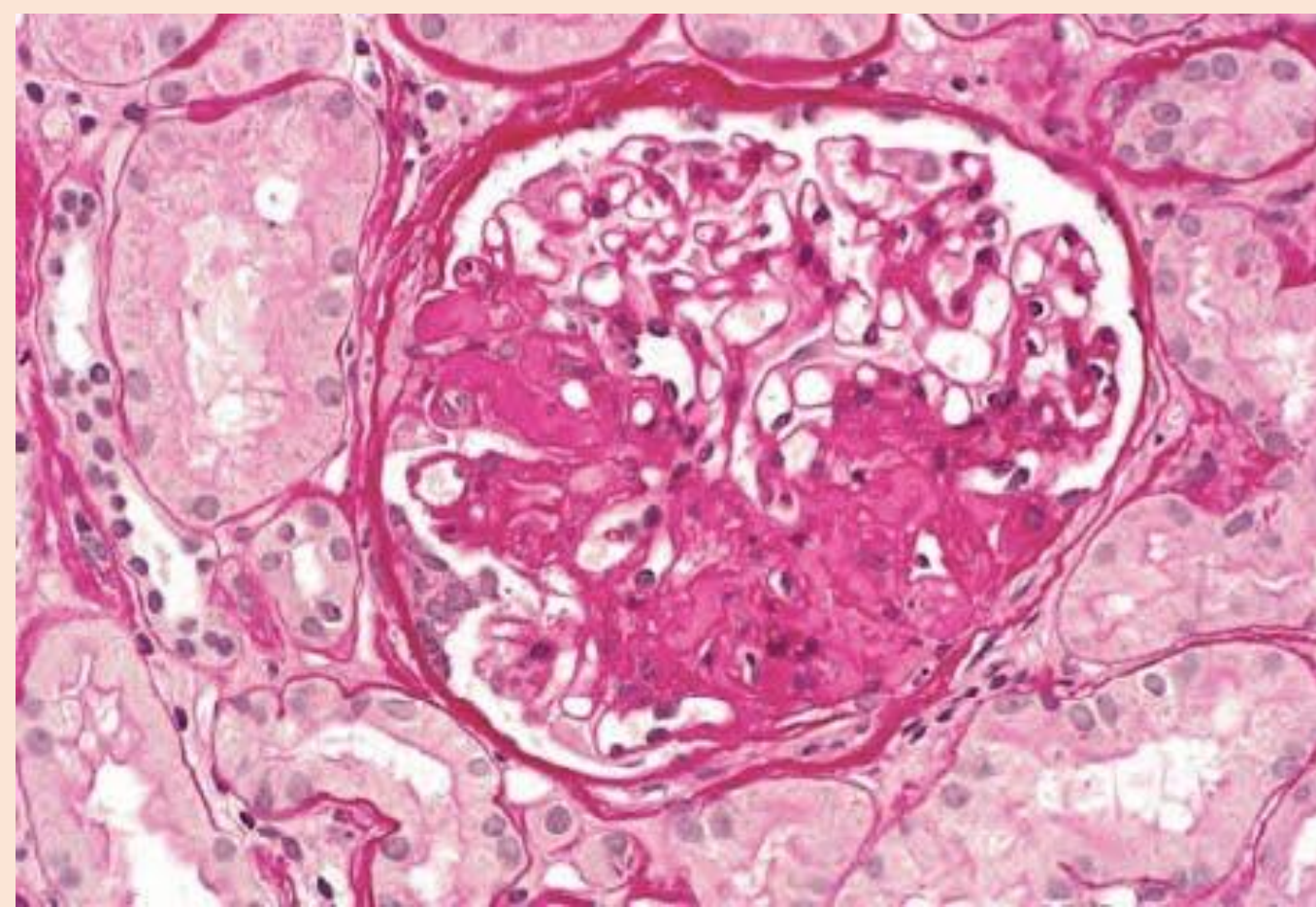
14 years: the girl was referred to endocrinological clinic for primary amenorrhea despite a complete pubertal development (Tanner stage 5). She presented androgenetic alopecia and voice deepening.

Weight: 44 kg (25th), height: 161.4 (50-75th), BMI: 16.9 kg/mq (10-25th).

Bone age = chronological age

**WT1 heterozygous mutation c.1097>A\***

**46,XX female karyotype**



Kidney biopsy at onset: mesangial proliferative glomerulonephritis with focal-segmental glomerular sclerosis

**Endocrine tests:** pubertal gonadotrophins (FSH 8.8mU/ml, LH 3.6mU/ml), estradiol 92.8pg/ml, testosterone 190.2 ng/dl and anti-mullerian hormone 1.3ng/ml. Basal and post-ACTH adrenal androgens were normal.

**Pelvic ultrasound:** bilateral dysgenetic gonads in the inguinal canals, uterotubaric agenesis, vaginal atresia and urogenital sinus.

**Gonadectomy:** hypotrophic ovaries with cystic follicles and interstitial fibrosis.

\*producing the amino acid change Arg366His. This mutation had been described in 46,XY patients with Denys-Drash syndrome.

WT1 knockout mice lack gonads in both sexes, suggesting a role of the gene in the formation of the genital ridge, an early stage of development in which the gonad is still undifferentiated. Nowadays, little is known about the role of WT1 in the development of the female reproductive system. Sporadic cases of 46,XX females are reported with a WT1 mutation and minor abnormalities such as streak ovaries or bicornuate uterus. To our knowledge, this is the first report on a 46,XX female presenting heterozygous WT1 mutation, congenital nephrotic syndrome, and a complex DSD associated with gonadal dysgenesis.

Hoefele J, Kemper MJ, Schoenermarck U, et al. Truncating Wilms Tumor Suppressor Gene 1 Mutation in an XX Female with AdultOnset FocalSegmental Glomerulosclerosis and Streak Ovaries: A Case Report. *Nephron*. 2017;135:72-76.

Hastie ND. Wilms' tumour 1 (WT1) in development, homeostasis and disease. *Development*. 2017 Aug 15;144:2862-2872.