

M.Azgal <sup>a</sup>(Mme), N.Bouhours-Nouet <sup>a</sup>(Dr), O.Camard <sup>c</sup> (Dr) , I.ALLIX <sup>b</sup> (Dr) , R.Coutant <sup>a</sup> (Pr).

*a: Department of Pediatric Endocrinology CHU Angers; b: Department of Endocrinology Diabetes Nutrition CHU Angers; c: Department of Pediatric CHU Niort*

## INTRODUCTION

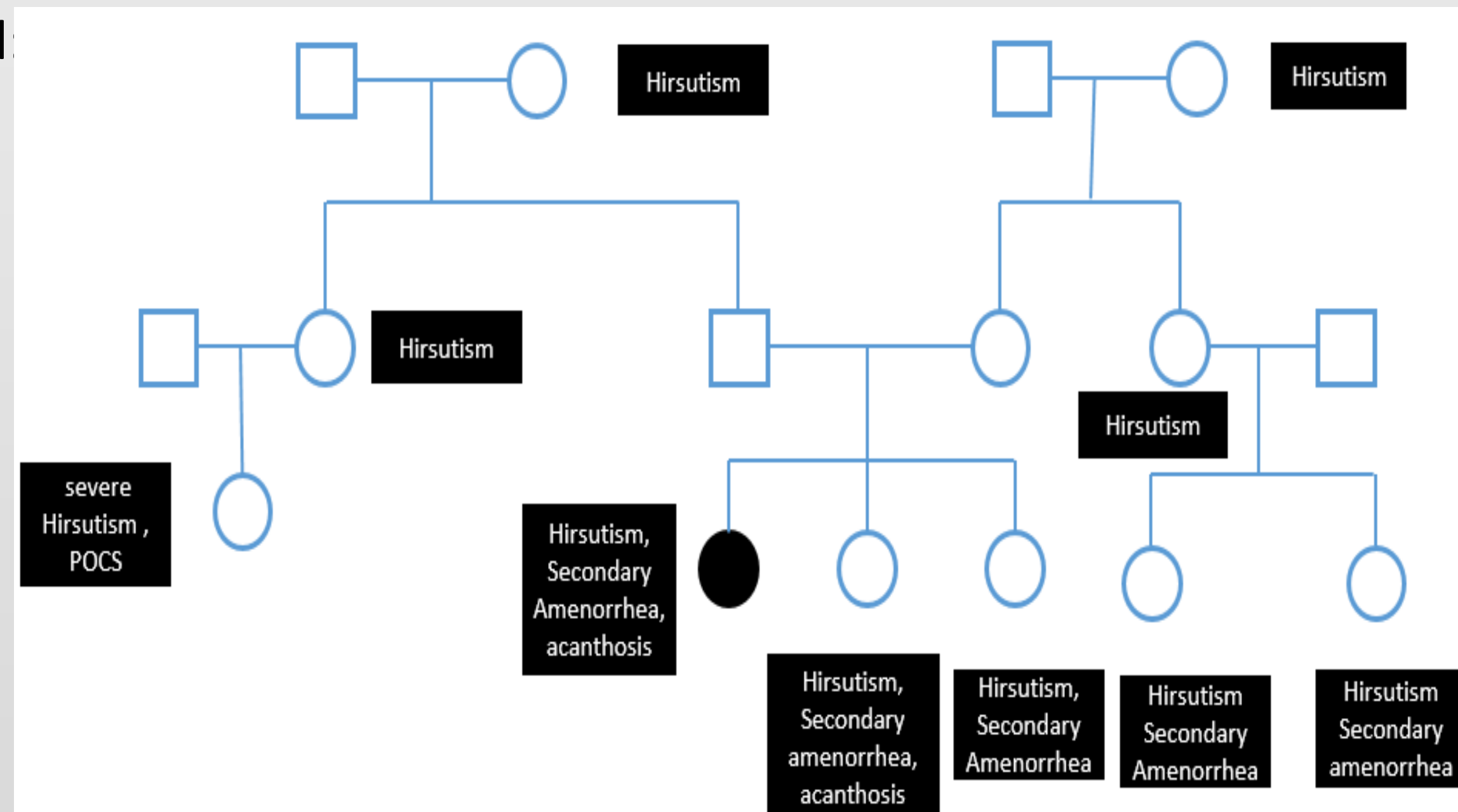
Insulin resistance is most often found in obese patients with metabolic syndrome, and is considered as due to the excess fat mass. However when the origin is genetic, the BMI is normal and it can be accompanied by acanthosis nigricans, hyperandrogenism and hyperinsulinism.

We report here two cases of insulin receptor mutation whose presenting signs were less noticeable.

### Case report 1

- A 16-year-old girl (born eutrophic) consulted for hirsutism and secondary amenorrhea attributed to PCOS.
- No personal medical or surgical history.

- Familial background  
Multiple cases of hirsutism

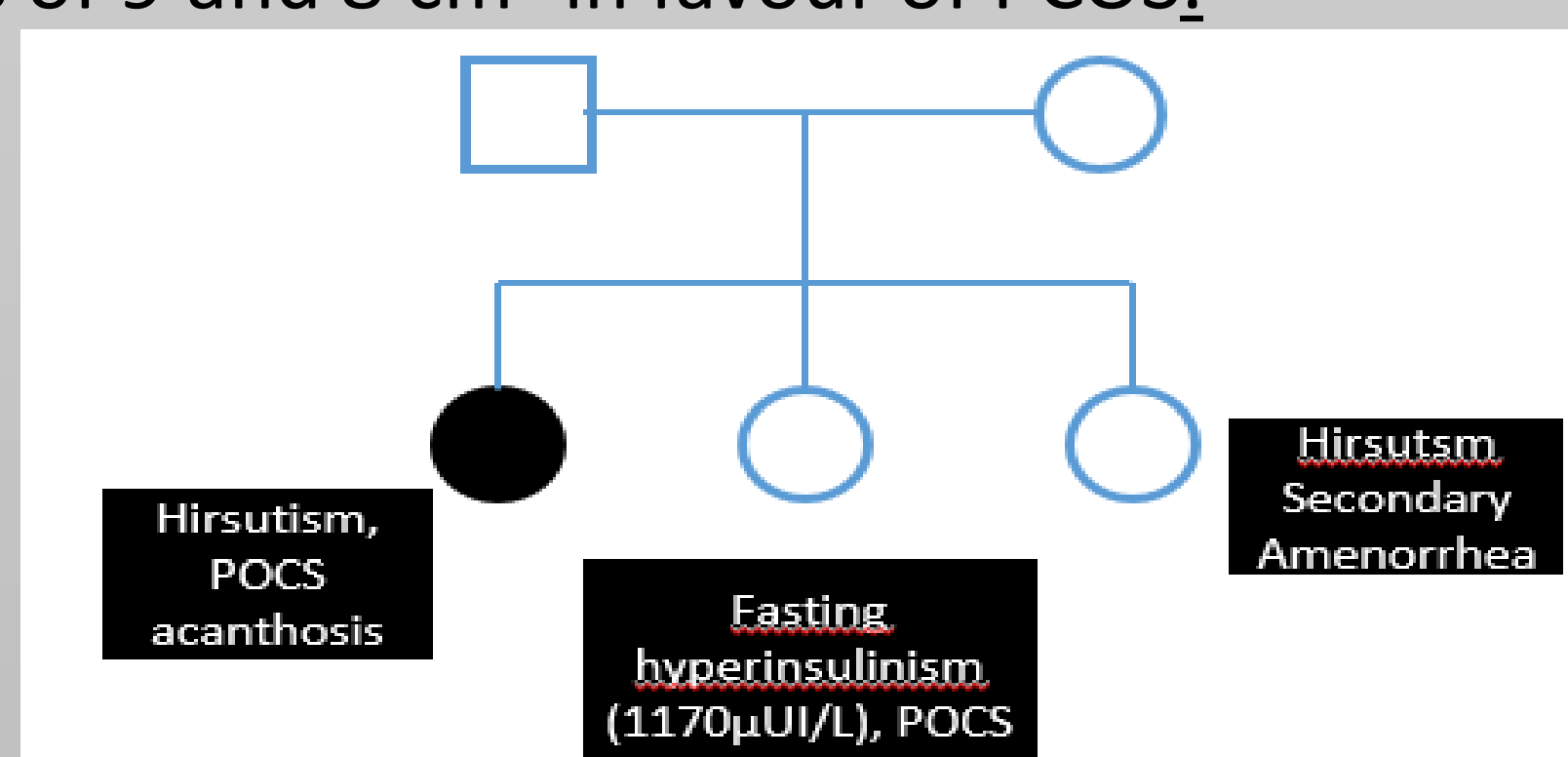


- Exam 44,7 kg, 158,8 cm (BMI 17,7 kg/m<sup>2</sup>), axillary and inguinal acanthosis nigricans, mild acne, discreet hirsutism (Ferriman score 7), pubertal stage A4P4S4, no lipodystrophy.

OGTT	T0	T30	T60	T90	T120
BG mmol/L	3,96	8,3	6,2	6,3	5,72
Insulinemia (μUI/L)	81	1000	1120	1080	1400

- Biology :  
Fasting glucose : 4 mmol/L  
Fasting insulinemia: 170 μUI/L  
OGTT was performed:  
Testosterone level 0,6 ng/mL (N < 0.5), AMH 23,95 ng/ml, 170HP normal
- Pelvic ultrasound showed large ovaries of 9 and 8 cm<sup>2</sup> in favour of PCOS.

Overall : sever hyperinsulinism with normal BMI, PCOS and familial cases of PCOS

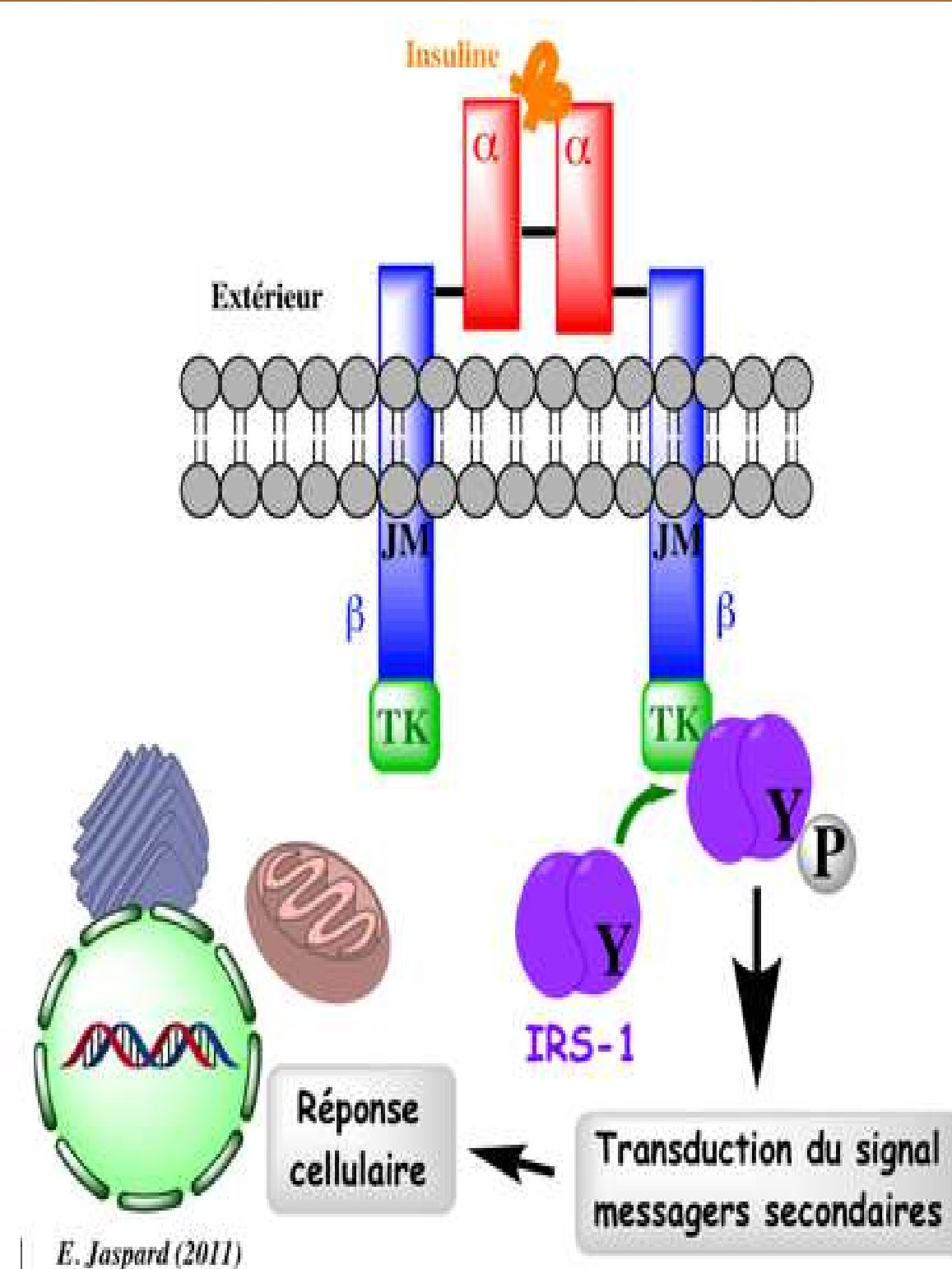


Exploration of the family : familial hyperinsulinemia

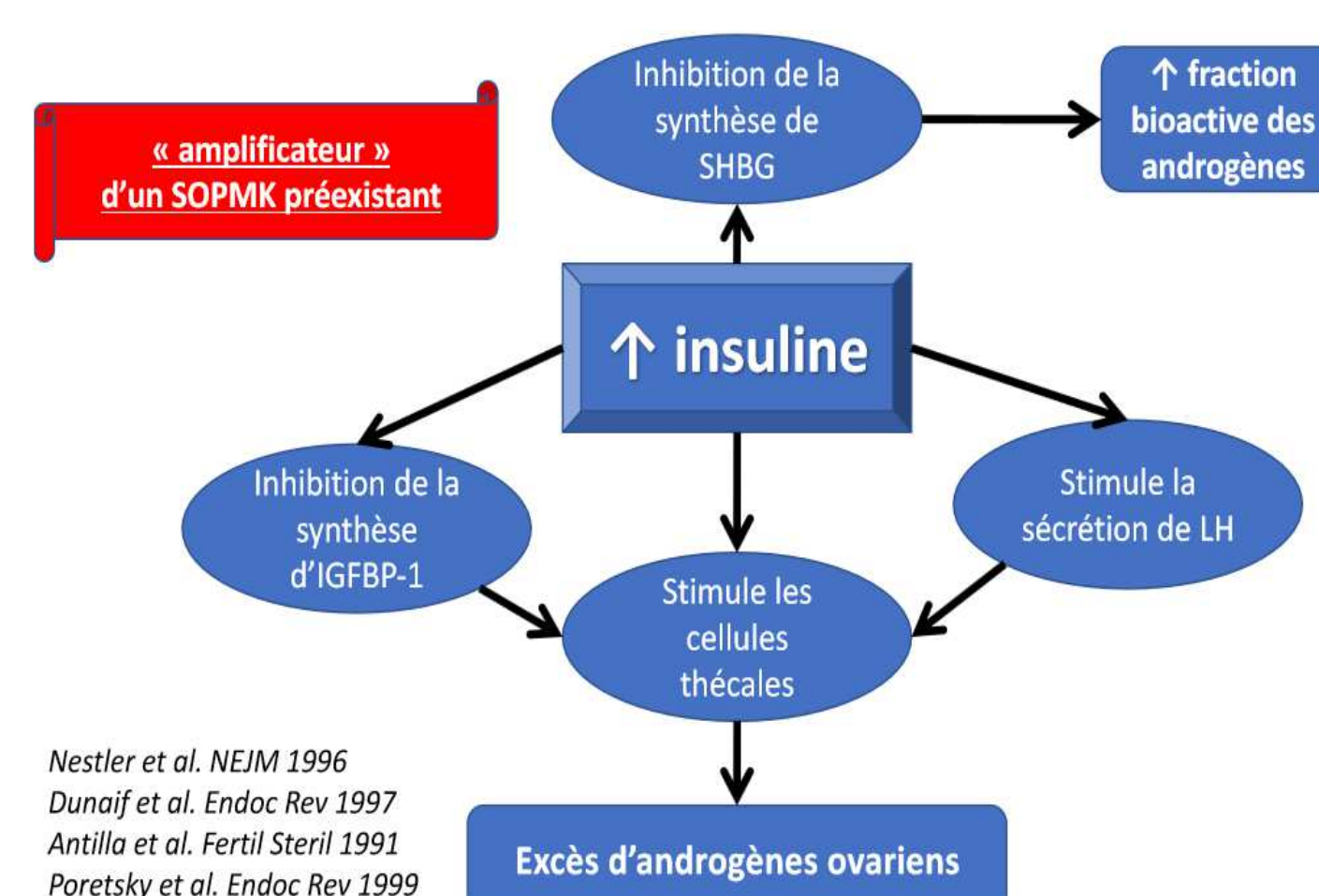
## Suspected abnormality in the insulin signaling pathway: Insulin receptor gene analysis

Heterozygote mutation of the INSR gene exon 17 (3164c>T), described in type A insulin resistance syndrome

Treatment : Metformine, improvement of hirsutism with acetate de cytoperone/estrogen

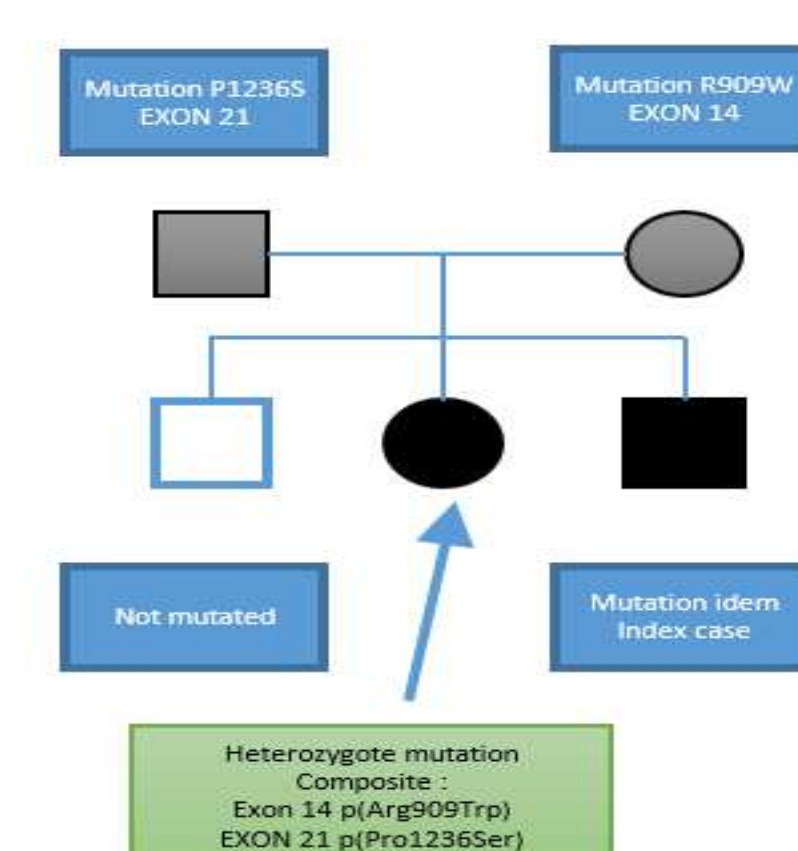


The human insulin receptor is composed of 4 glycosylated peptides linked by disulfide bridges:  
2 alpha sub units that ensure the attachment of the hormone to tissues:  
2 beta sub units with TK activity  
The mutations described affect the beta sub unit



Nestler et al. NEJM 1996  
Dunaif et al. Endoc Rev 1997  
Antilla et al. Fertil Steril 1991  
Poretsky et al. Endoc Rev 1999

Heterozygote composite mutation of INSR gene exon 14 (R909W), and exon 21 (P1236S)



Overall : SGA without hypoglycemia during the insulin tolerance test, hyperinsulinism and PCOS with normal BMI

### Case report 2

- A 13-year-old girl was referred for short stature (Height -2.5 SDS) with SGA ( birth length 44 cm, at gestational age 41 weeks), no medical surgical history.

- Clinical examination was normal, pubertal stage was A2P3S3, 33,6 kg, 142,5 cm (BMI 17,2kg/m<sup>2</sup>).

- Biology : IGF1 : 307 ng/ml

- The glycemic nadir was 3,7 mmol/l (no hypoglycemia), and GH peak was 8 ng/ml during the insulin tolerance test (0.1 U/kg). All the investigations were normal, and the short stature was attributed to idiopathic SGA

- At the age of 16, she was seen for acanthosis nigricans and primary amenorrhea. Pubertal stage was A4P4S4, and Ferriman score was 4, normal BMI, no lipodystrophy.

- Normal lipid profil and HBA1c

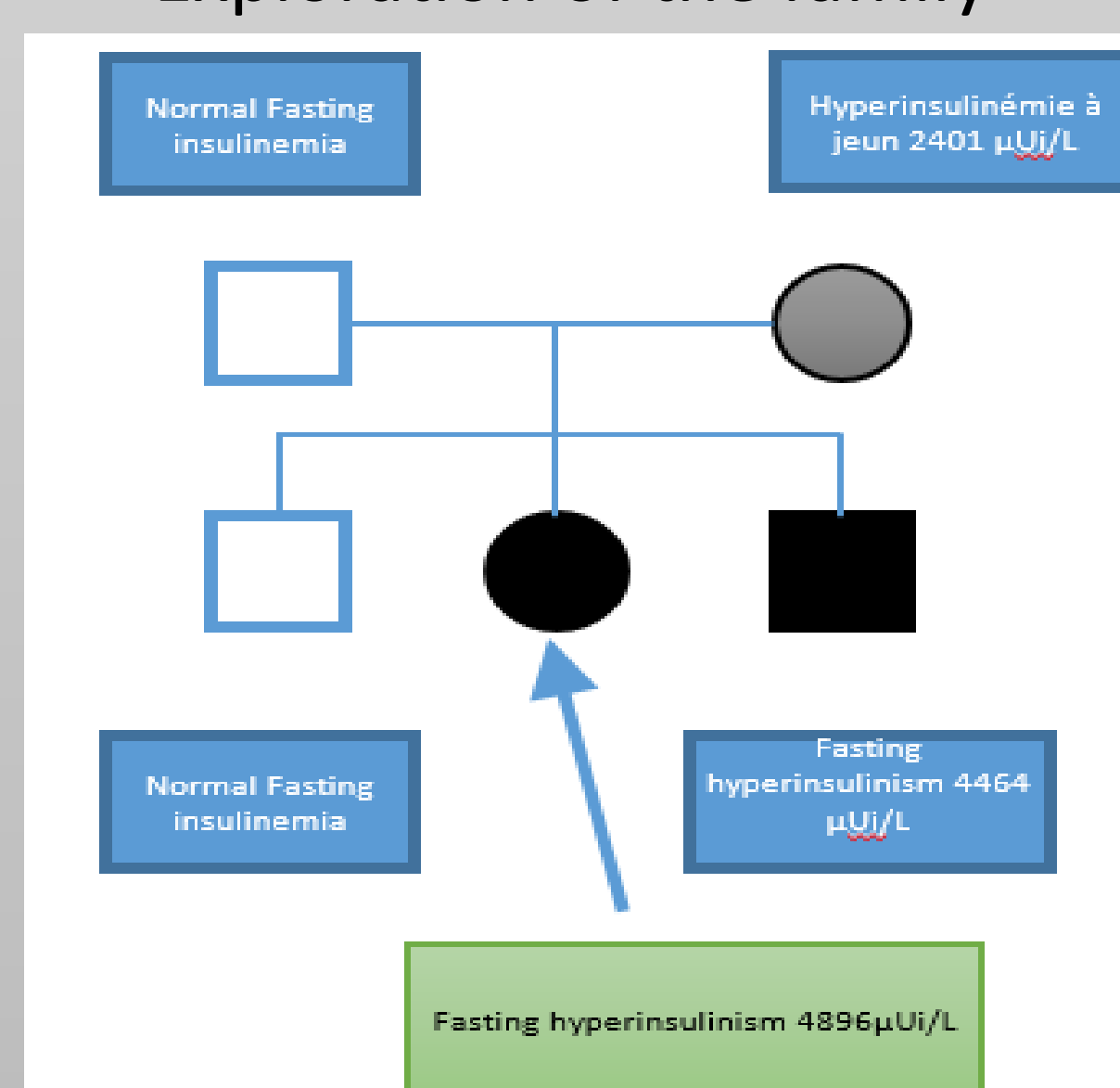
- Testosterone 0,5 ng/ml (N < 0.5), FSH 4,7 UI/L, LH 11,8 UI/L, SDHEA 4mg/L, 17OHP 1,48 μg/L

- OGTT:

OGTT	T0	T30	T60	T90	T120
Blood glucose mmol/L)	3,68	7,86	11	8,8	7,37
Insulinemia (μUI/L)	102	3100	6500	7900	3100

- Pelvic ultrasound showed large ovaries of 10 and 8 cm<sup>2</sup> suggesting PCOS.

### Exploration of the family



## Take home message

In short stature with SGA as well as in familial cases of PCOS with normal BMI, we suggest to routinely measure fasting insulinemia, as it may lead to the diagnosis of pathological insulin resistance due to insulin receptor mutation.