

A paternally inherited NR5A1 mutation in a case of 46,XY partial gonadal dysgenesis

Andréa Trevas Maciel-Guerra, Helena Fabbri-Scallet, Gil Guerra-Junior, Maricilda Palandi de Mello

Interdisciplinary Group of Study of Disorders of Sex Development, State University of Campinas, SP, Brazil



Introduction

Steroidogenic factor-1 (SF1), encoded by *NR5A1*, is a protein that regulates several steps of adrenal and gonadal development and plays a central role in sex development, steroidogenesis, and reproduction in both males and females. *NR5A1* mutations have been described in a diverse spectrum of XY and XX disorders of sex development (DSD). Most variants described to date are heterozygous, either *de novo* or maternally inherited in an autosomal dominant sex-limited manner, in which the mother may present premature ovarian insufficiency or remain asymptomatic. Variable expressivity and incomplete penetrance have made genotype-phenotype correlations difficult to establish. Furthermore, rare cases of paternal inheritance have also been reported, where the father may be unaffected or mildly undervirilized¹. We report on a case of XY Partial Gonadal Dysgenesis with paternal inheritance of a *NR5A1* variant.

Case report

A 17-year-old girl was referred to us due to primary amenorrhea and absence of secondary female sex characteristics. She was born at term to healthy unrelated parents after an uneventful pregnancy with a birth weight of 3085 g and length 51 cm. Her neuromotor development was normal, there were no significant health problems and family history was unremarkable. On physical examination weight was 87.5 Kg and height 184 cm. She had a 3 cm-phallus, a female urethra and a vaginal opening; no gonads were palpable, and pubertal stage was B1P3. Karyotype was 46,XY, there were high FSH and LH concentrations, low estradiol, low serum testosterone and no accumulation of testosterone precursors. Müllerian derivatives could not be identified on pelvic ultrasound and pelvic MRI. She was subject to bilateral laparoscopic gonadectomy and pathology revealed bilateral dysgenetic testes. Estrogen replacement therapy for puberty induction was initiated and vaginal dilation will be performed in due time.

Sequencing of *NR5A1* revealed a heterozygous 17-bp deletion (c.268_285 p.M98Gfs*44) in exon 4. This novel frameshift mutation, which is located in the DNA binding domain of SF1, introduces a premature stop codon at the residue 142 (Figure). This variant was inherited from the unaffected father. Adrenal function was evaluated in both of them, with normal results.

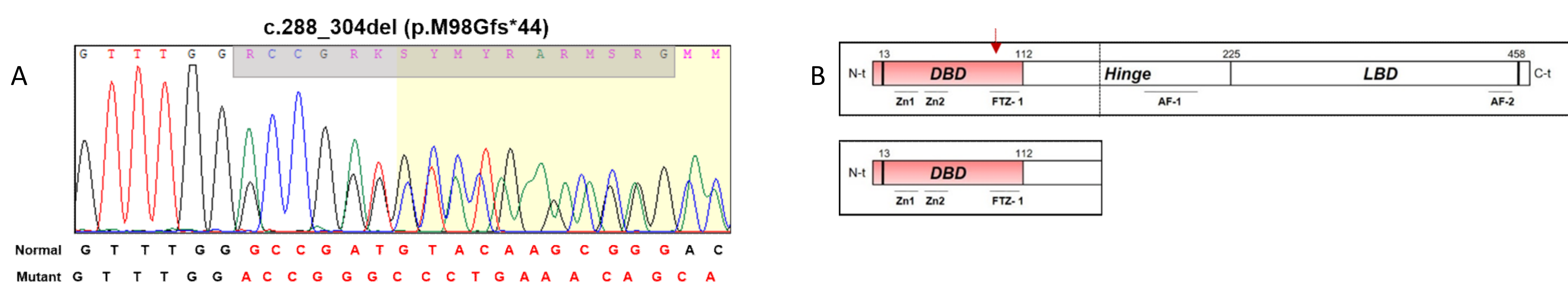


Figure - A) Part of electropherogram sequence showing the heterozygous c.288_304del mutation within exon 4 of *NR5A1* gene. B) Structure of SF-1 protein. Red arrow points to the position of substitute amino acid within DNA-binding domain (DBD). p.M98Gfs*34 mutation would create a premature translation termination codon within the hinge region.

Discussion

Paternal inheritance of *NR5A1* mutations found in patients with 46,XY DSD has rarely been reported. A frameshift mutation c.1150delC, p.Leu384fsTer1² and a c.910G>A, p.E304K variant³ were both inherited from unaffected fathers. A heterozygous 8-bp deletion c.630_637del, p.Tyr211Profs*12 was inherited from the maternal grandfather, who had been subject to hypospadias repair in infancy but had spontaneously fathered two children⁴. Finally, a heterozygous c.938G>A, p.Arg313Hys variant was detected in four individuals with severe hypospadias belonging to the same family, one of whom had fathered five children⁵. Together with our own case, these findings add further complexity to genetic studies of *NR5A1* in DSD and point out to the need to perform sequencing of all family members of a patient with a *NR5A1* variant, irrespective of genetic sex and phenotype.

References

1. Robevska G et al. Hum Mutat. 2018;39(1):124-39.
2. Swartz JM et al. Horm Res Paediatr. 2017; 87:264-70.
3. Yagi H et al. Endocr J 2015;62:289-95.
4. Baetens D et al. Orphanet J Rare Dis 2014;9: 209.
5. Ciaccio M et al. Horm Res Paediatr 2012;78:119-26.