

# Multinodular goiter in childhood: look for DICER1 mutation

V. Suteau<sup>\*a</sup> (Dr), I. Souto<sup>b</sup> (Dr), N. Bouhours-Nouet<sup>c</sup> (Dr), S. Proust<sup>d</sup> (Dr), A. Donzeau<sup>c</sup> (Dr), F. Savagner<sup>e</sup> (Pr)  
P. Rodien<sup>a</sup> (Pr), R. Coutant<sup>c</sup> (Pr)

<sup>a</sup> Department of Endocrinology, University hospital of Angers, France; <sup>b</sup> Department of Pediatrics, Hospital of Le Mans; France; <sup>c</sup> Department of Pediatric Endocrinology, University hospital of Angers, France; <sup>d</sup> Department of Pediatric Oncology, University hospital of Angers, France; <sup>e</sup> Molecular Endocrinology-IFB, University hospital of Toulouse, France

\* valentine.courant@chu-angers.fr

## Introduction :

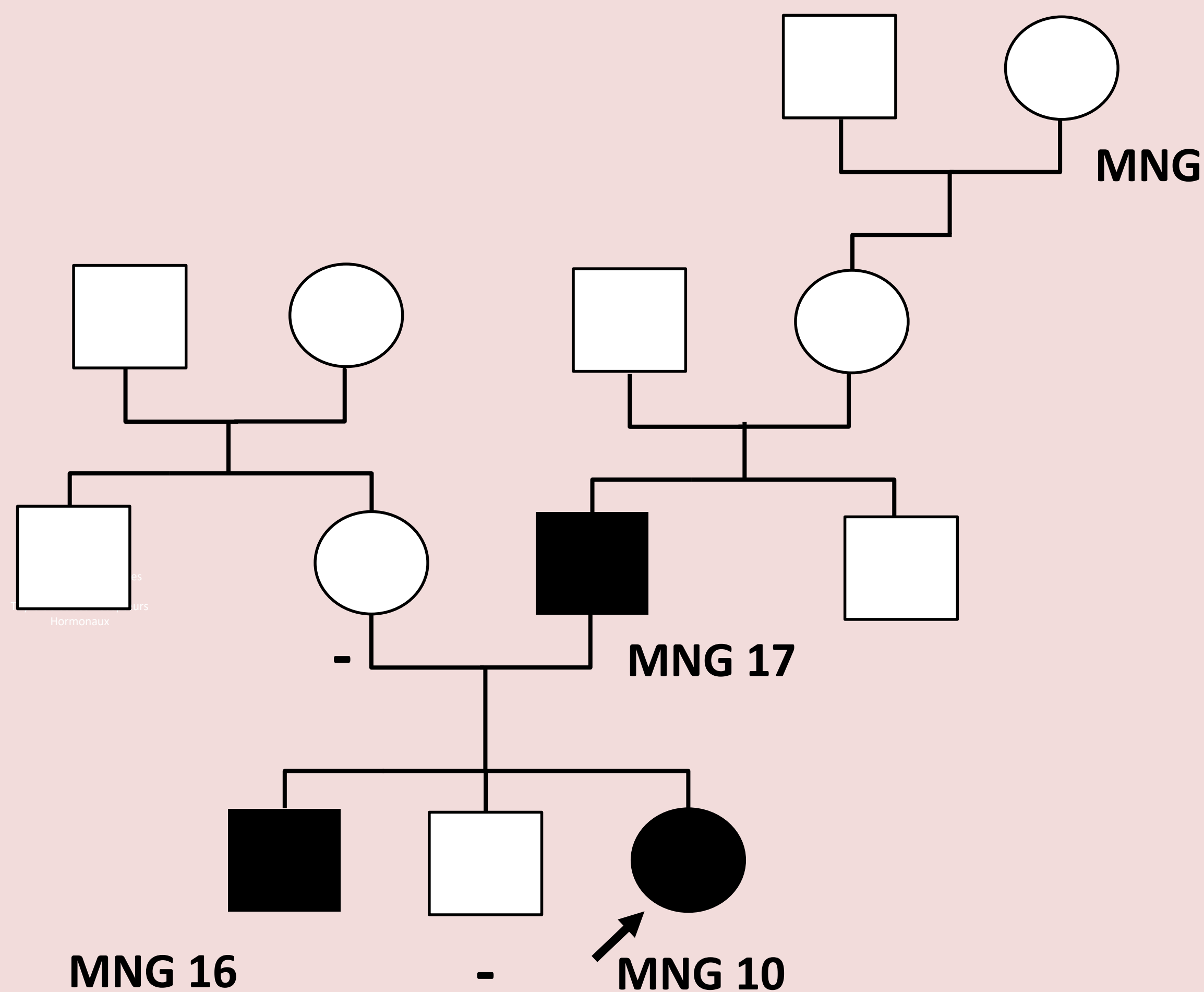
Multinodular goiter is infrequent in children. Mutations in the *DICER1* gene are associated with thyroid abnormalities, including multinodular goiter and differentiated carcinoma (1).

Here, we present the case of two families with novel *DICER1* mutations and familial history of nodules or multinodular goiter in adolescence.

## Observations :

### Cas 1

A 10-year-old female presented a **multinodular goiter** with a **thyroid nodule** measuring 22 mm, discovered due to neck pain. TSH, Free T3, Free T4 were in the normal range and thyroid auto antibodies were negative. Fine needle cytology of the thyroid nodule revealed undetermined lesion in two samples. Therefore, she underwent a thyroidectomy. Histology revealed a benign follicular adenoma.



Familial medical history included an multinodular goiter (MNG) operated at the age of 15 in her brother and at age 19 in her father, and in maternal grandmother. There was not familial history of cancer.

Based on **familial history and young age, a hereditary predisposition syndrome** was suspected and genetic testing of *DICER1* was undertaken. A **novel heterozygous pathogen germ-line *DICER1* variant** was identified in Exon 4 (c.322C>T, p.Gln108Stop). This variant was predicted to be deleterious with a premature codon stop and a loss of protein function.

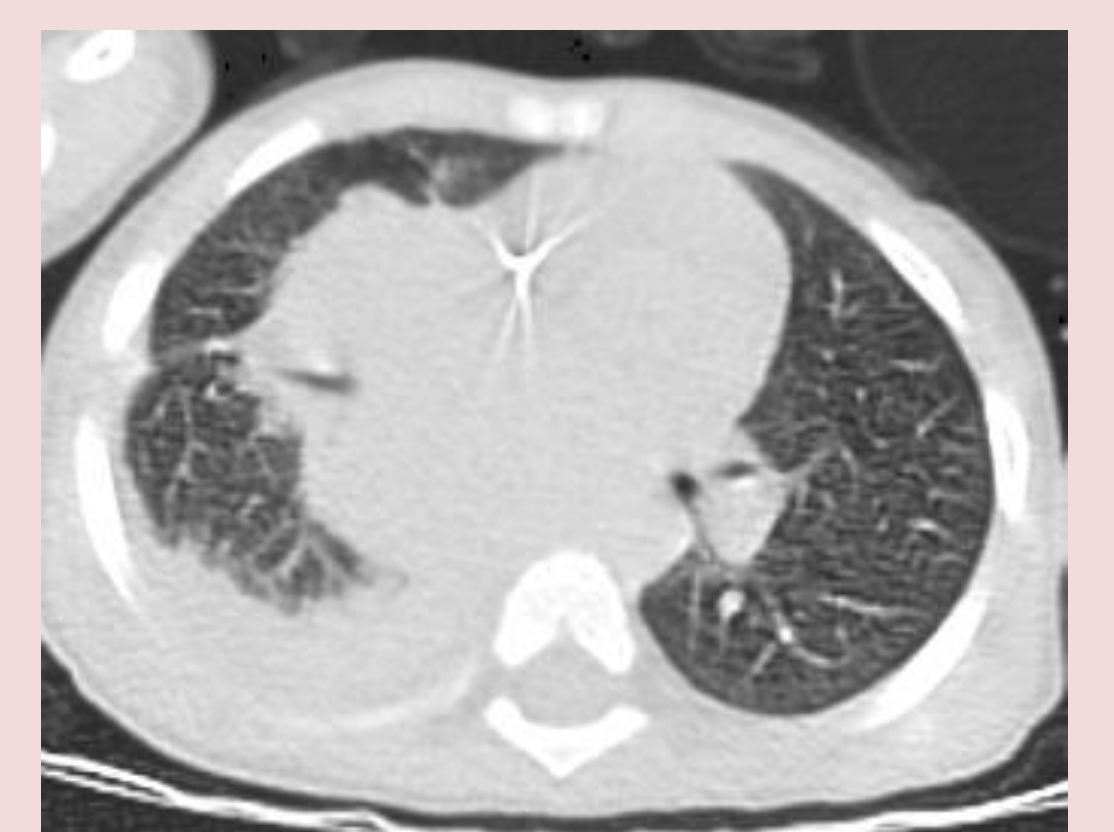The family survey confirmed that the two other family members with an history of multinodular goiter had the same pathogenic germ-line *DICER1* variant.

The extensive work-up (chest X-ray, transabdominal pelvic ultrasound in female) did not find other disorders associated with tumoral predisposition gene.

### Cas 2

A Two-year-old girl presented **pleuropulmonary blastoma**. Germ-line mutation screening of *DICER1* and TP53 was performed. None TP53 mutation was identified. A **novel heterozygous germ-line mutation** was identified in Exon 12 (c2692del, p.Glu898Lysfs\*10). Mutation was also identified in her mother.

Mother medical history revealed a left unilateral retinoblastoma at the age of three. She also underwent a thyroidectomy at the age of ten then fifteen for thyroid nodules. Her sister also underwent thyroid surgery at the age of seven years old, suggesting a **familial history of nodules in adolescence**.



## Discussion

Thyroid nodules and multinodular goiter was uncommon in pediatric population. **Familial cases, or the association with familial tumors**, should prompt the search for *DICER1* mutation. *DICER1* is a member of the ribonuclease type III family, producing microRNAs. Reduction of microRNAs leads to enhance tumorigenesis (2). *DICER1* mutation predispose to a variety of tumor types in children and young adults (1, 3-4). **Recent surveillance recommendations** have been established for detecting pleuropulmonary blastoma, ovarian sex cord-stromal tumors and other *DICER1*-associated tumors (5).

## References :

- (1) Capon F et al. Am J Hum Genet. 2000
- (2) Kumar MS et al. Nat Genet. 2007
- (3) Hill DA et al. Science. 2009
- (4) Schultz KA et al. GynecolOncol. 2011
- (5) Schultz KA et al. Clin Cancer Res. 2018

