




# AMIODARONE INDUCED HYPERTHYROIDISM IN A PEDIATRIC PATIENT



Bernardo Marques<sup>1</sup>, Sofia Oliveira<sup>2</sup>, Sérgio Laranjo<sup>3</sup>, Lurdes Lopes<sup>4</sup>

- 1 - Endocrinology Department - Portuguese Institute of Oncology, FG, Coimbra, Portugal
- 2 - Endocrinology, Diabetes and Metabolism Department - Centro Hospitalar de São João, EPE, Porto, Portugal
- 3 - Pediatric Cardiology Department - Centro Hospitalar de Lisboa Central, EPE, Lisbon, Portugal
- 4 - Pediatric Endocrinology Unit - Centro Hospitalar de Lisboa Central, Hospital Dona Estefânia, EPE, Lisbon, Portugal

57<sup>th</sup> ESPE 2018  
Meeting ATHENS GREECE  
27-29 September 2018

## Introduction

Thyroid dysfunction is the most common side effect of amiodarone therapy, ranging from subclinical changes to overt clinical thyrotoxicosis (AIT) and/or hypothyroidism (AIH). Two major types of AIT have been described: type I usually develops in multinodular goiter or in preexisting Graves' disease where an overload of iodine is responsible for the overproduction of thyroid hormones, and type II presents as a destructive thyroiditis, with release of pre-formed thyroid hormones. However, many cases are mixed-form AIT, encompassing several features of both type I and type II.

## Clinical Case:

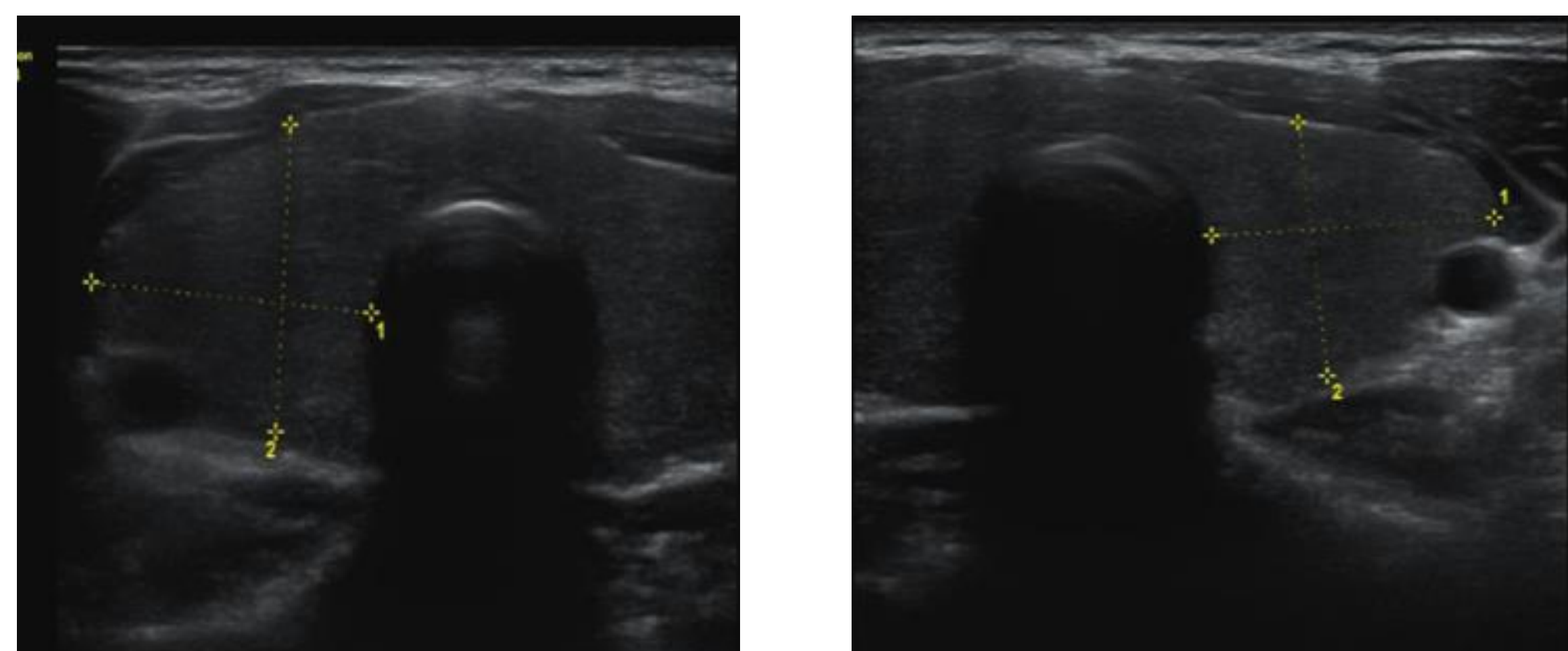
16 year old, male, with type 1 truncus arteriosus who underwent three cardiac surgical interventions.

- July 2015**
  - Complaints of fatigue and palpitations
  - 24h Holter monitoring: supraventricular tachycardia (200bpm)
- August 2015**
  - Amiodarone 200mg/day; normal thyroid function
- Octo. 2017**
  - Asthenia; loss of 4kg in weight in the previous 3 months

### Laboratory evaluation (20/10/2017):

- TSH <0.01 uUI/mL (0.47-3.41)
- FT4 2.83 pg/mL (0.89-1.32)
- FT3 7.92 pg/mL (2.25-3.85)
- Negative anti-thyroid antibodies

He was sent to our department and underwent thyroid ultrasound (24/10/2017), which was normal.



Images 1 and 2: Thyroid with globally hypoechoic texture, with no solid nodular nodules. No increase in vascularization. No latero-cervical adenopathies.

He was started on thiamazole 15mg/day (0.25mg/kg/day).

- November 2017:** in view of no significant improvement in thyroid function and slight changes in hepatic enzymes, amiodarone was replaced by sotalol 160mg/day.

### Biochemical follow-up:

Parameter	27/02/2018	18/04/2018	02/05/2018
TSH (0.47-3.41 uUI/mL)	0.02	22.10	6.34
FT4 (0.89-1.37 ng/dL)	0.78	0.51	0.9
FT3 (2.25-3.85 pg/mL)	2.83	2.62	3.54

Suspension of thiamazole

Five months after starting thiamazole, the patient had gained 5kg and maintained good control of both heart rhythm and rate.

He remains asymptomatic after suspension of thiamazole.

## Discussion:

This is a rare case of AIT in pediatric age. If possible, amiodarone should be replaced by other antiarrhythmic drug, as was the case with this patient. Nevertheless, therapy with thiamazole has to be continued due to the long half-life of amiodarone. It is also important to distinguish the type of AIT when planning therapy, as steroid therapy could be started when findings indicate type II or mixed-type AIT.

## Bibliography:

- Bartalena L. et al. 2018 European Thyroid Association (ETA) Guidelines for the Management of Amiodarone-Associated Thyroid Dysfunction. 10.1159/000486957.
- Trudel K. et al. Pediatr Crit Care Med. 2011 Jan;12(1):e43-5. doi: 10.1097/PCC.0b013e3181e2a388.
- Hanley P. et al. Thyroid Disorders in Children and Adolescents. JAMA Pediatr. 2016;170(10):1008-1019. doi:10.1001/jamapediatrics.2016.0486

