

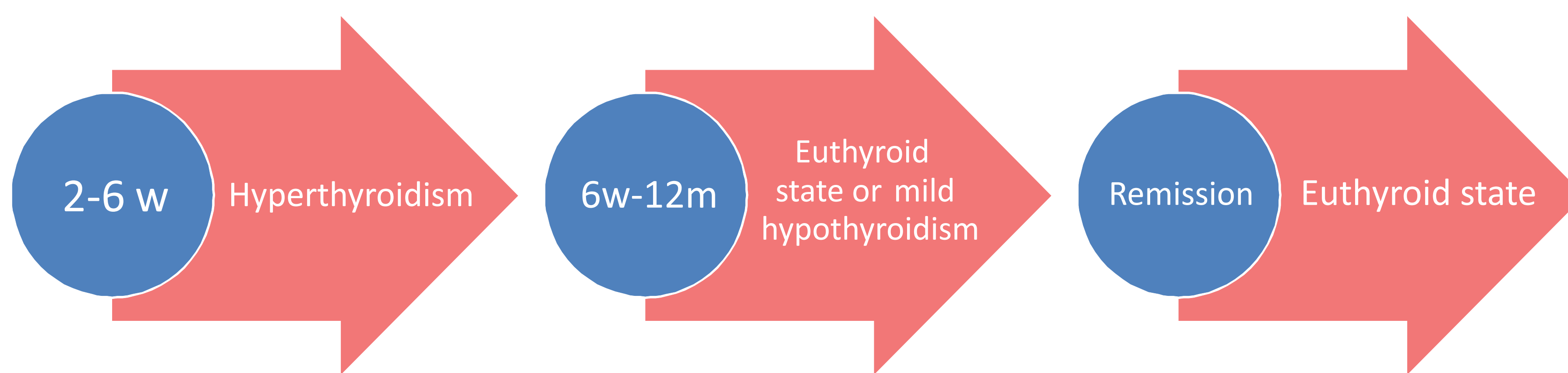
Rare case of thyroiditis De Quervain in a 6 year old girl

M. Liapi, E. Hamelmann, N. Jorch

Evangelisches Klinikum Bethel, pediatric endocrinology department, Bielefeld, Germany

Subacute thyroiditis or De Quervain thyroiditis:

- Self limited inflammatory disease of the thyroid gland
- Caused by viral infection in genetically predisposed individuals
- Uncommon in adults, very rare in children



	ESR	CRP
On admission	70mm	74,9 mg/l
2 nd week	25 mm	0,4 mg/l

Case report

6 year old girl with 10 days history of fever, sore throat, weightloss, neck and ear pain

Clinical mild lymphadenopathy, diffuse painful swelling in the right neck

High infection parameters, high fT4, low TSH

U/S: diffuse inhomogen enlargement of the right thyroid globe, without abscess formation

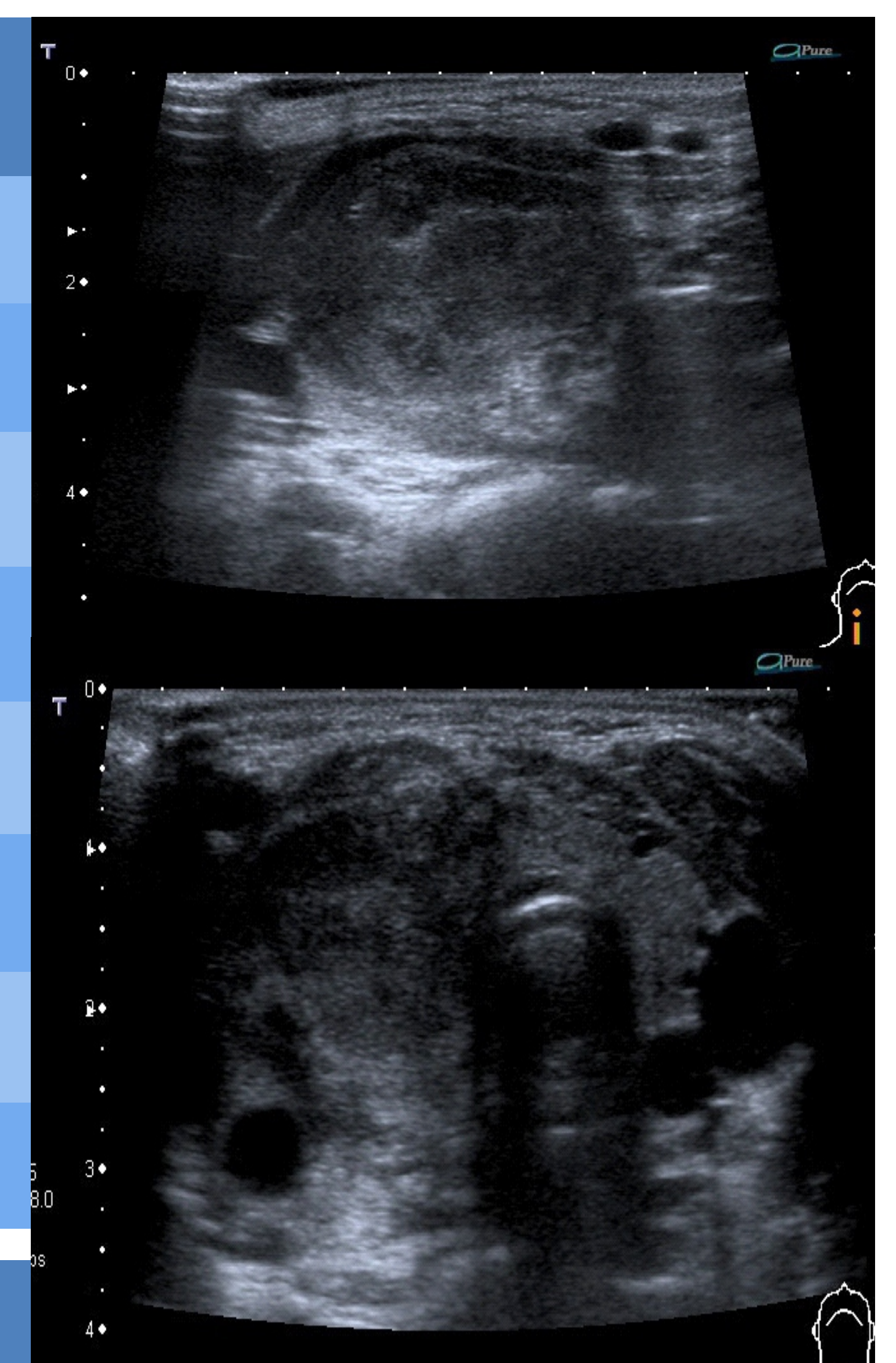
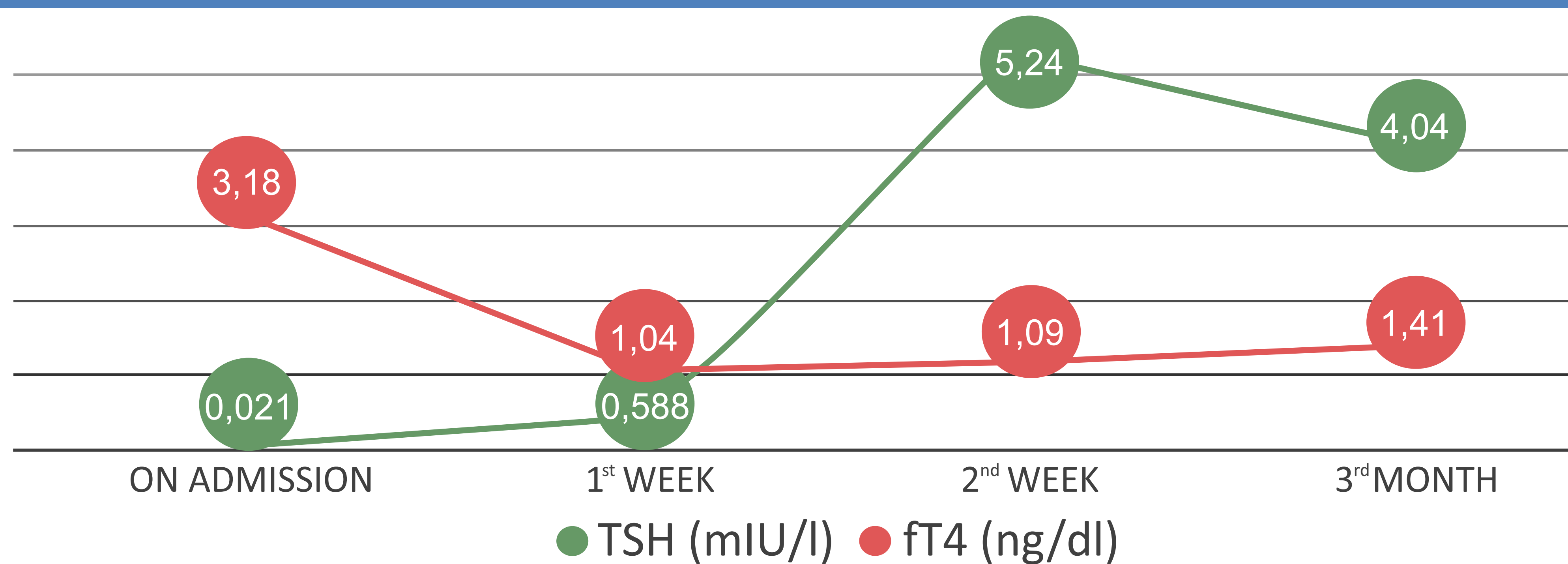
On NSAID for 5 weeks, rapid resolution of fever and symptoms. Euthyrosis in 2 weeks

Virologic studies negative

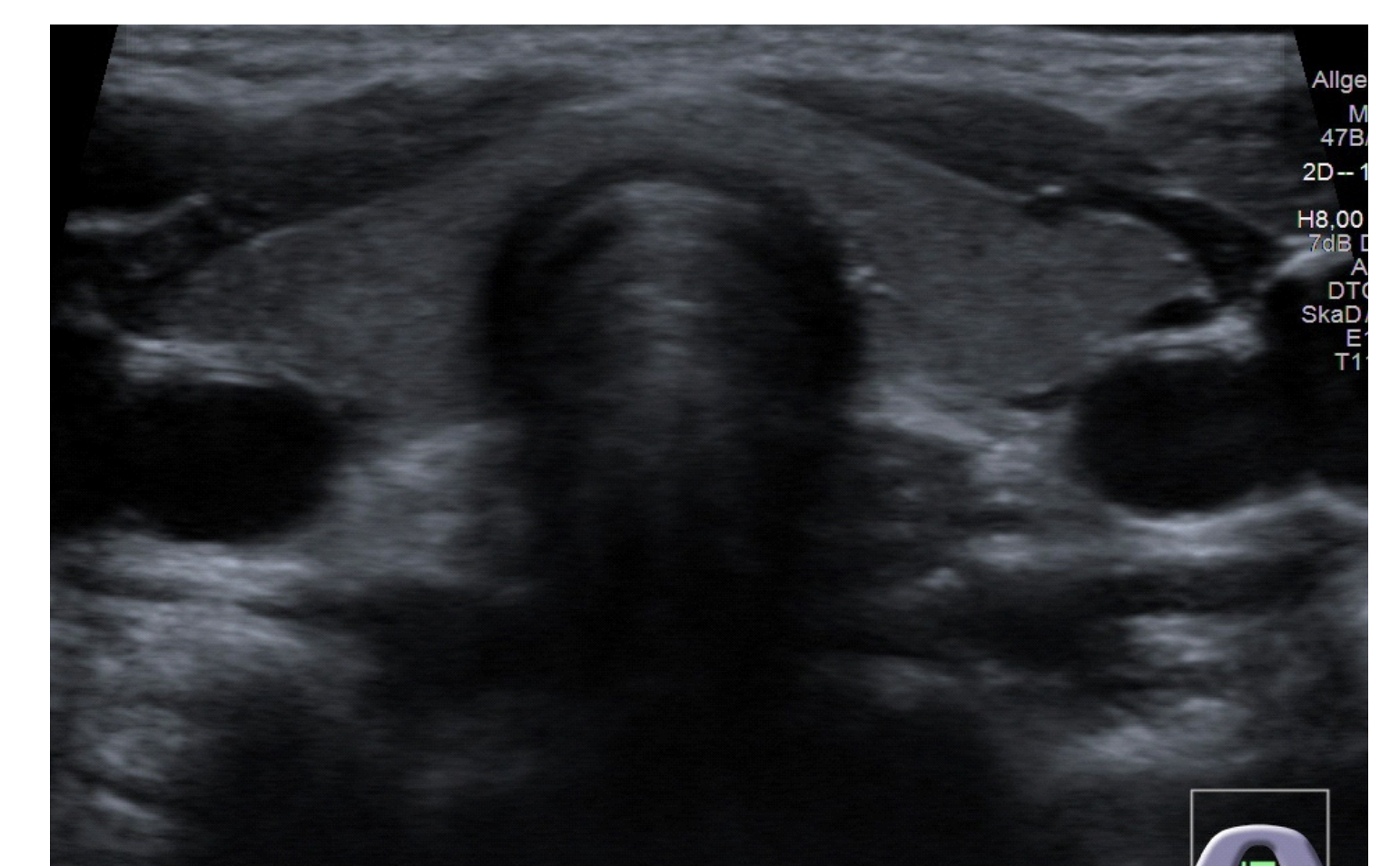
Recurrent fever intermittently for 4 months

The right globe of the thyroid gland returned to normal size in 8 weeks

Thyroid gland function tests



U/S on diagnosis



8th week

Conclusion

- Subacute thyroiditis is very uncommon in children but it may be underdiagnosed as symptoms resemble common viral illnesses
- Thyroid malignoma or acute suppurative thyroiditis must be ruled out
- Symptomatic treatment with NSAID (further optional treatment with steroids)
- Usually complete remission without complications