

# The Novel R211Q POP1 Homozygous Mutation Causes Severe Short Stature But Uniquely Only Subtle Skeletal Dysplasia

Maha Abdulhadi-Atwan<sup>1</sup>, Tehila Klopshtock<sup>2</sup>, Muna Sharaf<sup>3</sup>, Ariella Weinberg-Shokrun<sup>2</sup>, Ephrat Levy-Lahad<sup>2</sup>, David Zangen<sup>3</sup>

<sup>1</sup> Bethlehem Arab Society for Rehabilitation Hospital, Beit Jala, Palestine

<sup>2</sup> Share Zedek Medical Center, Jerusalem, Israel

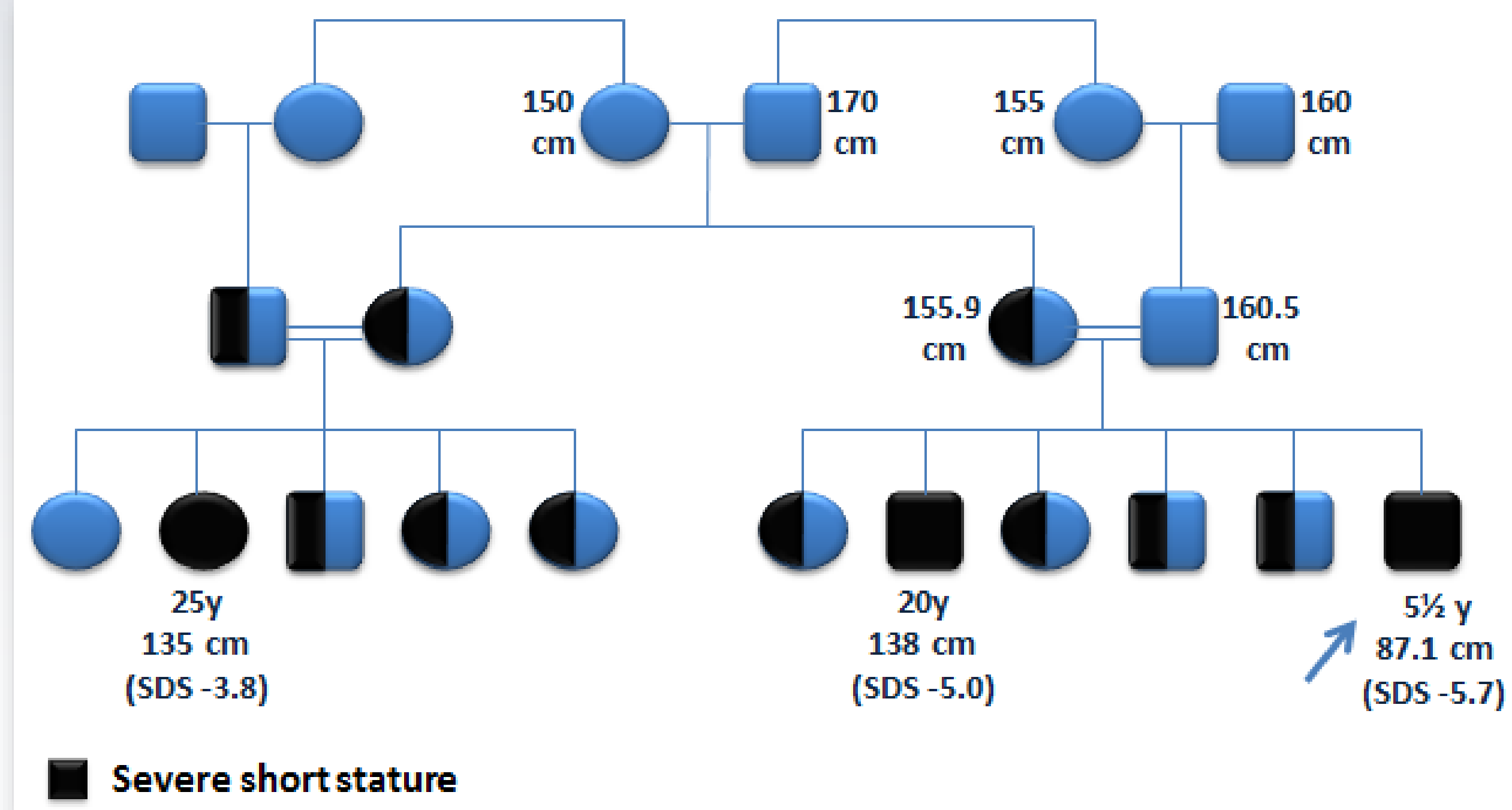
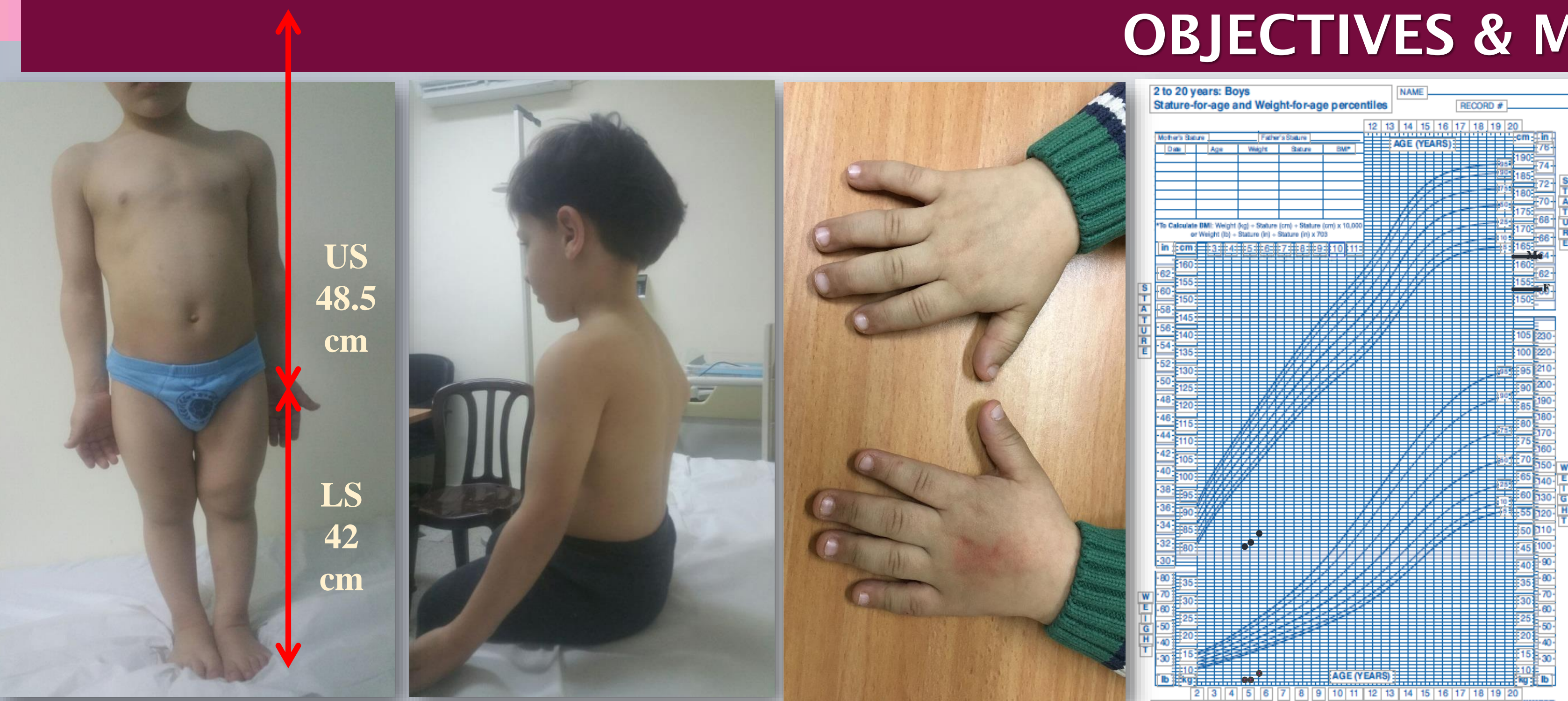<sup>3</sup> Division of Pediatric Endocrinology, Hadassah Hebrew University Medical Center, Jerusalem, Israel



## INTRODUCTION

Processing of Precursor 1 (POP1) is a core protein component of the Ribonuclease-Mitochondrial RNA Processing (RNase-MRP) enzymatic complex, an essential ribonucleoprotein in all eukaryotes. Mutations in *RMRP*, which encodes the RNA moiety of the complex, are known to cause several autosomal recessive skeletal dysplasias: cartilage-hair hypoplasia – anauxetic dysplasia (CHH-AD) spectrum disorders, characterized by severe disproportionate short stature. Recently, five mutations in *POP1* have been reported in five patients with anauxetic dysplasia (spondylo-epi-metaphyseal dysplasia with extremely short stature). Despite of the variability in phenotypic severity, involvement of the spine, epiphyses and metaphyses was evident in the five cases.

## OBJECTIVES & METHODS



A 6 year old boy ,born to consanguineous parents, presented with:

- Severe short stature (height 90.5 cm, SDS -5.68).
- Mild legs shortness (US:LS ratio is 1.15:1)
- Mild brachydactyly

- Family history: Adult male sibling and female cousin have extremely short final height (138 cm and 135 cm, respectively), with no apparent skeletal deformities.
- Normal growth investigations.

- Skeletal survey and whole exome sequencing were performed for the proband. Relative abundance of the RMRP RNA and unprocessed pre5.8s rRNA (a substrate of RNase MRP complex) were measured in the affected siblings, non-affected parents and control.

## RESULTS

### Skeletal Survey:

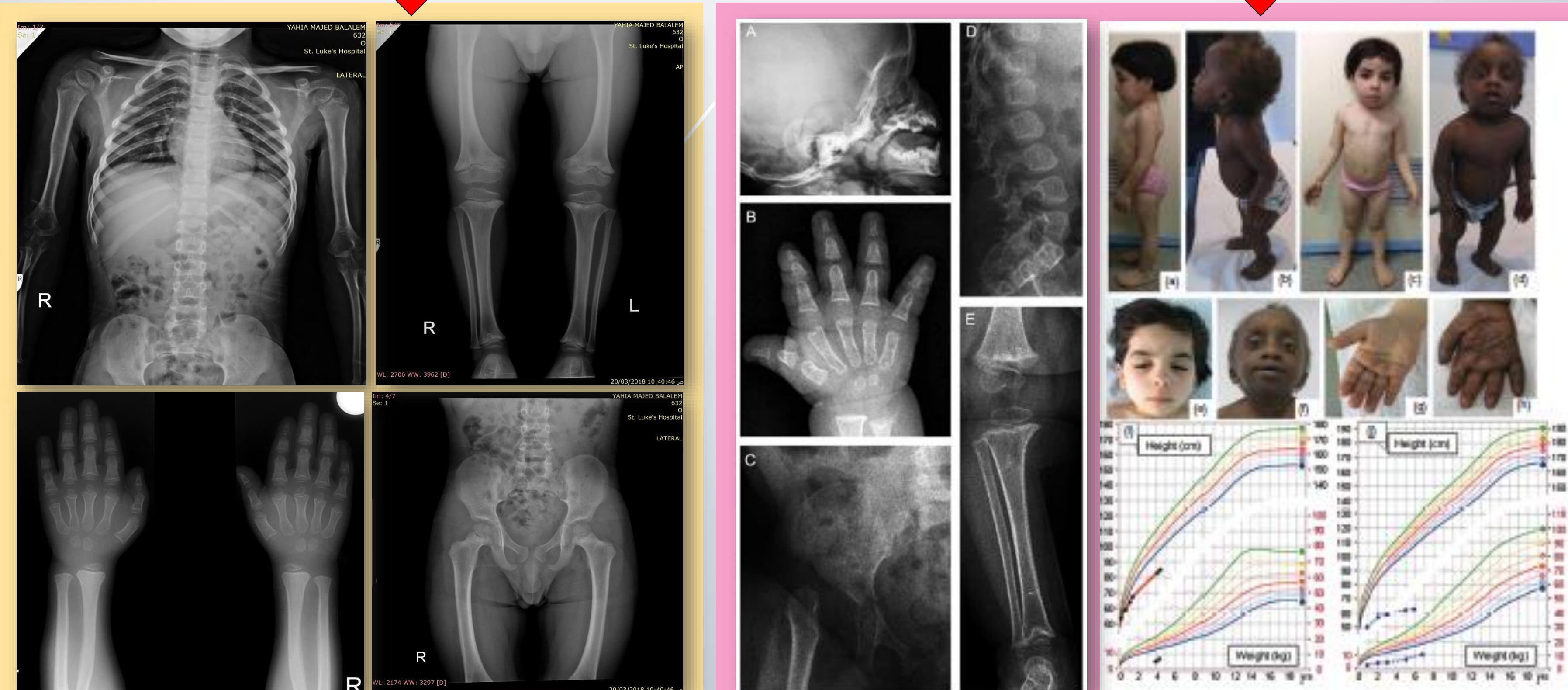- Short forearm & metacarpals.
- Irregularity of metaphyseal borders of long bones (subtle in our report)
- Bone age delay

### This report

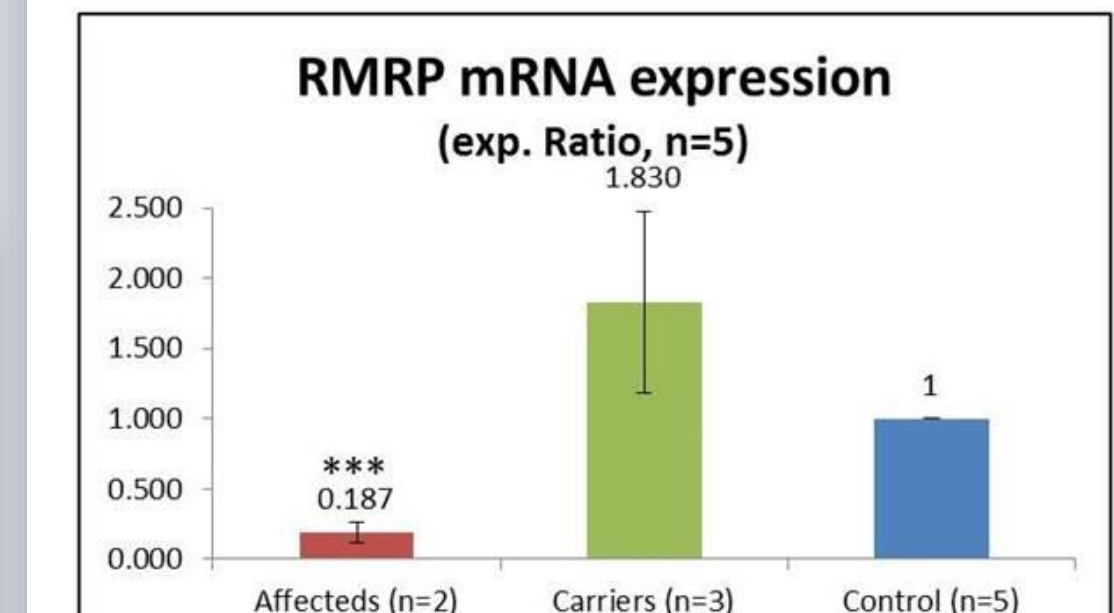
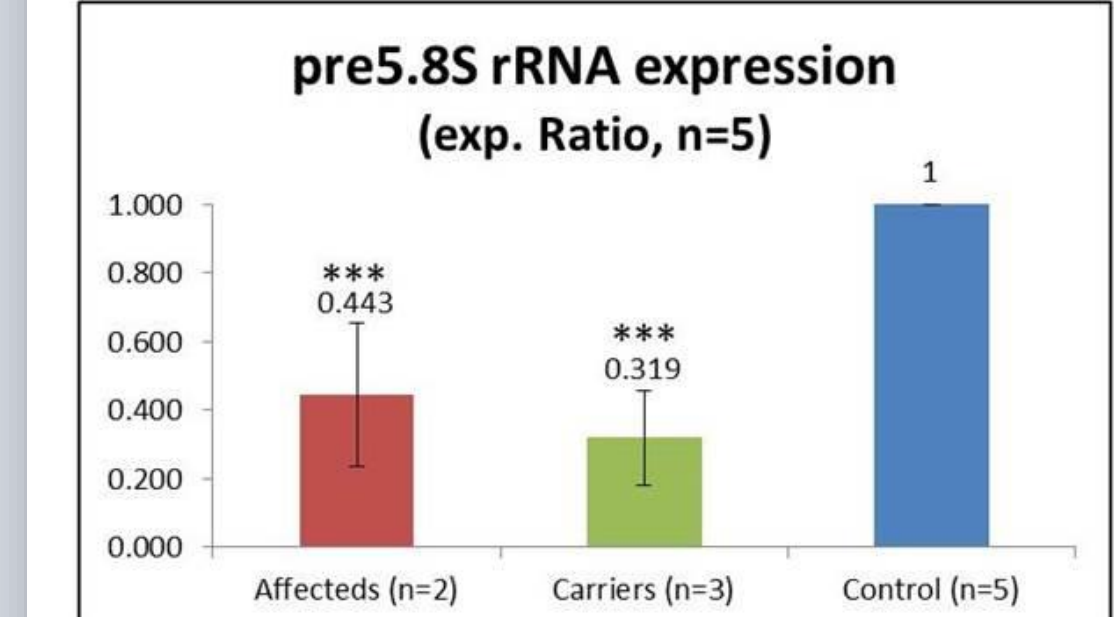
- ✗ No Epiphyseal involvement
- ✗ No Cranium, vertebral bodies or pelvis abnormalities

### Previous reports <sup>1, 2</sup>

- ✓ Epiphyseal involvement
- ✓ Cranium, vertebral bodies & pelvis



5 controls (5 different controls in 3 exp. – in each exp. there are 3 different controls)



### Expression Studies:

- The RNA moiety of the RNase-MRP complex was dramatically reduced (20 times less) in affected patients compared to non-affected controls.
- Pre5.8s rRNA was not increased in patients' RNA.

### Exome Sequencing:

- The proband, his affected brother and cousin were homozygous for the R211Q novel mutation in *POP1* gene.
- Parents and healthy siblings were all heterozygous.
- The arginine residue at position 211 is highly evolutionarily conserved.

## CONCLUSIONS

We describe a novel homozygous *POP1* mutation in three patients from a consanguineous family resulting in severe short stature. Unlike the previously reported five cases, skeletal dysplastic changes are subtle and merely metaphyseal. Gene expression assays showed no elevation in levels of pre5.8s rRNA possibly explaining the uniquely mild phenotype. We recommend to consider *POP1* mutations in familial cases with severe short stature even when skeletal dysplasia is not strongly evident.

## REFERENCES

1. Glazov et al. Whole-Exome Re-Sequencing in a Family Quartet Identifies *POP1* Mutations As the Cause of a Novel Skeletal Dysplasia. PLoS Genetics. 2011
2. Barraza-Garcia et al. Broadening the phenotypic spectrum of *POP1*-skeletal dysplasias: identification of *POP1* mutations in a mild and severe skeletal dysplasia. Clin Genet 2017

