

CAN NEUROIMAGING PREDICT ENDOCRINE MORBIDITY IN CONGENITAL HYPOTHALAMO-PITUITARY (H-P) DISORDERS?

M. Cerbone^{1,2}, M. Güemes^{1,2}, A. Wade³, N. Improda¹, M.T. Dattani^{1,2}

¹London Centre for Paediatric Endocrinology and Diabetes at Great Ormond Street Children's Hospital and University College London Hospitals; ²Section of Genetics and Epigenetics in Health and Disease, Genetics and Genomic Medicine Programme, University College London Great Ormond Street Hospital Institute of Child Health, London; ³ICH Pop, Policy & Practice Prog, UCL GOS Institute of Child Health

BACKGROUND

Brain MRI is an essential diagnostic tool when approaching the management of a patient with hypopituitarism. Although some H-P abnormalities on Magnetic Resonance Imaging (MRI) have been strongly associated with hypopituitarism, a correlation between specific H-P findings and the severity and timing at onset of different pituitary deficits is less clear. Additionally, due to the rarity of the condition, the distinctive H-P neuroimaging features of children with Septo-Optic Dysplasia (SOD) have only been reported in small case series.

AIM

The aim of this study was to evaluate the range of H-P structural abnormalities and the endocrine morbidity of children with SOD compared to those with isolated Multiple Pituitary Hormone Deficiencies (MPHD) (without optic nerve and midline brain abnormalities) and to those with isolated Optic Nerve Hypoplasia (ONH).

PATIENTS, DESIGN AND METHODS

PATIENTS

- 171 children with SOD
- 53 children with MPHD
- 35 children with ONH

SOD with pituitary defects were named SOD+
SOD without pituitary defects were named SOD-

DESIGN

- Retrospective longitudinal single centre study

METHODS

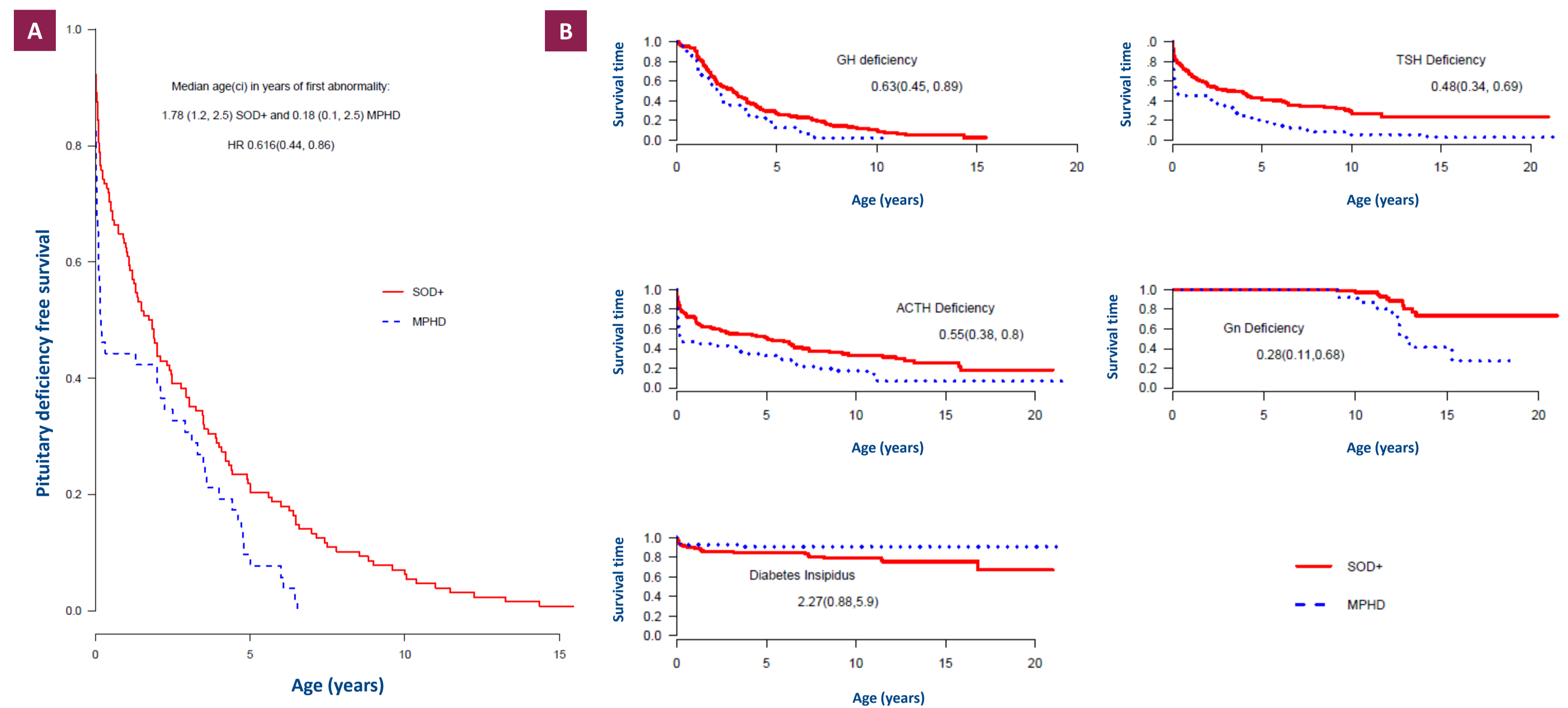
- The number of pituitary deficits was scored by the Endocrine Morbidity Score (EMS) ranging from 1 (one pituitary deficit) to 5 (panhypopituitarism)
- Magnetic resonance images were reviewed by one experienced neuroradiologist
- The following H-P abnormalities were reported:
 - absent/hypoplastic/enlarged Anterior Pituitary (AP)
 - absent/hypoplastic/enlarged/ectopic Posterior Pituitary (PP)
 - absent/hypoplastic/interrupted/thickened Pituitary Stalk (PS),
 - PS Interruption Syndrome (PSIS) [Small AP (SAP), Ectopic PP (EPP) and PS Absence (PSA)]

RESULTS

TABLE 1 GENERAL FEATURES	SOD (n:171)	MPHD (n:53)	ONH (n:35)	p value
Gender (M/F)	95/75	30/23	21/14	0.915
Age at diagnosis (years) mean ± SD (range)	2.45±2.89 (0.01-14.36)	1.78±2.15 (0.01-6.53)	2.82±2.55 (0.19-8.50)	0.004
Age at last appointment (years) mean ± SD (range)	9.24±4.64 (0.52-21.00)	9.00±4.66 (0.46-21.48)	9.54 ± 3.82 (1.03-15.01)	0.858
Follow-up duration (years) mean ± SD (range)	7.81±4.15 (0.40-17.50)	7.07±3.76 (0.45-16.70)	7.40 ± 4.04 (0.69-14.82)	0.494

FIGURE 1

Survival curves of time to first pituitary abnormality (A) and to each pituitary deficit (B) in SOD+ compared to MPHD patients (Hazard ratio 95% confidence interval)



SUMMARY OF MAIN FINDINGS

- Of SOD patients, 39/171 (23%) did not develop hypopituitarism over a median (25th,75th centiles) follow-up of 6.20 (3.41, 8.06) years, although 73% of them had a SAP (Table 2).
- Half of the patients with ONH had SAP (Table 2), but preserved pituitary function at 10.22 (5.96, 12.98) years of follow-up.
- Compared to SOD, MPHD patients developed the first deficit earlier (Figure 1A).
- MPHD patients were significantly more likely to manifest each individual anterior pituitary deficiencies and to develop these earlier (Figure 1B), with a higher prevalence of EPP and PSIS (Table 2).
- Diabetes Insipidus (DI) (Figure 1B) and PP Absence (PPA) (Table 2) were more frequent in SOD.
- The time to first deficiency was significantly associated with the number of pituitary deficits that subsequently developed [HR 1.59 (1.36, 1.85)] (Figure 2) and with the presence of EPP [Hazard ratio 2.11 (1.41, 3.15)] and PPA [Hazard ratio 2.54 (1.53, 4.21)], in both groups.
- In SOD only, there was an association between PSA and ACTH, GH and TSH deficiencies, as shown by the interaction Hazard ratio of 3.02 (1.16, 7.84), 2.7 (1.10, 6.61) and 3.04 (1.23, 7.56), respectively.
- Among DI patients, 6/26 (23%) SOD and 3/5 (60%) MPHD had a normal PP and 3/26 (11.5%) SOD and 1/5 (20.0%) MPHD had EPP. Among patients without DI, 18/128 (14.1%) SOD and 2/45 (4.4%) MPHD had PPA.
- Unusual MRI abnormalities (pituitary enlargement or pituitary stalk thickening) were documented in SOD only (Table 2).

FIGURE 2

Survival curves of time to first pituitary abnormality in patients with different EMS at last follow-up (Hazard ratio 95% confidence interval)

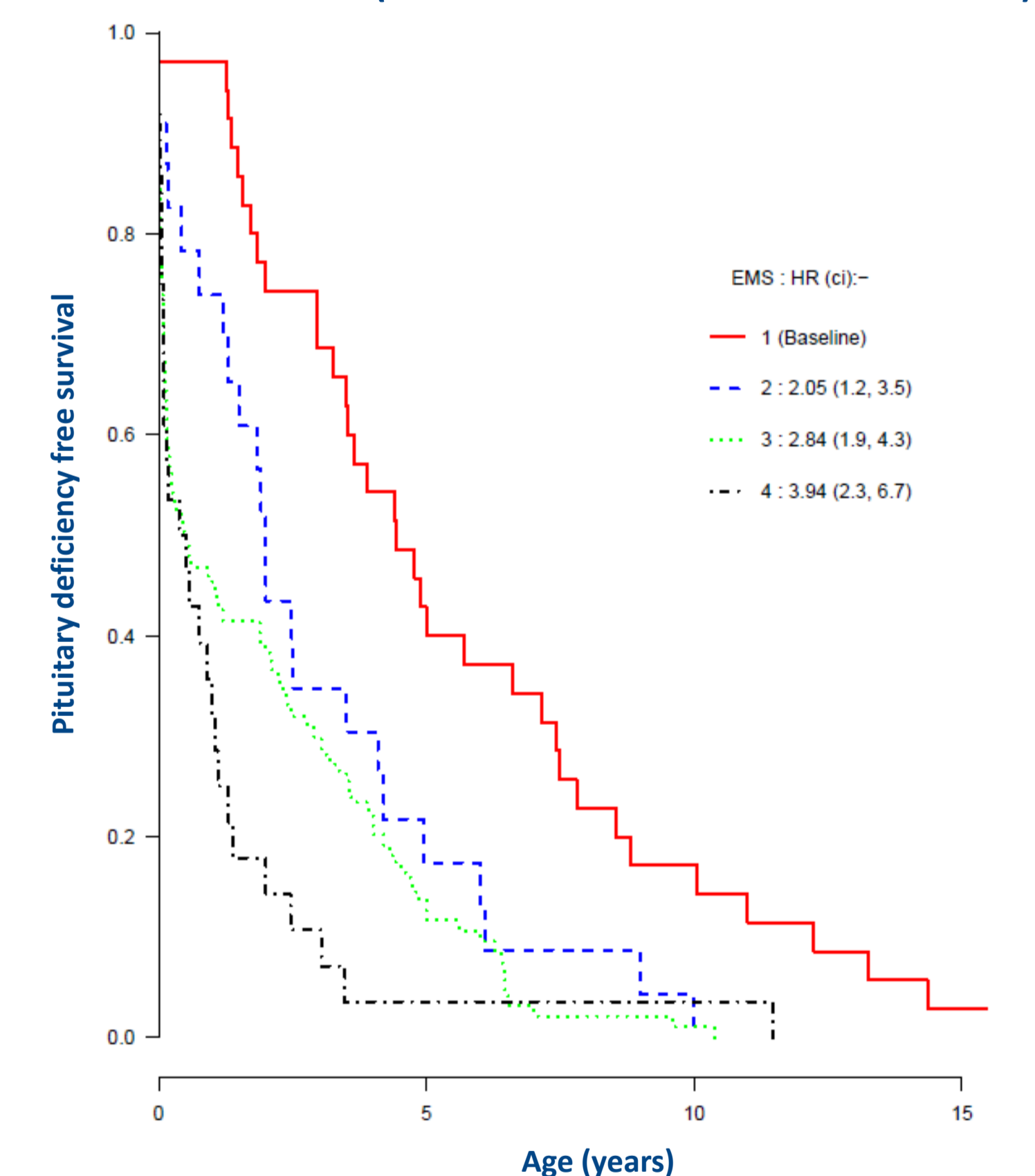


TABLE 2 STRUCTURAL H-P ABNORMALITIES	SOD (n:171)	MPHD [¶] (n:53)	ONH (35)	SOD+ [¶] (n:132)	SOD- (n:39)	p value [¶]
Anterior pituitary abnormalities n (%)	135/162 (83.3)	49/50 (98.0)	17/34 (50.0)	108/125 (86.4)	27/37 (73.0)	0.127
Absence	2/162 (1.2)	1/50 (2.0)	-	2/125 (1.6)	-	
Hypoplasia	132/162 (81.5)	48/50 (96.0)	17/34 (50.0)	105/125 (84.0)	27/37 (73.0)	
Enlargement	1/162 (0.6)	-	-	1/125 (0.8)	-	
Posterior pituitary abnormalities n (%)	96/161 (59.3)	43/50 (86.0)	0	84/125 (67.2)	12/37 (29.6)	<0.0001
Absence	34/162 (21.0)	3/50 (6.0)	-	27/125 (21.6)	7/37 (18.9)	
Hypoplasia	8/162 (4.9)	-	-	4/125 (3.2)	4/37 (10.8)	
Enlargement	1/162 (0.6)	-	-	1/125 (0.8)	-	
Ectopia	53/162 (32.7)	40/50 (80.0)	-	52/125 (41.6)	1/37 (2.7)	
Stalk abnormalities n (%)	78/157 (49.7)	23/49 (46.9)	0	67/122 (54.9)	11/35 (31.4)	0.629
Absence	32/157 (20.4)	11/49 (25.4)	-	30/122 (24.6)	2/35 (5.7)	
Thin	43/157 (27.4)	10/49 (10.4)	-	34/122 (27.9)	9/35 (25.7)	
Interrupted	2/157 (1.3)	2/49 (4.1)	-	2/122 (1.6)	-	
Thick	1/157 (0.6)	-	-	1/122 (0.8)	-	
Pituitary stalk interruption syndrome n (%)	37/159 (23.3)	23/49 (46.9)	0	36/122 (29.5)	1/37 (2.7)	0.030

CONCLUSIONS

- SOD patients present with a wide spectrum of radiological H-P abnormalities and with heterogeneous endocrine phenotypes, whilst MPHD tend to develop multiple anterior pituitary deficits at early stages of life with a higher prevalence of EPP and PSIS.
- PSA is associated with the development of specific anterior pituitary deficits in SOD only.
- SAP and PPA have low predictive value for the development of anterior and posterior pituitary deficits.
- MRI findings can predict the development of endocrine deficits only to some extent, hence life-long surveillance is essential in all groups.

Disclosure statement: the authors have nothing to declare