

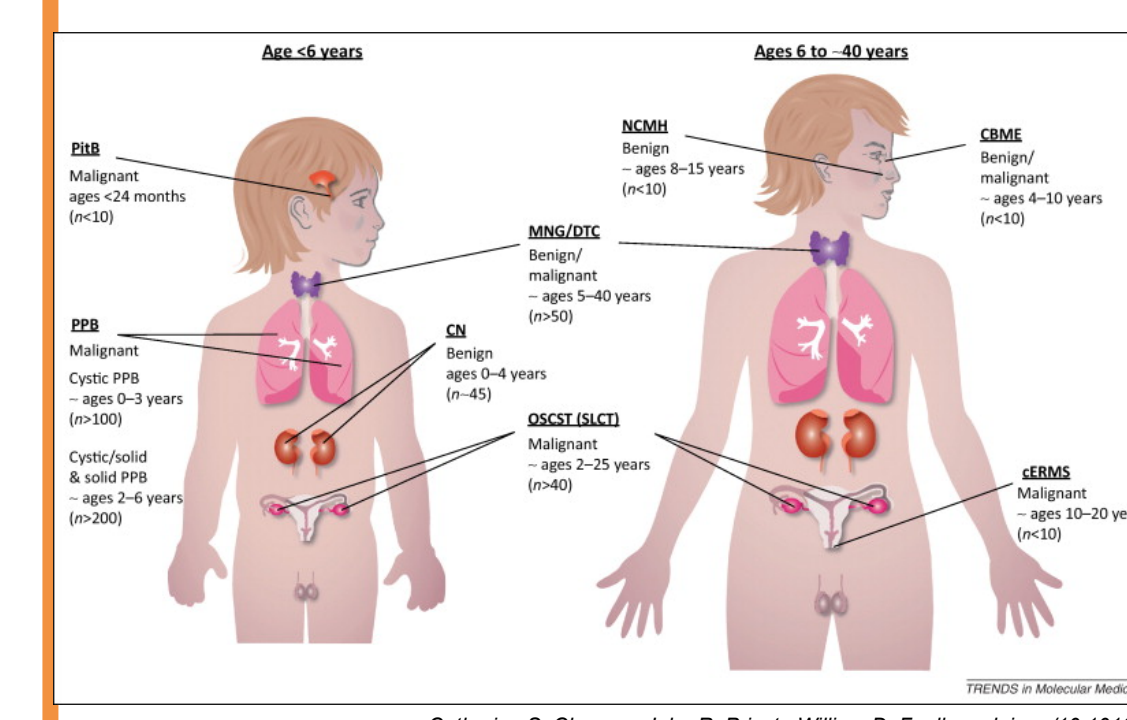
# Multinodular goiter in childhood: A diagnostic gateway for screening *DICER1* syndrome

 Isabelle OLIVER PETIT<sup>1</sup>, Solange GRUNENWALD<sup>2</sup>, Lisa Golmard<sup>5</sup>, Frédérique SAVAGNER<sup>3,4</sup>
<sup>1</sup> Endocrine Unit, Children Hospital, <sup>2</sup> Endocrine unit, Hôpital Larrey <sup>3</sup> Endocrine molecular biology, Institut Fédératif de biologie, University Hospital, TOULOUSE, <sup>4</sup> Université Paul Sabatier, Toulouse., <sup>5</sup> Institut Curie, Paris. France

Nothing to disclose

## Background

*DICER1* is a member of the Ribonuclease III family that plays a crucial role in the biogenesis and the maturation of microRNAs. Pathogenic germline *DICER1* variants cause a **hereditary cancer predisposition syndrome**, recently described, with a large variety of manifestations: in addition to first described pleuropulmonary blastoma (PPB) and ovarian sex cord-stromal tumours, individuals may also develop benign as multinodular goiter (**MNG**), cystic nephroma... or malignant rare ubiquitous tumours and differentiated thyroid carcinoma from infancy to adolescence and early adult. Average penetrance seems low to 15% except for MNG recently described as 15 to 75% at 40 years (male and female respectively).



## Objective

To investigate whether MNG could be a pointer for familial *DICER1* variants screening in pediatric population

## Methods

We report a families serie whose diagnosis for *DICER1* syndrome was **suspected on childhood MNG history: or in index patient or in siblings presenting benign (15) and/ or malignant (9) rare tumours.**

We screened germline DNA samples from probands (9) and relatives (16) for *DICER1* variants using Next Generation Sequencing (NGS) tools. Personal and family history, clinical examination, thyroid ultrasonography, thyroid function and autoimmunity were evaluated.

## Results

### Clinical presentation at diagnostic for index patients and medical history in siblings

Families	Age (year)	Clinical presentation in index patient	Personal medical history	Family medical history none or discovered after screening (age)	Nb patients with pathogenic variants
F 1	10	GMN	Neonatal lung malformation (PPB)	MNG in father, uncle, grandfather (15y) lung cysts in cousin (5y)	6
F 2	17	Pineoblastoma Renal cyst	MNG (12y) DTC (16y)	none	1
F 3	<1 (7 months)	Cystic nephroma	none	DTC in mother (6y) GMN in aunt (15y) Sertoli cell tumor in aunt (30y) Lung cyst in grandfather (1y) Thyroidectomy in grandfather (20y)	3 (4)
F 4	3	PPB (3y) Nephroblastoma (3y)	none	Recurrent MNG in brother (8 and 13 y) Thyroidectomy in father (20 y)	4
F 5	3	Metastatic PPB	none	Thyroidectomy in mother (20y) MNG in uncle (25y)	4
F 6	9	MNG	none	Recurrent MNG in mother (12y) MNG in sister (13y) Ovariectomy in grandmother (18 y)	3 (4)
F 7	13	MNG	none	MNG (GF)	3
F 8	13	MNG	none	MNG	1
F 9	11	MNG	none	MNG	1

-Index patients were 4 girls and 5 boys, between 7 months to 17 years.

Diagnostic was suspected :

- 4 with a rare paediatric tumor and family MNG history
- 5 with childhood onset MNG

Interestingly, for 3 families the unique manifestation over generations was related to MNG.

-We identified 8 different pathogenic *DICER1* variants in the 9 index patients and 16 relatives. In all cases but one, the germline *DICER1* pathogenic variants have been already described in the literature or located in the enzymatic site of the enzyme. In one family, infant history of pulmonary cystic adenomatoid malformation in the context of MNG at 11 for the proband but also father and uncle, led us to explore the *DICER1* gene and identified a novel heterozygous variant in the exon 20, c.3104C>G, p.Pro1035Arg. Histological sections rereading in view of the familial thyroid history corrected the initial diagnosis in PPB.

-Quick molecular confirmation by NGS for *DICER1* syndrome suspicion changed twice our therapeutic strategies

-Surveillance strategies has been organised for all patients with pathogenic following 2018 *DICER1* guidelines<sup>a</sup>

<sup>a</sup>Schultz KAP, Clin Cancer Res.2018;24(10) doi:10.1158/1078-0432

**Conclusion:** MNG is uncommon in children. Its diagnosis before adulthood, recurrence within a family or its association with children benign or malignant tumours should make them suspect of anomalies in the *DICER1* protein as proposed in recent international recommendations<sup>a</sup>.

Children and adolescents diagnosed with GMN should be referred in genetic counselling<sup>a</sup>.

Early detection of *DICER1* variants has important consequences in terms of tumour screening, therapeutic strategies and genetic counseling

