



A rare case of ACTH- independent Cushing's syndrome due to bilateral micronodular adrenal hyperplasia, and myoclonic dystonia

I.A. Vasilakis¹, P. Kazakou¹, C. Kogia¹, M. Karafidou¹, G. Chrousos¹, E. Charmandari¹

¹ Division of Endocrinology, Diabetes and Metabolism, First Department of Pediatrics, National and Kapodistrian University of Athens Medical School, "Aghia Sophia" Children's Hospital, Athens, Greece

Background

ACTH- independent adrenal Cushing's syndrome accounts for less than 15% of endogenous Cushing's syndrome in children¹. We present a rare case of ACTH-independent adrenal Cushing's syndrome, which was associated with myoclonic dystonia.

Case presentation

A 12-year old girl (Figure 1) was referred on account of rapid weight gain, fatigue, growth deceleration and facial hypertrichosis. She had a history of gait instability and ataxia till the age of 5 years and had primary nocturnal enuresis. Her mother had administered a Chinese herb (rehmania root) for 2 months prior to her presentation. Clinical examination revealed buffalo hump, moon facies, central obesity, dysmetria and ataxia. Her height was 128.4 cm (<3rd centile), her weight was 32.3 kg (3rd – 10th centile) (Figure 2) and her BMI was 19.6 kg/m² (25th- 50th centile). Her Tanner pubertal stages were B1, P3, AH1.

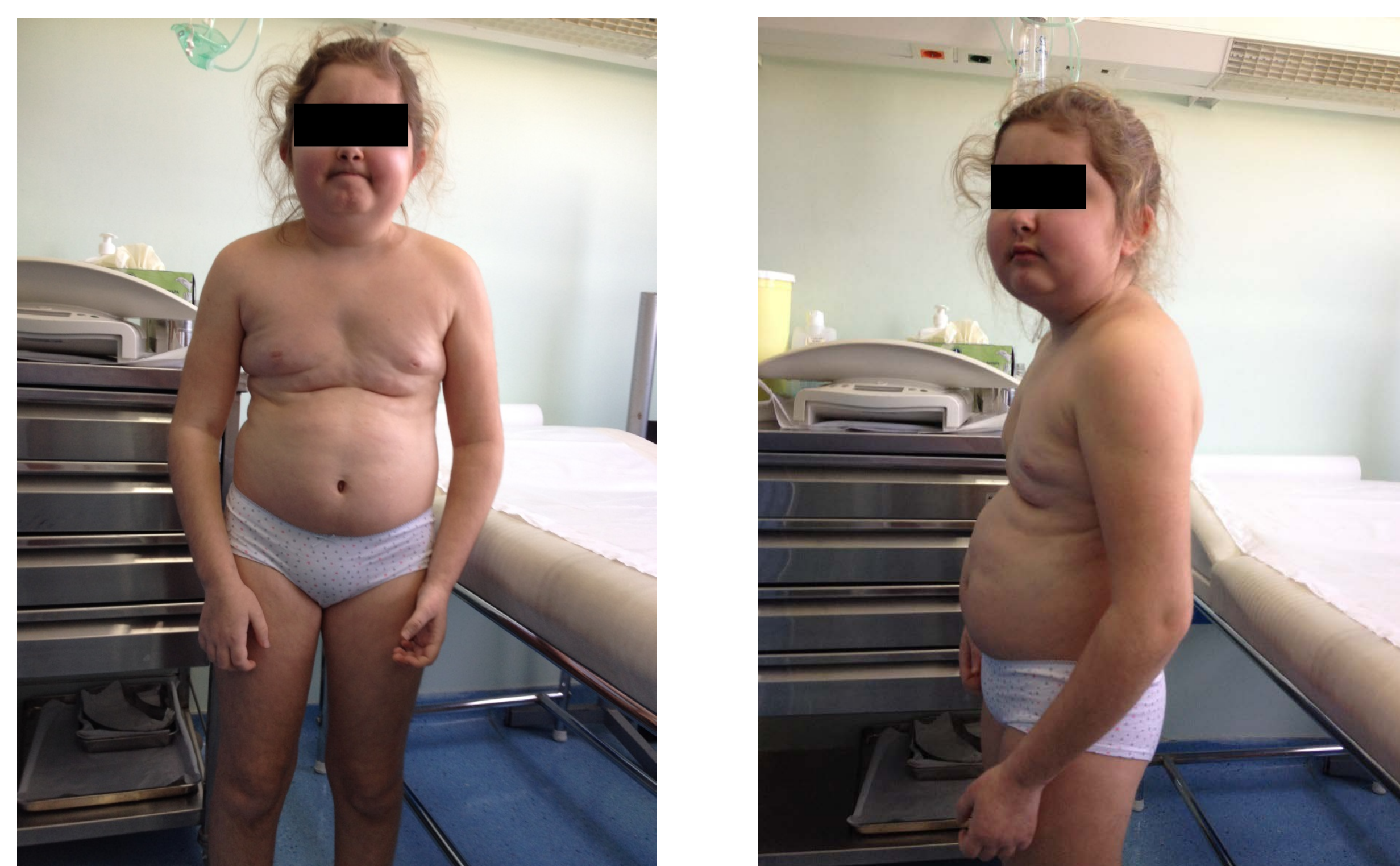

Figure 1: The patient at her first presentation

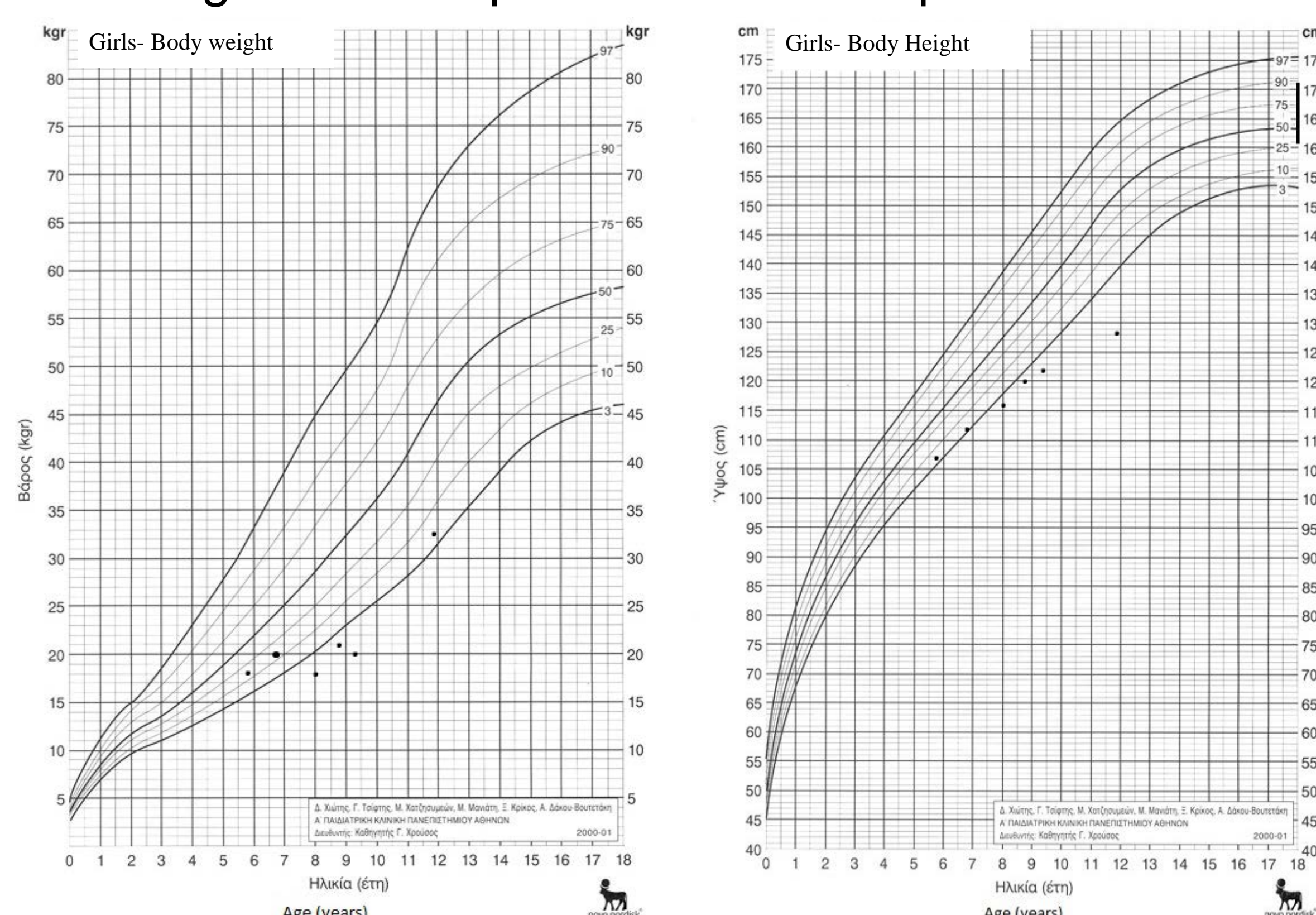


Figure 2: Patient's growth chart

Laboratory findings

Endocrinologic evaluation revealed elevated 24-hour urine free cortisol excretion [(1699.9 and 1079.7 (normal values: 2.6 – 37 µg/day)] and suppressed plasma ACTH concentrations (< 1 ng/mL) on several measurements. ACTH concentrations remained suppressed throughout a formal CRH Test. A Liddle test showed no suppression of serum cortisol concentrations following stimulation with low dose (22.47 mcg/dL) and high dose (27.95 mcg/dL) dexamethasone. The rest of the endocrinologic investigations were as follows:

TSH 0.89 µIU/mL (0.76-4.2), **FT4 0.7 ng/dL (0.9-1.7)**, DHEAS 0.89 mcg/mL (0.35-4.3), LH < 0.1 mIU /mL, FSH <0.1 mIU/mL, E2 <5 pg/mL, IGF-1 210 ng/mL (49-342 Tanner stage I), testosterone 52.8 ng/dL, **androstendione 500 ng/dL (17-175)**, DHEA 143 ng/dL (0-599). Adrenals CT- scan (Figure 3)

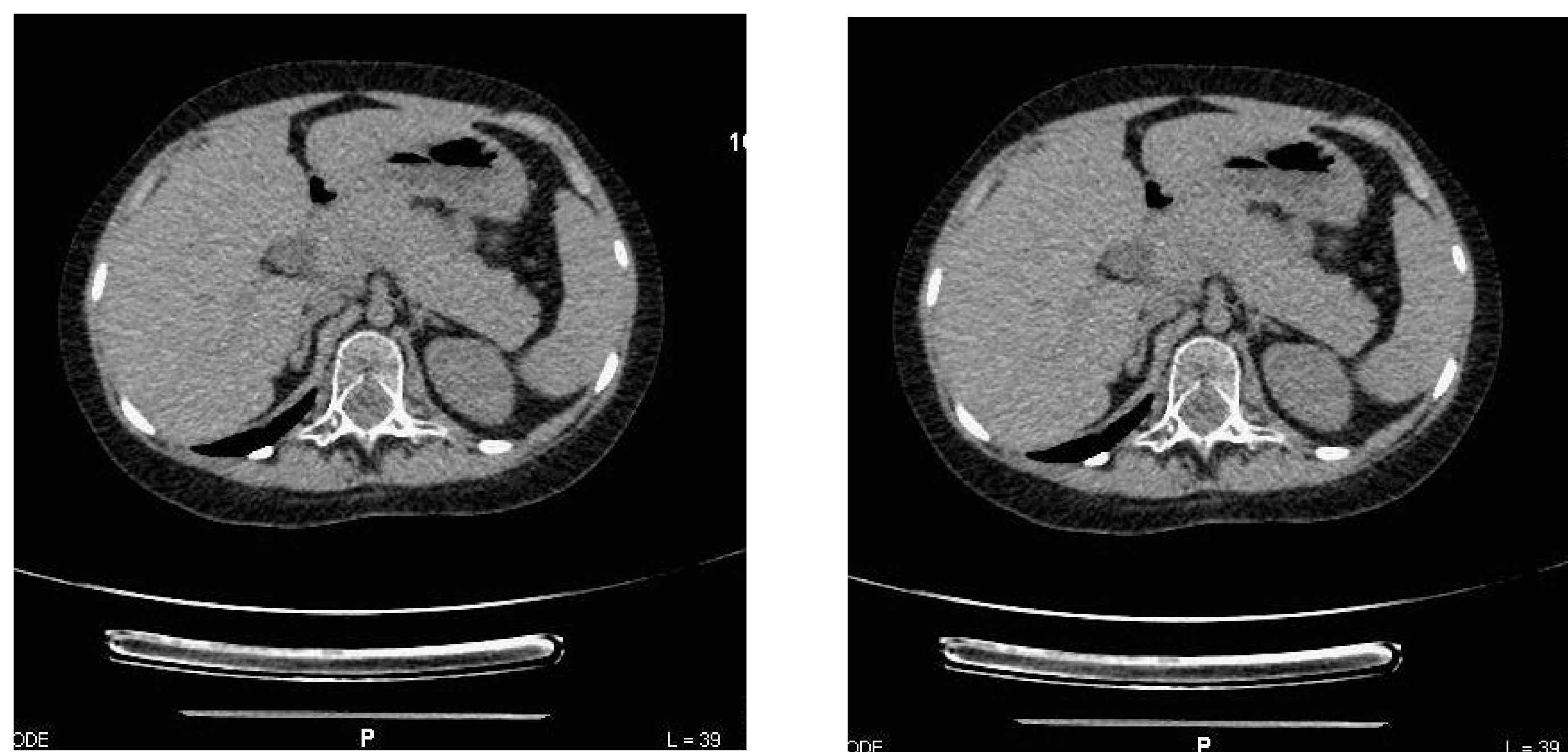


Figure 3: The computed tomography scan of the adrenals showed increased adrenal volume bilaterally.

The diagnosis of ACTH – independent Cushing's syndrome was made and the patient underwent bilateral adrenalectomy. The histopathologic examination confirmed isolated micronodular adrenocortical disease. The patient has been on replacement therapy with hydrocortisone and fludrocortisone since. Neurological evaluation confirmed the diagnosis of myoclonic dystonia due to deletion of the *SGCE* gene².

Conclusion

Exogenous Cushing's syndrome is the commonest etiology of Cushing's syndrome in the pediatric population, and Chinese herbs contaminated with glucocorticoids have been attributed as an etiologic factor.^{3,4} Isolated micronodular adrenocortical disease is an extremely rare aetiology of ACTH-independent Cushing's syndrome and bilateral adrenalectomy remains the best therapeutic option. Our case represents the first case of isolated micronodular adrenocortical disease associated with myoclonic dystonia.

References

- 1.Lodish M. and Stratakis C. "A genetic and molecular update on adrenocortical causes of Cushing syndrome." Nature Reviews. Endocrinology, 2016
- 2.Peall K, Kurian M et al. "SGCE and myoclonus dystonia: motor characteristics, diagnostic criteria and clinical predictors of genotype." J Neurol, 2014
- 3.Thrower SL, Taylor NF, Buckley DA. "Cushing syndrome and rebound generalised pustular psoriasis due to Chinese herbs." Br J Dermatol, 2013
- 4.Oldenburg-Lightenberg PC, van der Westerlaken MM, "A woman with Cushing's syndrome after use of an Indonesian herb: a case report." Neth J Med, 2007

